

Post-Dilatation endoscopic application of Mitomycin-C in children with esophageal strictures.

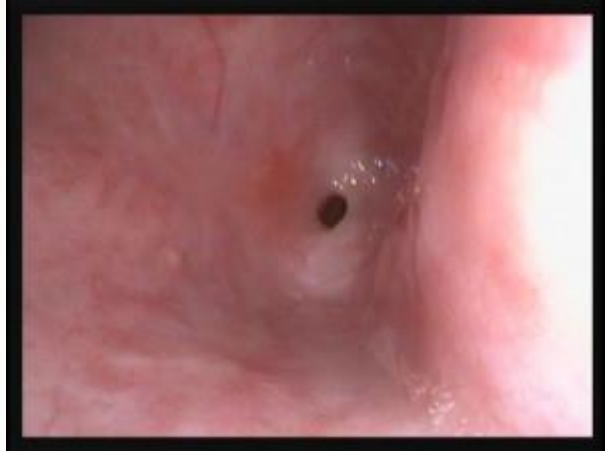By

Yasser Kamal Rashed

**A. Professor of Pediatric Hepatology,
Gastroenterology and GI endoscopy**

National Liver Institute - Menofiya University- Egypt.

**Consultant of Pediatric Gastroenterology and
Hepatology - Dubai Hospital.**




INTRODUCTION



There are numerous etiologies for esophageal stricture in childhood, most of which are benign.

- **Caustic burns of esophagus following ingestion of acids or alkali. (Most common)**
- **Complication of gastroesophageal reflux.**
- **Iatrogenic after surgical repair of esophageal atresia.**
- **Congenital esophageal atresia**

- 
- **Caustic esophageal strictures represent a significant social and medical problem especially in the developing countries.**
 - **These strictures have a negative impact on the children's quality of life mainly because of the dysphagia affecting their nutritional status in addition to the higher incidence of aspiration and recurrent chest infection.**

Stages of the caustic injury

ACUTE:

- ***Over the 1st week***
- **Following the initial necrosis (whether caused by alkali or acid),**
- **Inflammation and vascular thrombosis will take place**



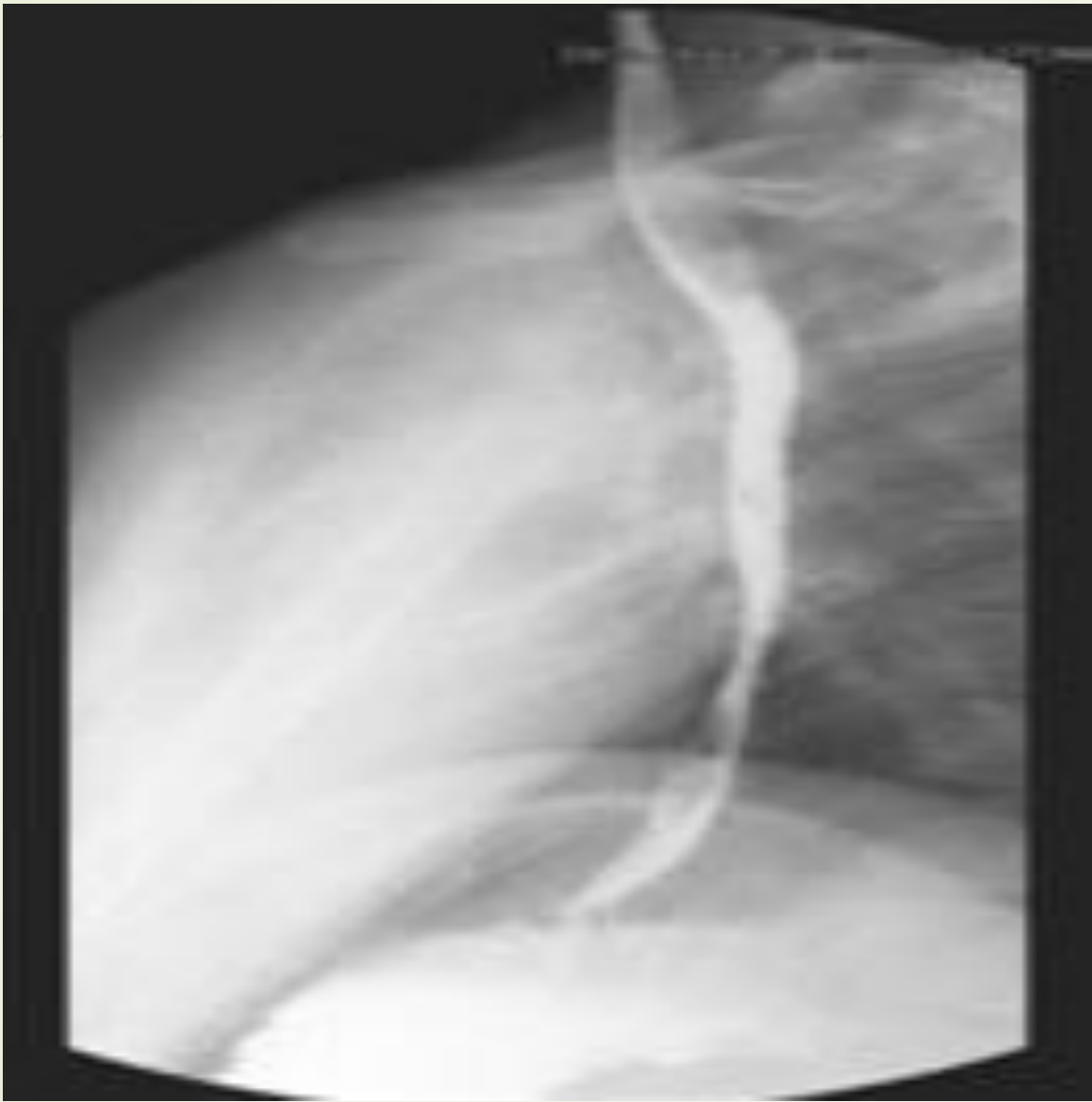SUBACUTE:

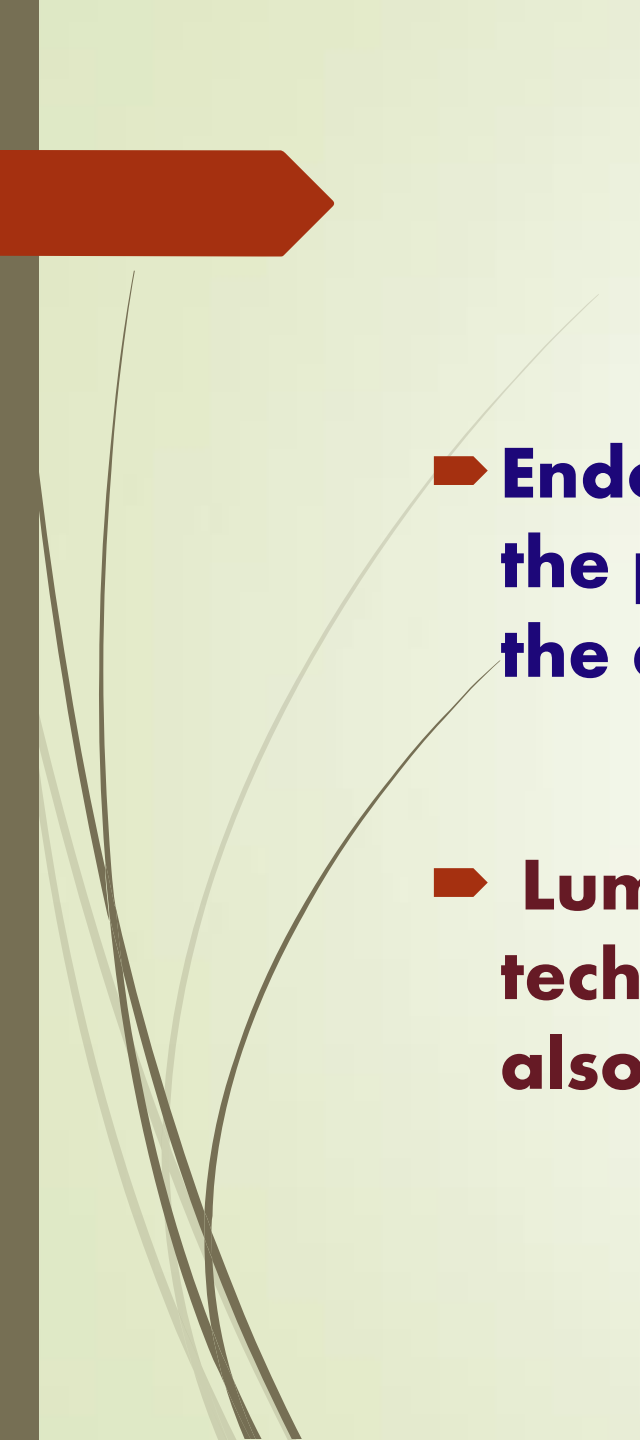
- ***By 10 days*** formation of granulation tissue and weakening of the esophageal wall
- **Esophagus is vulnerable to perforation not a good time for EGD)**

CHRONIC:

- ***By 3 -4 weeks***
- **Fibrogenesis and stricture formation.**

- 
- **These esophageal injuries eventually lead to stricture formation in approximately 6 weeks.**
 - **These strictures require repeated esophageal dilatations, or in severe cases, esophageal replacement.**
- 



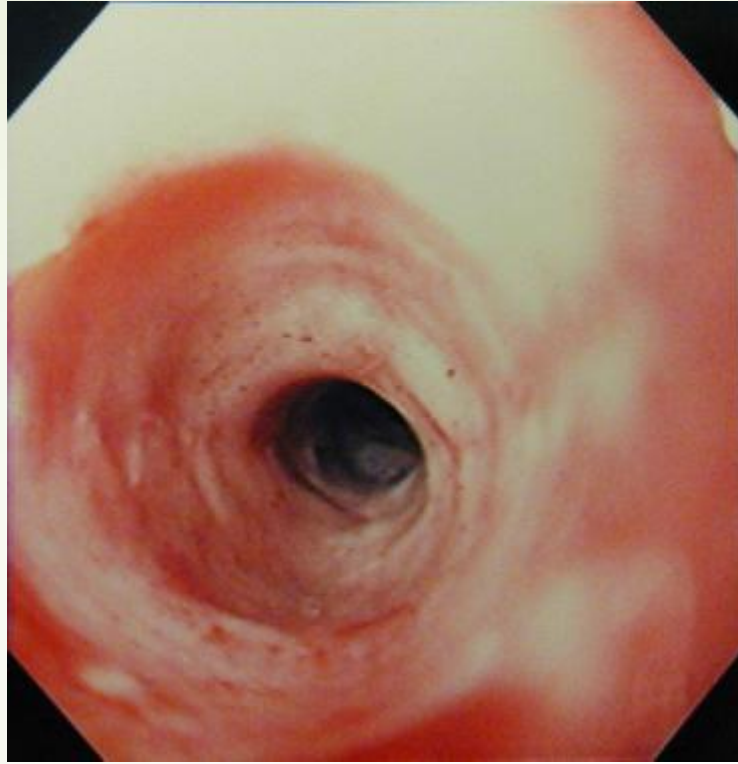
- 
- **Endoscopic GI bougienage and balloon dilation are the primary methods for non-surgical management of the enteric strictures.**
 - **Luminal application of a stent is another endoscopic technique used for the treatment of strictures and is also a means to maintain luminal patency.**

Mitomycin C (MMC),


Topical mitomycin-C has gained wide acceptance in the field of ophthalmology and otorhinolaryngology as an agent to reduce scarring and restenosis after surgery.

Favorable clinical responses to the topical application of mitomycin-C in reducing scar formation have recently been reported in the treatment of surgical wound healing and adhesions.

Topical post-dilatation application of an anti-fibrotic agent, mitomycin-C, in the treatment of an esophageal stricture has been described.





AIM OF THE STUDY


- 
- ➔ **The aim of this study was to evaluate the methodology, efficacy, and side effects of Mitomycin-C application after GI endoscopic dilatation of esophageal strictures in children.**




PATIENTS AND METHODS:

- 
- **This study included 30 children features of esophageal stricture seen in (17 boys and 13 girls, their ages ranged from 16–168 months with a mean of 57.6 months)**
 - **Full history taking**
 - **Thorough clinical examination was done with special interest on weight, height, and nutritional status**
 - **Laboratory investigations included full blood count (FBC), liver function tests, chest X ray. Barium study and upper GI endoscopy were undergone aiming to diagnose the nature and extent of esophageal stricture.**


- 
- A decorative graphic on the left side of the slide, featuring a dark red arrow pointing right at the top, and several thin, curved lines in shades of grey and brown extending downwards from the arrow's tail.
- **The procedure was done under general anesthesia.**
 - **Upper GI endoscopy was done first until reaching the area of stenosis,**
 - **Then gauge wire was passed into the stomach and esophageal dilators bogies were introduced subsequently under X-ray screen.**
 - **After dilatation to size allow introduction of endoscope.**
 - **The endoscope was reintroduced for topical application of mitomycin C (2 mg dissolved in 20 ml saline) on the stenotic area under direct vision.**

- 
- **This was done by either front-loading the pledget in a standard cap used for band ligation of varices attached to the end of the endoscope, to prevent the mitomycin-C from touching normal mucosa (group 1, n=16 patients), or by topical spraying of mitomycin using the injection needle on the affected mucosa (group 2, n=14 patients).**



The response to Mitomycin C application classified according to the clinical and endoscopic findings, clinical and endoscopic follow up continued for 3-5 years the response classified according to the followings:

- **Excellent:** excellent improvement regarding both clinical and endoscopic findings.
- **Partly improved:** improvement of both finding not allowing normal swallowing and weight gaining.
- **Poor response:** no improvement including the endoscopic and clinical findings.

- 
- **Caustic potash ingestion was the cause of esophageal stricture formation in 23 patients which determined by careful history taking and / or observing the containing bottle by the family.**
 - **Post reflux occurred in one patient**
 - **post-sclerotherapy in another patient.**
 - **The etiology was not discovered in 5 of the patients**



Upper endoscopy was performed in all of the patients and while barium upper gastrointestinal series was performed in 10 patients before endoscopy.

The median diameter of the stricture was 1.5mm (range 1–5 mm) which determined by barium or by upper GI endoscope.



The length of the stricture at diagnosis was ranged from 10 – 110mm.with the mean of 37.14mm.





Before Mitomycin C application, repeated dilation procedures were done in 21 patients ranging from 2 – 75 with the mean of 12 times.

Nine patients had no history of previous dilatation while number of dilatation settings with Mitomycin applications ranged from one to five with the mean of 2.3 times

- 
- 
- ▶ **The interval between each two dilation procedures settings before the application of mitomycin was 2.52 ± 1.44 weeks, only prolonged after the application of mitomycin to be 5.00 ± 4.39 weeks.**

- 
- 
- **Excellent improvement regarding both clinical and endoscopic findings seen in 28 patients (93.3%)**
 - **Partly improving seen in two (6.7%),**
 - **We did not find any patient with poor response in this study.**
 - **There were no complications related to the Mitomycin C application in both studied group.**

- 
- 
- **Follow up of our patients for 3-5 years did not show any complications related to the procedures itself or to Mitomycin C.,**
 - **The results of both pledget and spray methods nearly the same without any difference regarding the side effects which encourage the use of spray method as it easier for the endoscopist and shorter in duration.**


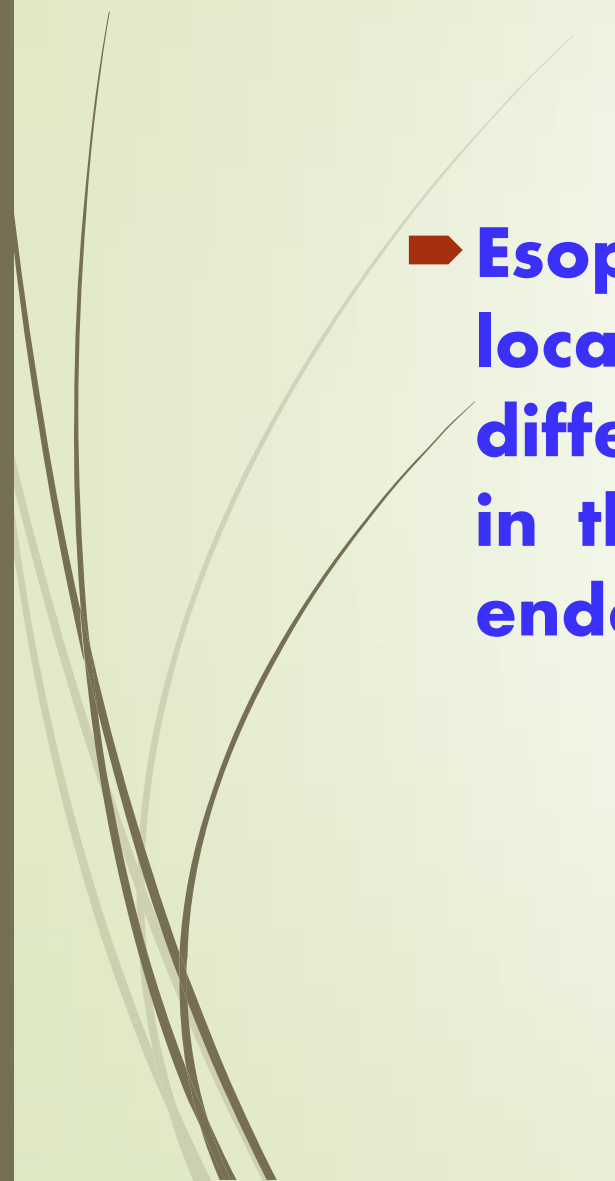
Case No	Age / mo	Gender	Length of stricture	Cause of stricture	R history	Tool of diagnosis	Diameter of stricture mm	No. of dilatation before MC	interval	No of Dilatation with MC	Interval () MC application	Response to mitomycin	Route of application	Complications of Mitomycin
1	60	F	110 mm	Post corr	D with boggies	Barium and upper endoscopy	1mm	75	2-3 wk	4	4w	Good	spray	No
2	56	M	70 -75	Post corr tic			1mm	45	2-3 wk	2	4w	Excellent	spray	No
3	36	M	13-15	Post corr			1mm	9	2-4 w	2	4w	Excellent	spray	No
4	42	M	15 -20	Post corr tic			2mm	7	2-4 w	2	4w	Excellent	spray	No
5	72	F	20 – 25	reflux			5mm	0	0	1	---	Excellent	spray	No
6	50	F	35-40	Post corr			3mm	11	4 w	1	--	Excellent	pledget	No
7	35	F	15 / 20	Post corr			1mm	22	2-4 w	3	3-4 w	Excellent	pledget	No
8	75	M	40-45	Post corr			2mm	18	4-6 w	2	4 w	Excellent	pledget	No
9	41	M	25-30	Post corr			1mm	12	4 w	2	4 w	Excellent	pledget	No
10	70	F	45-50	Post corr			4mm	8	4 w	2	4 w	Excellent	pledget	No
11	35	M	10 mm	Unknown		endo	5mm	0	0	1	0	Excellent	pledget	No
12	40	M	30 mm	Post corr		endo	3mm	4	2-4 weeks	2	8 w	Excellent	pledget	No
13	144	F	30	Post variceal injections and banding		endo	2mm	2	2 w	1		Excellent	pledget	No
14	60	M	50	Post corr		endo	3mm	4	2-4 weeks	3	8-12 w	Excellent	pledget	No
15	22 m	F	30	Post corr		endo	1mm	10	2-4 weeks	3	8-12 w	Excellent	pledget	No
16	16 m	M	20	Unknown		endo	4mm	none		2		Excellent	pledget	No
17	23 m	F	20	Post corr		endo	2mm	5	2-4 weeks	3	8-12 w	Excellent	pledget	No
18	72	F	40	Post corr		endo	1mm	12	2-4 weeks	4	8-12 w	Excellent	pledget	No
19	66 m	F	20	Unknown		endo	4mm	none		1		Excellent	pledget	No
20	168	M	70	Post corr		endo	1mm	16	2-4 weeks	5	8-12 w	Good	pledget	No
21	28 m	M	30	Post corr		Endo	1mm	6	2-4 weeks	3	8-12 w	Excellent	Pledget	No
22	30	M	24	Post corr		Endo	5mm	0	0	2	5w	Excellent	Spray	--
23	40	M	15	Post corr		Endo	5mm	0	0	2	4w	Excellent	Spray	No
24	42	F	10	Unknown		Endo	5mm	0	0	1	--	Excellent	Spray	--
25	54	F	10	Unknown		Endo	5mm	0	0	1	--	Excellent	Spary	--
26	39	M	15	Post corr		Endo	2mm	0	0	2	5w	Excellent	spray	No
27	44	M	10	Post corr		Endo	2mm	5	2-4	2	4w	Excellent	spray	No
28	40	F	10	Post Corr		Endo	5mm	5	2-4	2	4w	Excellent	spray	No
29	50	M	15	Post Corr		Endo	5mm	3	2-4	2	4w	Excellent	spray	No
30	56	M	10	Post corr		Endo	10mm	3	2-4	2	4w	Excellent	spray	No

Mo= months M+ Male F= female mm= millimeter post corr. = post corrosive
Endo = upper GI endoscopy MC = mitomycin C w = week

Table (1) Description of the cases



CONCLUSION:

- 
- 
- ➔ **Esophageal dilatation with mitomycin - C applied locally is a useful strategy in esophageal strictures of different etiologies without complications especially in those patients who were refractory to repeated endoscopic dilation.**



THANK YOU