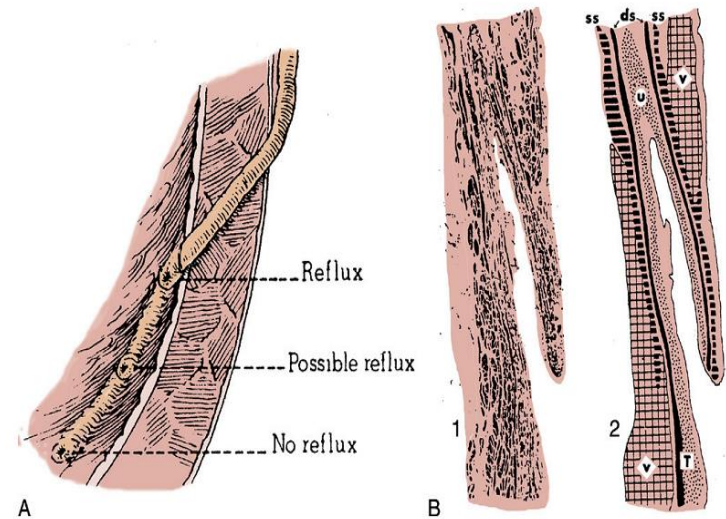


# Indications and effectiveness of the open surgery in vesicoureteral reflux

Suzi DEMIRBAG, MD

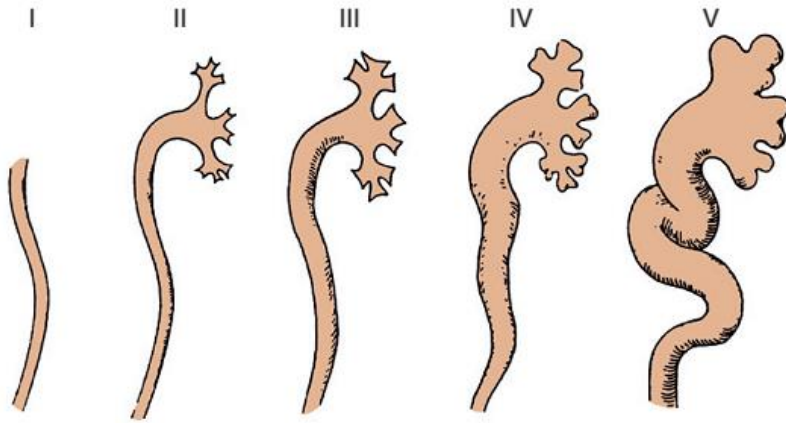
Department of Pediatric Surgery, Gulhane Military  
Medical Academy, Ankara, TURKEY

- Vesicoureteral reflux (VUR) refers to the retrograde flow of urine from the bladder into the ureter.
- In most individuals, reflux results from a congenital anomaly of the ureterovesical junction (Primary VUR), whereas in others it results from high-pressure voiding secondary to posterior urethral valves, neuropathic bladder or voiding dysfunction (Secondary VUR).



- The prevalence of VUR in normal children has been estimated at 0.4–1.8%
- Prenatally identified by ultrasonography to have hydronephrosis and who were screened for VUR, the prevalence was 16.2%
- Siblings of children with VUR had a 27.4% risk of also having VUR, whereas the offspring of parents with VUR had a higher incidence, 35.7%

# International Classification of VUR



GRADES OF REFLUX

## International Classification of Vesicoureteral Reflux

GRADE	DESCRIPTION
1	Into a nondilated ureter
2	Into the pelvis and calyces without dilatation
3	Mild to moderate dilatation of the ureter, renal pelvis, and calyces with minimal blunting of the fornices
4	Moderate ureteral tortuosity and dilatation of the pelvis and calyces
5	Gross dilatation of the ureter, pelvis, and calyces; loss of papillary impressions; and ureteral tortuosity

The main goal  preservation of kidney function

The risk factors

- age
- sex
- reflux grade
- lower urinary tract dysfunction [LUTD]
- anatomic abnormalities
- kidney status

There are divergent options in the management of VUR, from observation with or without antibiotics prophylaxis to surgical intervention using open endoscopic or laparoscopic approaches.

### Outcomes of Medical and Surgical Therapy for Children with Primary Vesicoureteral Reflux and Renal Scarring

REGISTRANT	NO. OF PATIENTS	NEW SCARS	THINNING
<b>Europe</b>			
Medical	155	19 (12%)	11 (7%)
Surgical	151	20 (13%)	15 (10%)
<b>United States</b>			
Medical	66	14 (20%)	9 (13%)
Surgical	64	16 (25%)	2 (3%)

# Factors influencing the decision

- The risk of developing a UTI, and associated risk factors for UTIs
  - such as voiding dysfunction
- Risk of development of new renal scars,
- Chance for spontaneous resolution

# Who Benefits from Correction

The focus should be on selecting patients for treatment by identifying those at risk :

- Recurrent Pyelonephritis
- VUR will not spontaneously resolve.



# rate of resolution

- age at presentation
- gender
- grade of the reflux
- laterality
- mode of clinical presentation
- ureteral anatomy
- bladder/bowel dysfunction

# Open Surgery

- Open ureteral reimplantation remains the gold standard for surgical treatment
- Success rates of 95% to 98% and low complication rates.

# Indications for Surgery

Absolute indication for surgical correction is the

- failure of nonsurgical management as evident by breakthrough UTIs or patient noncompliance.

Relative indications include the following:

- (1) high-grade (4–5) reflux
- anatomic problems,
- such as large para-ureteral diverticulum or ureteral
- duplication;
- reflux associated with impaired renal growth or function on serial
- evaluation.

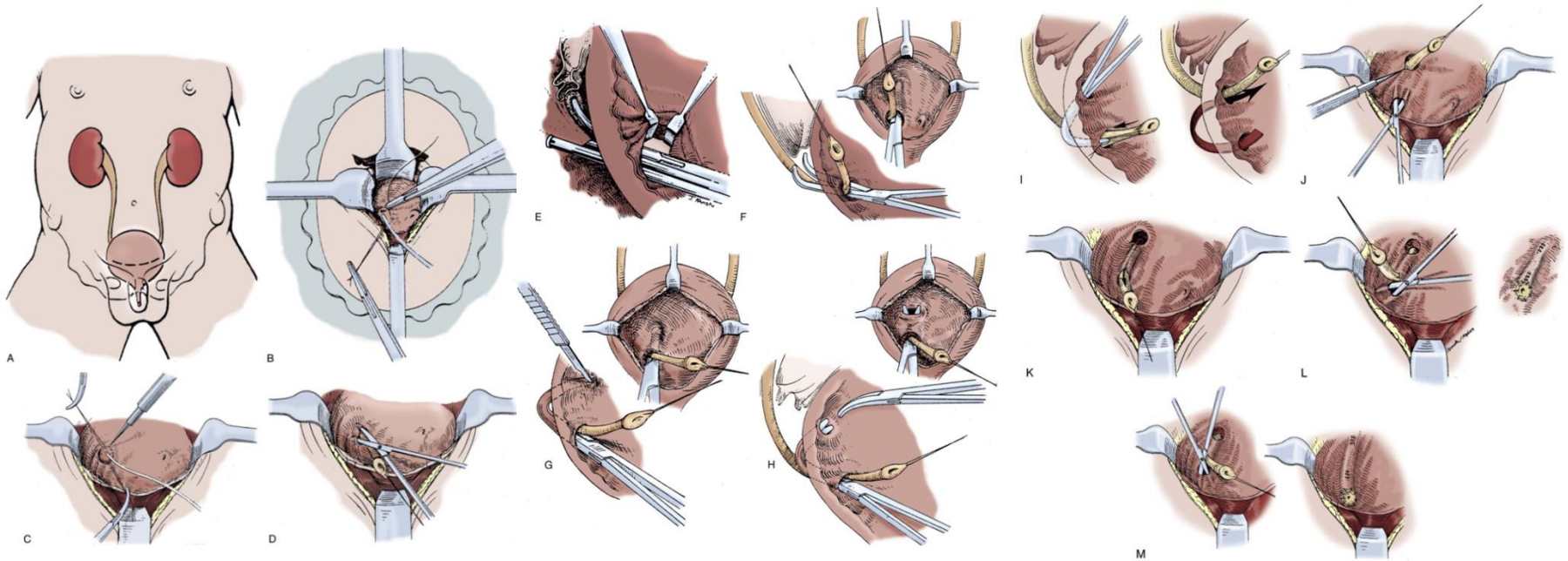
More controversial indications include

- persistent reflux in girls after puberty
- parental/physician preference to avoid the need for follow-up VUR evaluation or CAP.

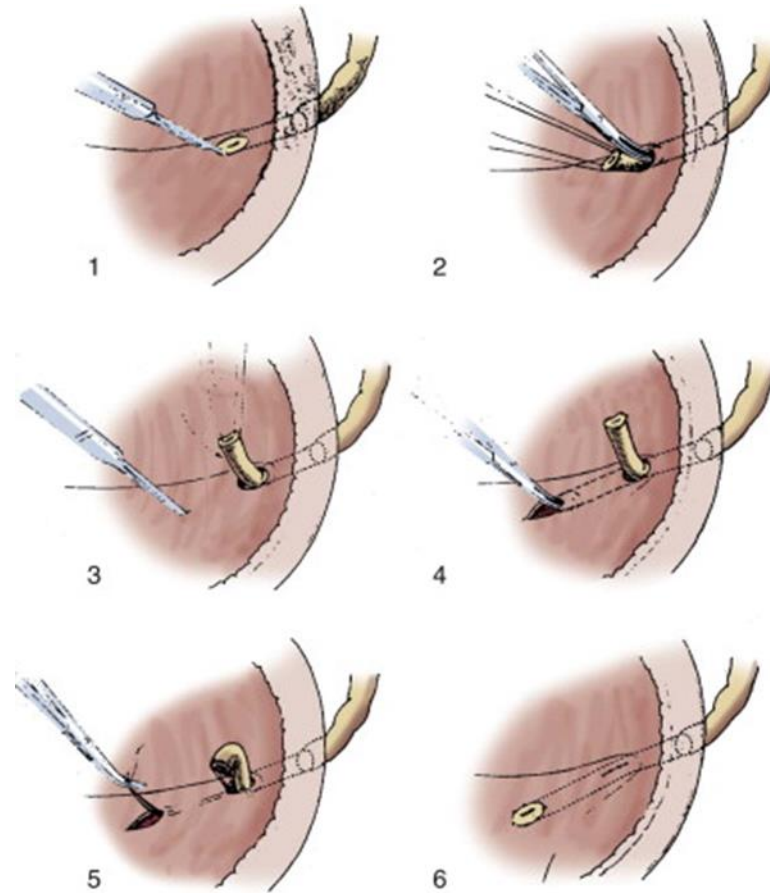
# The principles of surgical correction of reflux

- Exclusion of causes of secondary VUR
- Adequate mobilization of the distal ureter
- Creation of a submucosal tunnel ( 5 : 1 ratio)
- Attention to the entry point of the ureter into the bladder to prevent stenosis, angulation, or twisting of the ureter
- Attention to the muscular backing of the ureter to achieve an effective antireflux mechanism
- Gentle handling of the bladder to reduce postoperative hematuria and bladder spasms

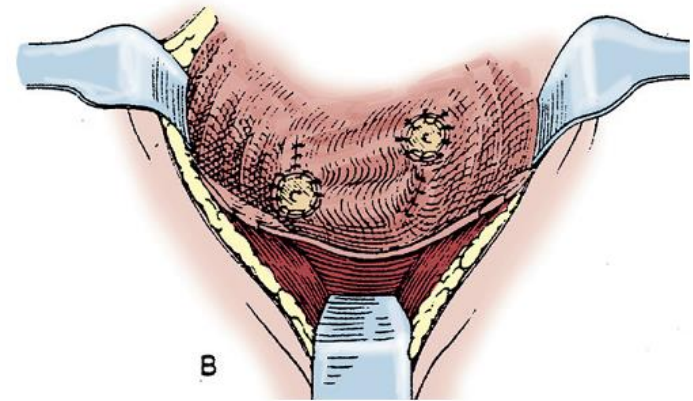
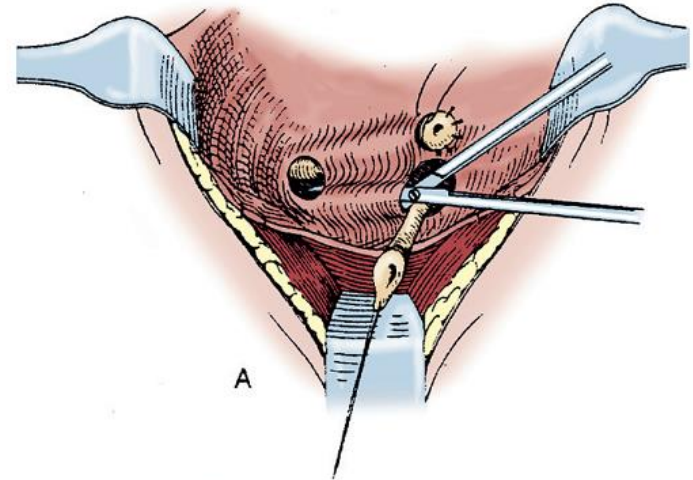
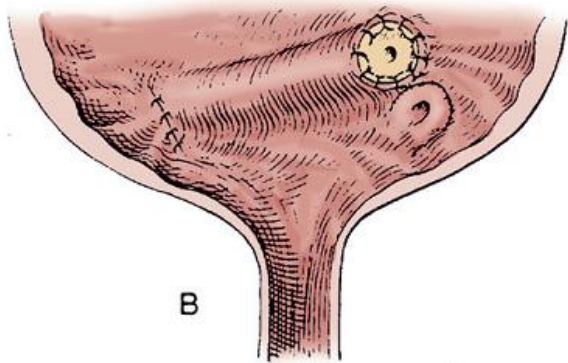
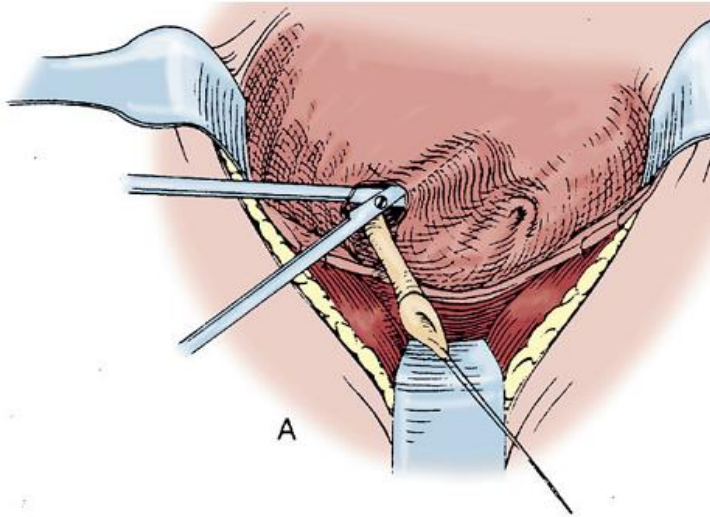
# Politano-Leadbetter Technique



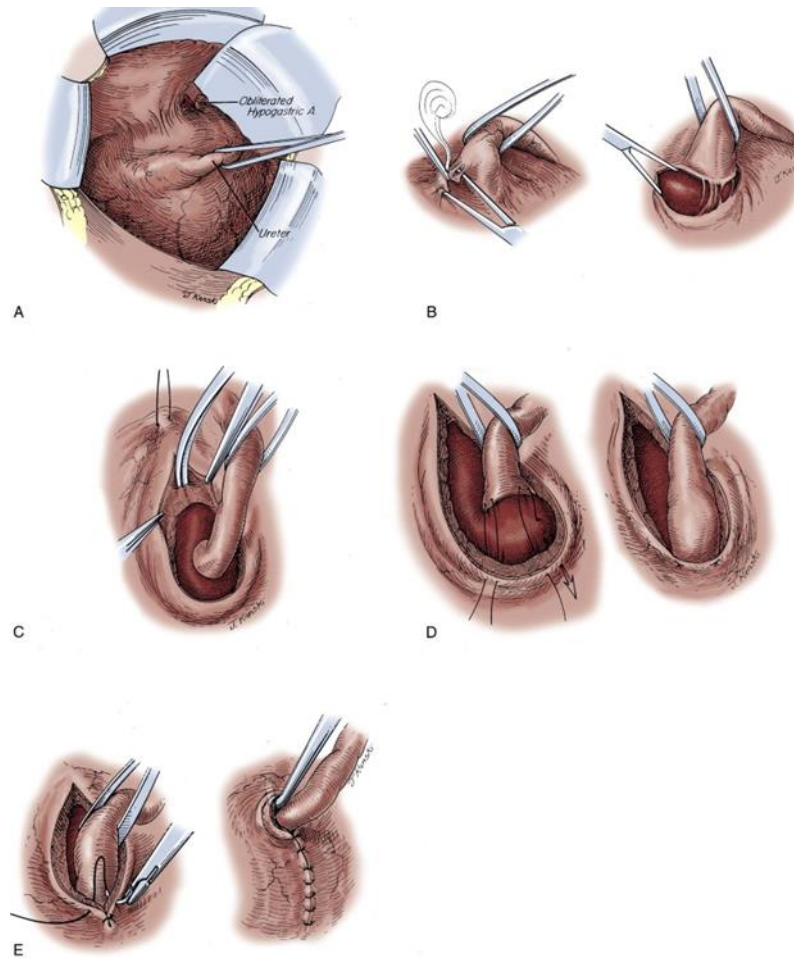
# Glenn-Anderson Technique



# Cohen's Technique



# Lich-Gregoir Technique





# Endoscopic Treatment of Vesicoureteral Reflux

## Agents used for Endoscopic Correction of Vesicoureteral Reflux

### Nonautologous Materials

Polytetrafluoroethylene (PTFE)  
 Cross-linked bovine collagen  
 Polydimethylsiloxane  
 Dextranomer hyaluronic copolymer (Deflux)  
 Coaptite

### Autologous Materials

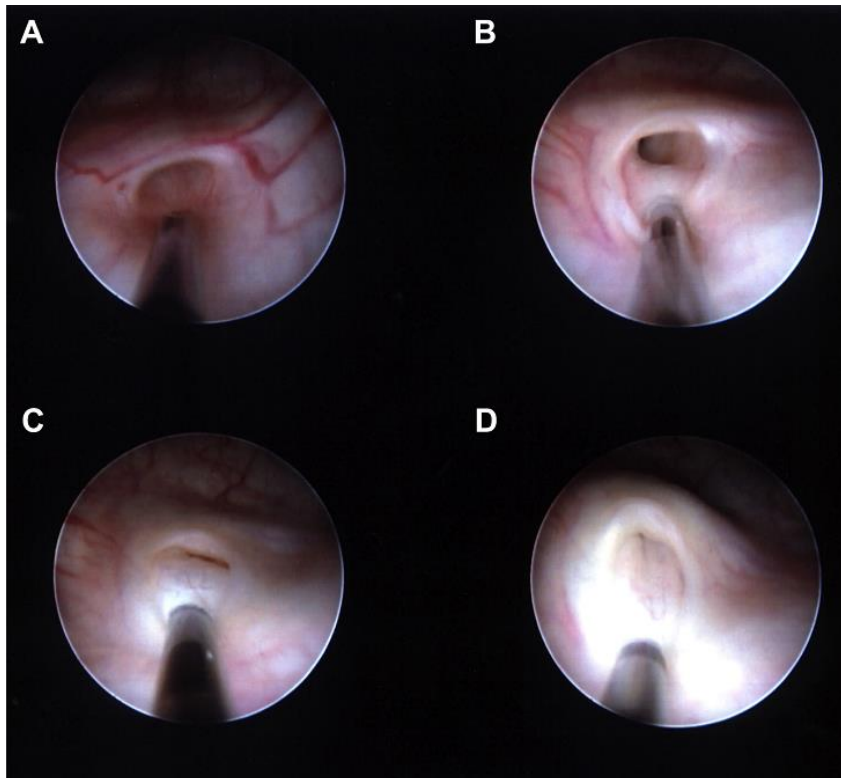
Chondrocytes  
 Fat  
 Collagen  
 Muscle

**Table 2**

**Percentage of ureters with VUR resolved following a single endoscopic injection for VUR grades I to IV**

<b>Grade of VUR</b>	<b>% Success (Ureters)</b>
I	79%
II	79%
III	72%
IV	62%

*Data from Elder JS, Diaz M, Caldamone AA, et al. Endoscopic therapy for vesicoureteral reflux: a meta-analysis. I. Reflux resolution and urinary tract infection. J Urol 2006;175:716–22.*



## **Laparoscopic ureteral reimplantation**

### Advantages

- Cosmetic
- Short hospitalisation

### Disadvantages

- Longer op.time
- Need more experience in laparoscopy

## **Robot-assisted laparoscopic ureteral reimplantation**

### Advantages

- Better view
- Better surgery

### Disadvantages:

- Higher op. cost
- Longer op.time

# Complications of VUR Surgery

## Early Complications:

- Persistent reflux
- Contralateral Reflux
- Obstruction

## Late Complications:

- Obstruction
- Recurrent or Persistent Reflux

# Conclusion

- Factors that negatively influence resolution include grade of reflux, lower bladder volume or pressure at onset of reflux, older age, female sex, bilateral VUR, ureteral duplication, abnormal or scarred kidneys, and bladder dysfunction

# Conclusion

- The treatment of VUR primarily results in a decreased rate of pyelonephritis.
- There is a high rate of cure after ureteral reimplantation.
- There is no difference in the rate of renal scarring, renal growth, and UTIs in patients treated medically or surgically for dilating VUR.
- The patients who will benefit most from surgical correction of VUR are those with recurrent pyelonephritis and/or reflux that will not resolve spontaneously.