

Hepatoprotective activity of *Murraya koenigii* leaf extract on paracetamol induced hepatic damaged rats.

Presented by :

Shyamala

M.Pharmacy 2nd year

Department of pharmacology.

UCPSc,KU.

Warangal.



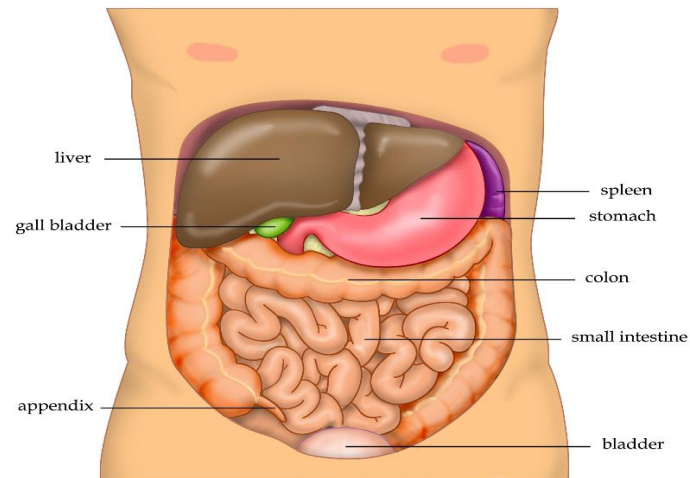
CONTENTS :

- Introduction
- Plant Profile
- Review of literature
- Aim and objective
- Plan of work
- Estimation of parameters.
- Results
- Discussion
- Conclusion
- References

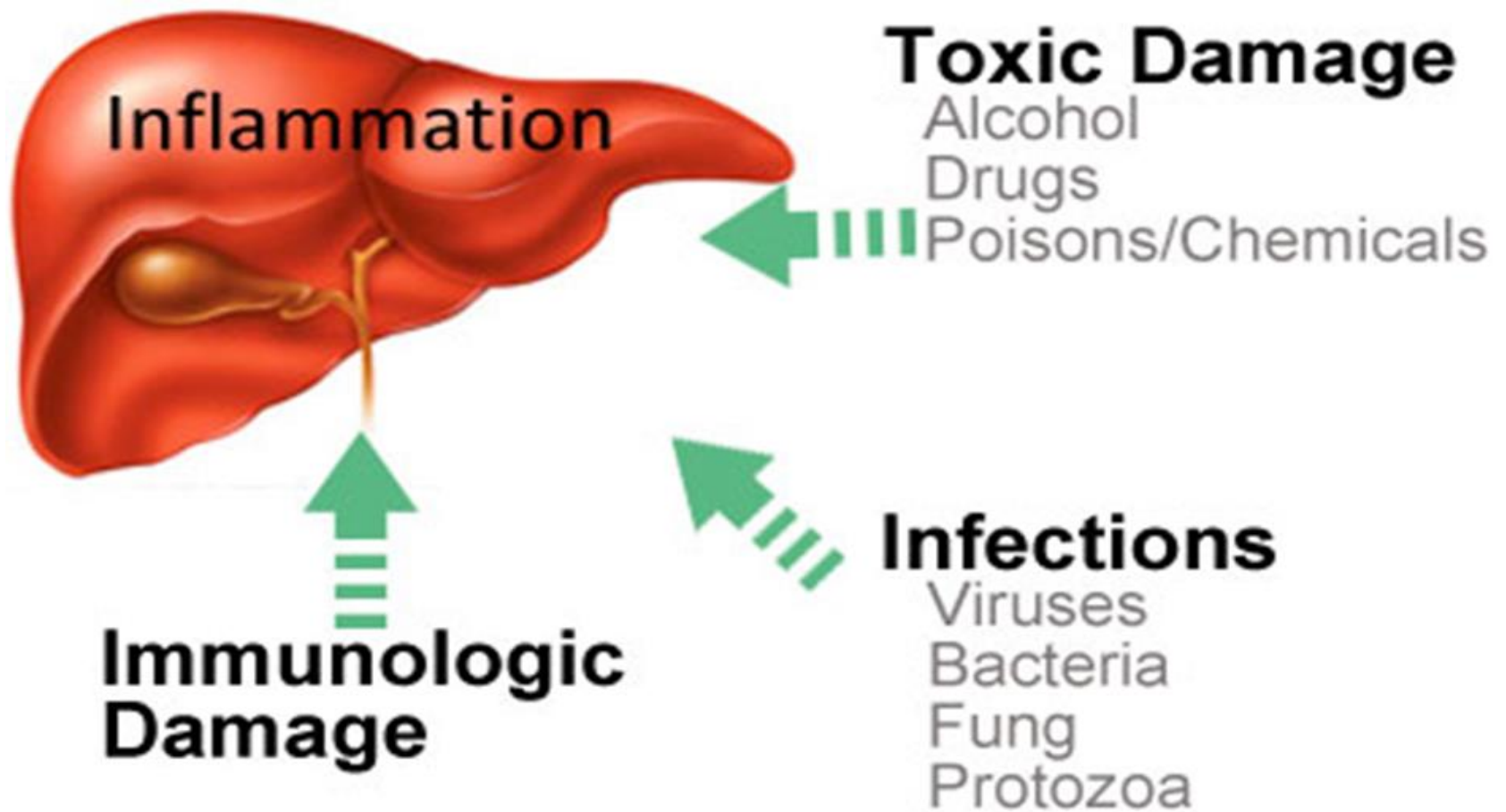


INTRODUCTION :

- Liver is the vital organ located in the upper right quadrant of the abdomen below the diaphragm.
- The liver has a wide range of functions, including detoxification of various metabolites, protein synthesis, and the production of biochemical necessary for digestion.



- Several mechanisms are responsible for either inducing hepatic injury or worsening the damage process.
- Many chemicals damage mitochondria, an intracellular organelle that produce energy. Its dysfunction releases excessive amount of oxidants that in turn injure hepatic cells.
- Activation of some enzymes in the cytochrome P-450 system such as CYP2E1 also lead to oxidative stress.
- Paracetamol is often considered as safe pain killer drug, even though overdoses this drug lead to acute liver failure.



The mode of action of paracetamol on the liver is by covalent binding of its toxic metabolite ,n-acetyl-p-benzoquinone-amine to the sulphhydryl group of protein resulting in cell necrosis and lipid peroxidation as a result of liver injury the transport function of hepatocytes gets disturbed resulting in the leakage of plasma membrane thus causing an increase in serum enzyme levels.(19,35,43)



PLANT PROFILE :(8,20,42)

➤ The **curry tree** (*Murraya koenigii* or *Bergera koenigii*) is a tropical to sub-tropical tree in the family Rutaceae

➤ **Systemic position of *Murraya koenigii*:**

| | | |
|------------|---|-------------------------|
| 1.Domain | – | Eukaryota |
| 2.Kingdom | – | Plantae |
| 3.Division | - | Angiospermae |
| 4.Class | – | Eudicots |
| 5.Order | – | Sapindales |
| 6.Family | – | Rutaceae |
| 7.Genus | – | <i>Murraya</i> |
| 8.Species | – | <i>Murraya koenigii</i> |

Names in different regional languages :

- | | | |
|-------------|---|---------------|
| 1.Telugu | - | Karivepaku |
| 2.Hindi | - | Karipatta |
| 3.Bengali | - | Kariphuli |
| 4.Gujarathi | - | Goranimb |
| 5.Kannada | - | Karibevu |
| 6.Malayalam | - | Karivepillei |
| 7.Sanskrit | - | Krishna nimba |
| 8.Tamil | - | Karivempu |
| 9.Oriya | - | Barsan |



CHEMICAL CONSTITUENTS :

some of the primary alkaloids found in the Curry Tree leaves, stems, and seeds are as follows: Mahanimbine, girinimbine, koenimbine, isomahanine, mahanine, Indicolactone, 2-methoxy-3-methyl-carbazole.



HEALTH BENEFITS OF CURRY LEAVES :

- 1.Regular consumption of curry leaves strengthens hair,cures dandruff and prevents premature graying of hair.
- 2.Application of curry leaves paste helps in treating bruises and burns as well as rashes and insect bites.
- 3.Eating curry leaves keeps liver healthy,they are beneficial in liver conditions such as cirrhosis,they also protects the liver from various infections.
- 4.Curry leaves are useful in eye problems such as cataract .they protect the eyes ,keeps the retina healthy and prevents vision loss.

5. Curry leaves are excellent source of iron and its consumption can help people who suffer from anaemia.

6. Curry leaves help lower the levels of bad cholesterol in the body. they also aid in weight loss, which removes extra pressure from the heart.

7. Health benefits of curry leaves for good digestion along with their aromatic flavour are the reasons for popularity of curry leaves usage in food.

LITERATURE REVIEW :

1.F.khanum etal (2000). Anticarcinogenic effect of curry leaves in dimethyl hydrazine treated rats.

2.Nuratikah binti m.nordin etal (2010). Evaluation of anti inflammatory activity of total alkaloids from *Murraya koenigii* leaves in rats

3.V.chinnari harika etal (2010). In vitro anti microbial activity of leaf powder.

4.Praveen sharma etal (2011). Anti ulcer activity of leaves extract of *Murraya koenigii* in experimentally induced ulcers in rats.

5.Anil kumar etal (2011). Anthelmintic activity of methanolic extract of *Murraya koenigii*

6.Dinesh kumar patidar etal (2011). Anti ulcer activity of aqueous extract of *Murraya koenigii* in albino rats.

7.Sadhana sathaye etal (2012). Hepatoprotective activity of *Murraya koenigii* against ethanol induced liver toxicity model.

8. De bosree ghosh et al (2013). Hepatoprotective activity of aqueous leaf extract of *Murraya koenigii* against lead induced hepatotoxicity.

9. Syed benazir firdaus et al (2014). Protective effect of antioxidant rich aqueous curry leaf extract against gastro toxic effect of piroxicam.

10. Lokesh et al (2014). Evaluation of cns stimulant and analgesic activity of *Murraya koenigii*.

AIM AND OBJECTIVE :

Aim :

To evaluate the hepatoprotective activity of *Murraya koenigii* which was investigated in paracetamol induced hepatic damaged rats.

Objective :

Paracetamol in over doses causes lipid peroxidation, extracts were given to evaluate the SGOT, SGPT, etc levels.

PLAN OF WORK :

- **Collection of plant material.**
- **Extraction**
- **Phyto chemical analysis**
- **Acute toxicity studies**
- **Screening method**

SCREENING METHOD :(23,24,35)

Wistar rats were divided into different groups of 6 each.

Group 1 – Control

Group 2 – Standard (100mg/kg.b.wt)

Group 3 – Toxic control (2g/kg.b.wt)

Group 4 – Test 1 (200mg/kg.b.wt)

Group 5 – Test 2 (400mg/kg.b.wt)

ESTIMATION OF PARAMETERS : (19,37,40,43,)

- 1.Estimation of SGOT.
- 2.Estimation of SGPT.
- 3.Estimation of total protein by BIURET method
- 4.Estimation of bilirubin
- 5.Estimation of albumin by BCG method
- 6.Estimation of alkaline phosphatase
- 7.Histopathological investigations.

TOTAL PROTIEN ESTIMATION (BIURET METHOD)

➤ Principle:

Proteins in alkaline medium bind with cupric ions present in biuret reagent to form a purple colored complex. The intensity of colour formed is directly proportional to the amount proteins present in the sample. (555nm)



ALBUMIN ESTIMATION (BCG METHOD)

➤ Principle:

Albumin binds with bromocresol green (BCG) and produce a green colour whose absorbance is proportional to the albumin concentration.(630nm)

BILIRUBIN ESTIMATION

(Modified Jendrassik and Grofs method)

➤ Principle:

Bilirubin reacts with diazotised sulphanilic acid to form azobilirubin, a pink coloured complex whose absorbance is proportional to bilirubin concentration. Direct bilirubin, being water soluble is allowed to react with diazotised sulfanilic acid the absence of an activator, while for the total bilirubin (direct and indirect) the diazotisation is carried out in the presence of an activator. The unconjugated bilirubin couples with the sulphanilic acid in the presence of a caffein-benzoate accelerator.(540nm)

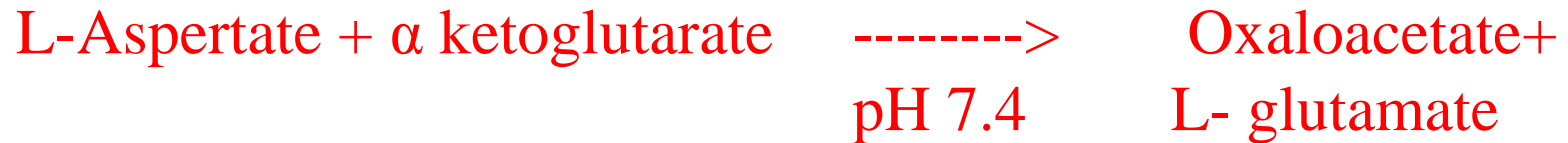ESTIMATION OF SGOT (AST)

Reitman and Frankel's method :

➤ Principle:

SGOT converts L-Aspartate and α ketoglutarate to oxaloacetate and glutamate. The Oxaloacetate formed reacts with 2,4, Dinitro phenyl hydrazine to produce a hydrazone derivative which in an alkaline medium produces a brown coloured complex whose intensity is measured. (340nm)

SGOT :



alkaline



ESTIMATION OF SGPT (ALT)

Reitman and frankel's method

SGPT converts L-Alanine and α ketoglutarate to pyruvate and glutamate. The pyruvate formed reacts with 2,4, Dinitro phenyl hydrazone derivative, which in an alkaline medium produces a brown coloured complex whose intensity is measured. (340nm)

SGPT

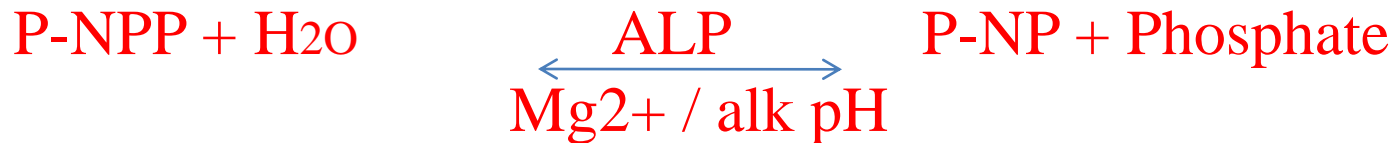
L-Alanine + α - ketoglutarate -----> pyruvate + L-glutamate

Ph 7.4

Pyruvate + 2,4, DNPH -----> 2,4, Dinitrophenyl hydrazon
(black coloured complex)

ESTIMATION OF ALKALINE PHOSPHATASE : (P-NPP Kinetic method)

Serum ALP hydrolyses P-NPP into yellow coloured p-nitrophenol at the alkaline pH. the rate of P-NP formation is directly proportional to the ALP activity and is measured in terms of changes in absorbance at 405nm in uv visible spectrophotometer.



HISTOPATHOLOGICAL INVESTIGATION :

On the 8th th day the animals were sacrificed and abdomen was cut open , the liver was dissected out. Liver was rinsed in saline and preserved in 10% formalin solution. The samples were given to the pathological laboratory for further histopathological examination. magnification of the changes of liver (X100) histopathology from control, paracetamol intoxicated and pretreatment with different test groups .

RESULTS:

Results of hepatoprotective activity were expressed as mean & sd (n=6).the significance between two groups was determined by ONE WAY ANOVA(graph pad prism software) followed by DUNNETT multiple comparision.

$p < 0.05^*$, $p < 0.01^{**}$, $p < 0.001^{***}$, compared between standard and test group

TABLE 1:

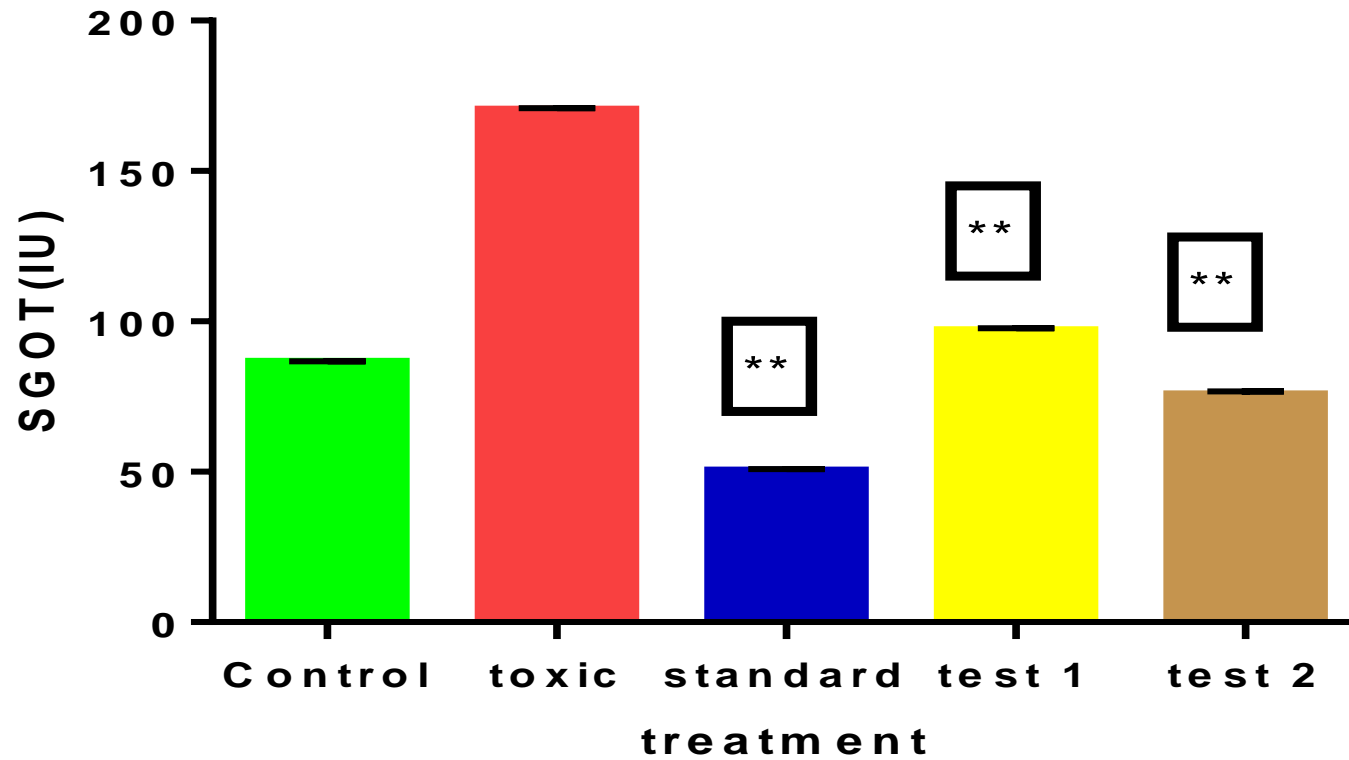
| CHEMICAL CONSTITUENTS | TEST | INFERENCE |
|------------------------------|---|------------------|
| alkaloids | Dragondroffs Mayers Hagers | + |
| Carbohydrates | Molish Fehling Benedict | + |
| Steroids | Salkowski Liebermann burchard | + |
| Glycosides | Legal Keller killiani Modified borntrager | + |
| Proteins | Biuret Ninhydrin | + |
| Flavanoids | Shinoda Naoh | + |
| Tannins and phenols | 5% fecl3 leadacetate | + |
| saponins | Foam test | + |

TABLE 2:

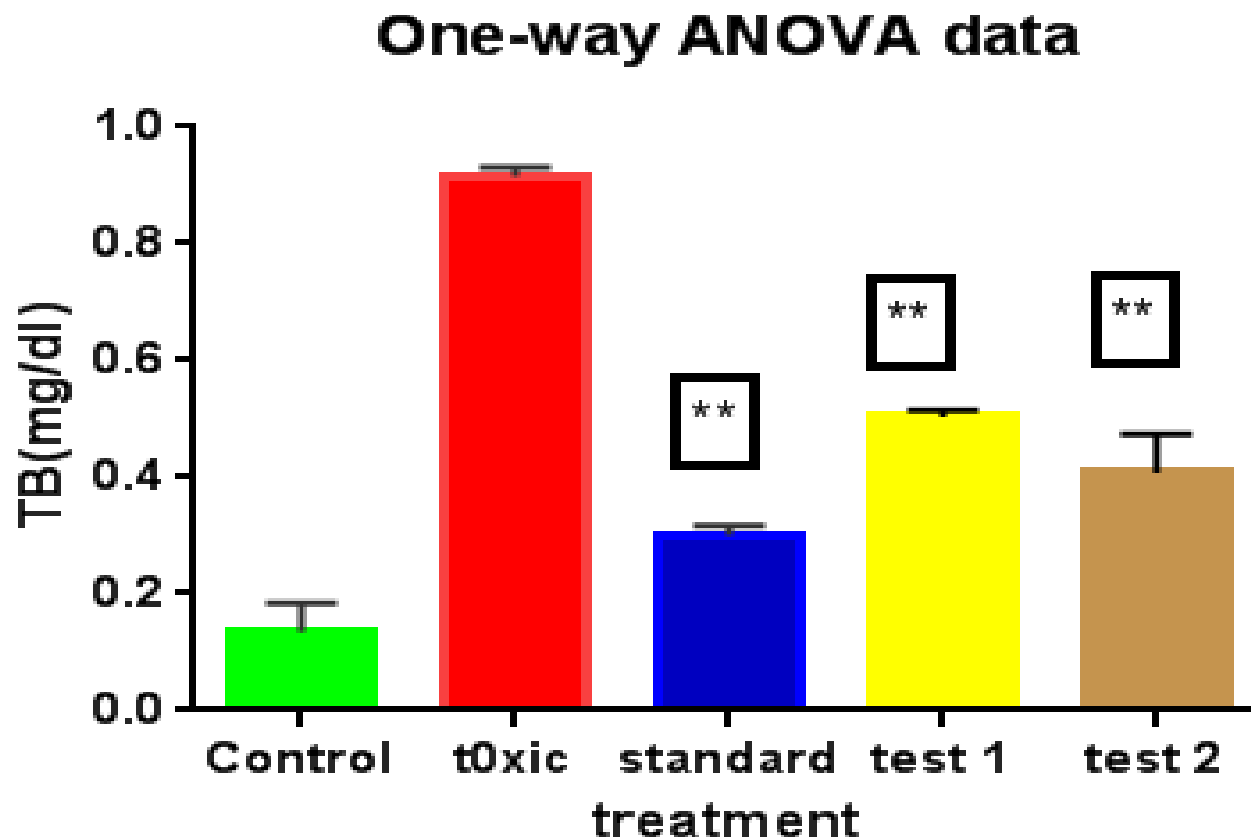
| GROUPS | TOTAL PROTEIN(gm%) | ALBUMIN (gm%) | TOTAL BILIRUBIN (mg/dl) | DIRECT BILIRUBIN (mg/dl) | AST(SGOT) (IU/l) | ALT(SGPT) (IU/l) | ALKP(IU /L) |
|----------|---------------------|---------------|-------------------------|--------------------------|-------------------|------------------|--------------|
| Control | 7.2±0.62 | 2.2±0.20 | 0.15±0.03 | 0.50±0.04 | 86.45±5.40 | 42.63±5.79 | 183.1±0.3 |
| Toxic | 5.05±0.91 | 0.36±0.21 | 0.91±0.03 | 0.95±0.03 | 170.1±6.80 | 147.3±8.06 | 2559.8±0.2 |
| Standard | 6.7±0.54* | 2.1±0.33* | 0.30±0.03*** | 0.42±0.04*** | 55.1±6.39** | 59.31±9.81* | 194.6±0.5** |
| Test1 | 6.0±0.65* | 1.38±0.34* | 0.50±0.03*** | 0.61±0.03*** | 96.8±5.75** | 110.5±5.20* | 200±0.6** |
| Test2 | 6.2±0.63* | 1.80±0.39* | 0.40±0.04*** | 0.518±0.03*** | 75.6±6.29** | 95.6±5.19* | 159.6±0.62** |

SGOT :

One-way ANOVA data

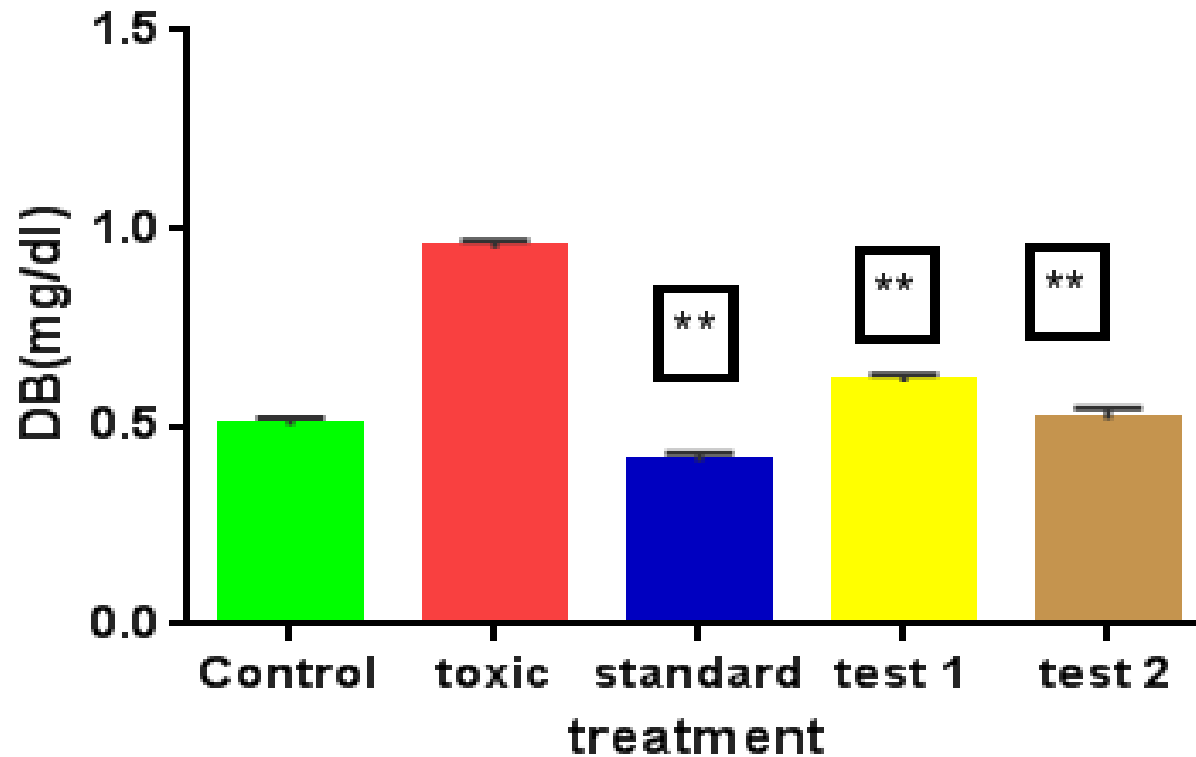


TOTAL BILIRUBIN :

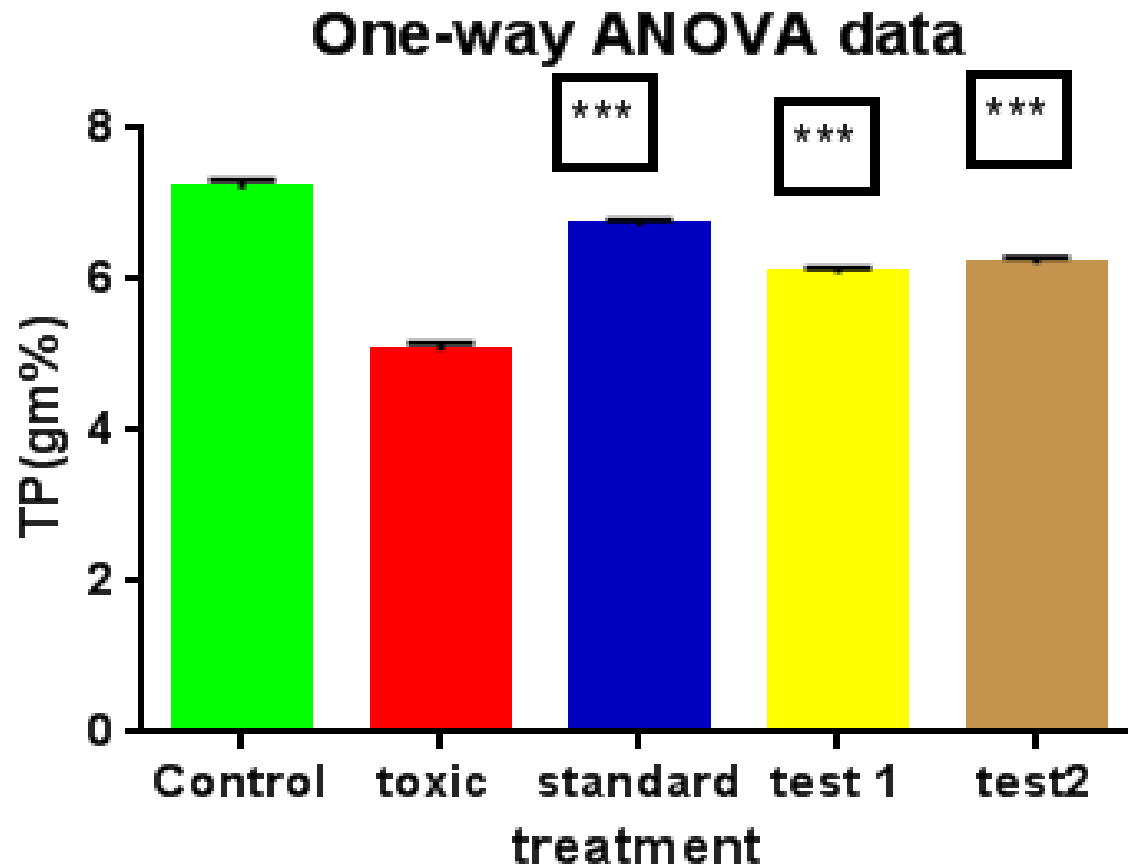


DIRECT BILIRUBIN :

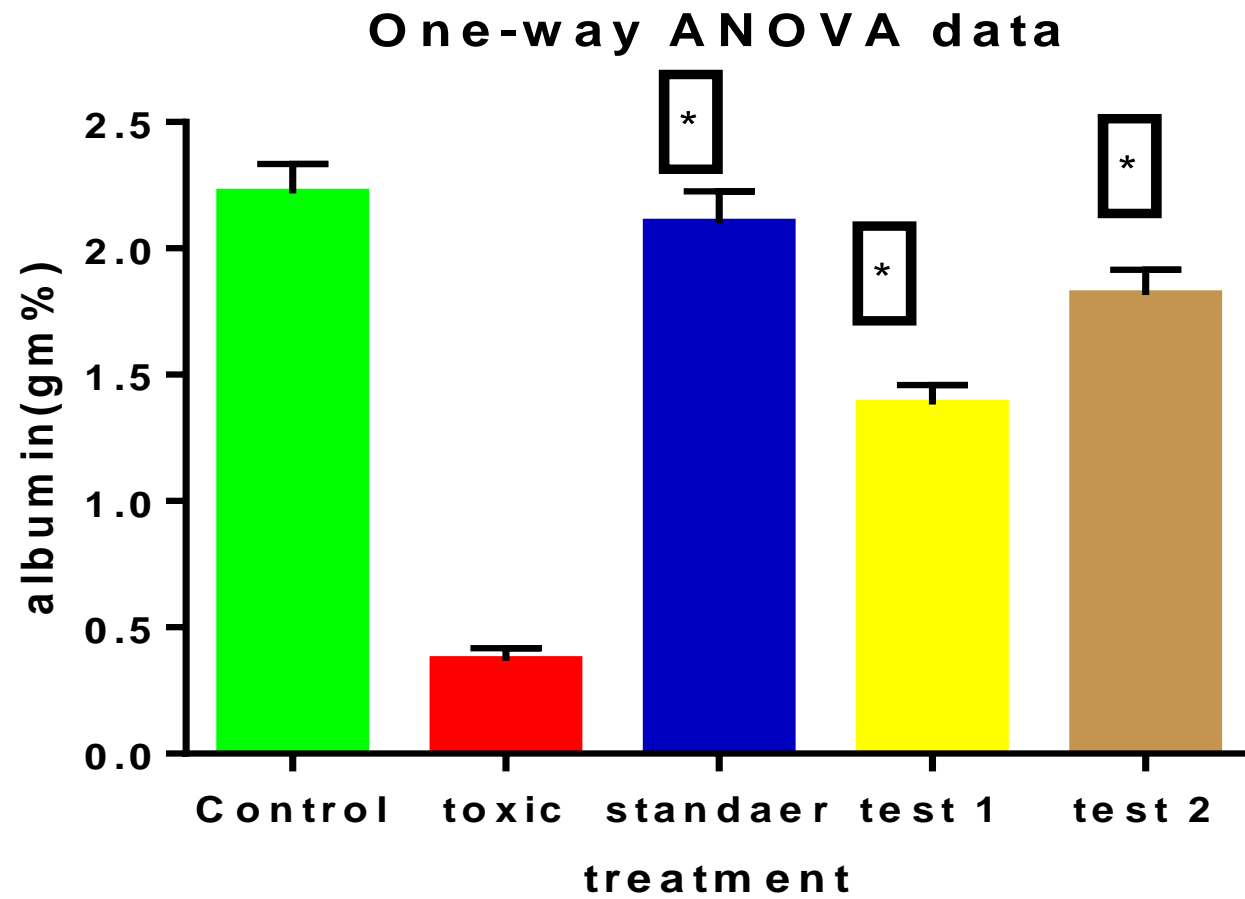
One-way ANOVA data



TOTAL PROTEIN :

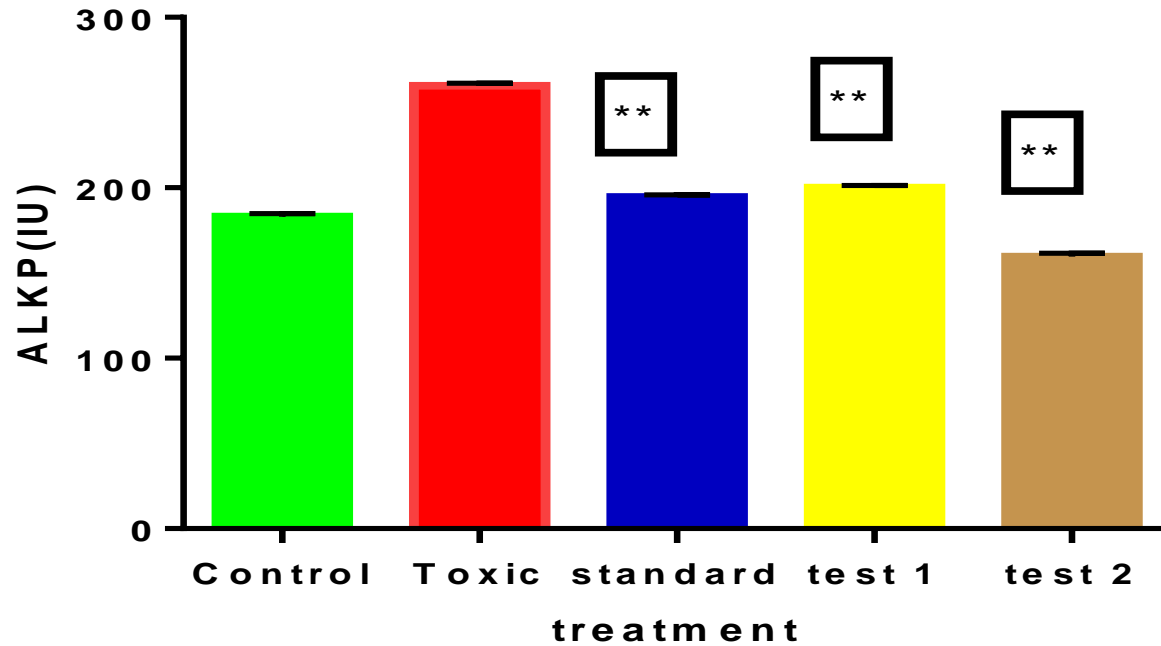


ALBUMIN :



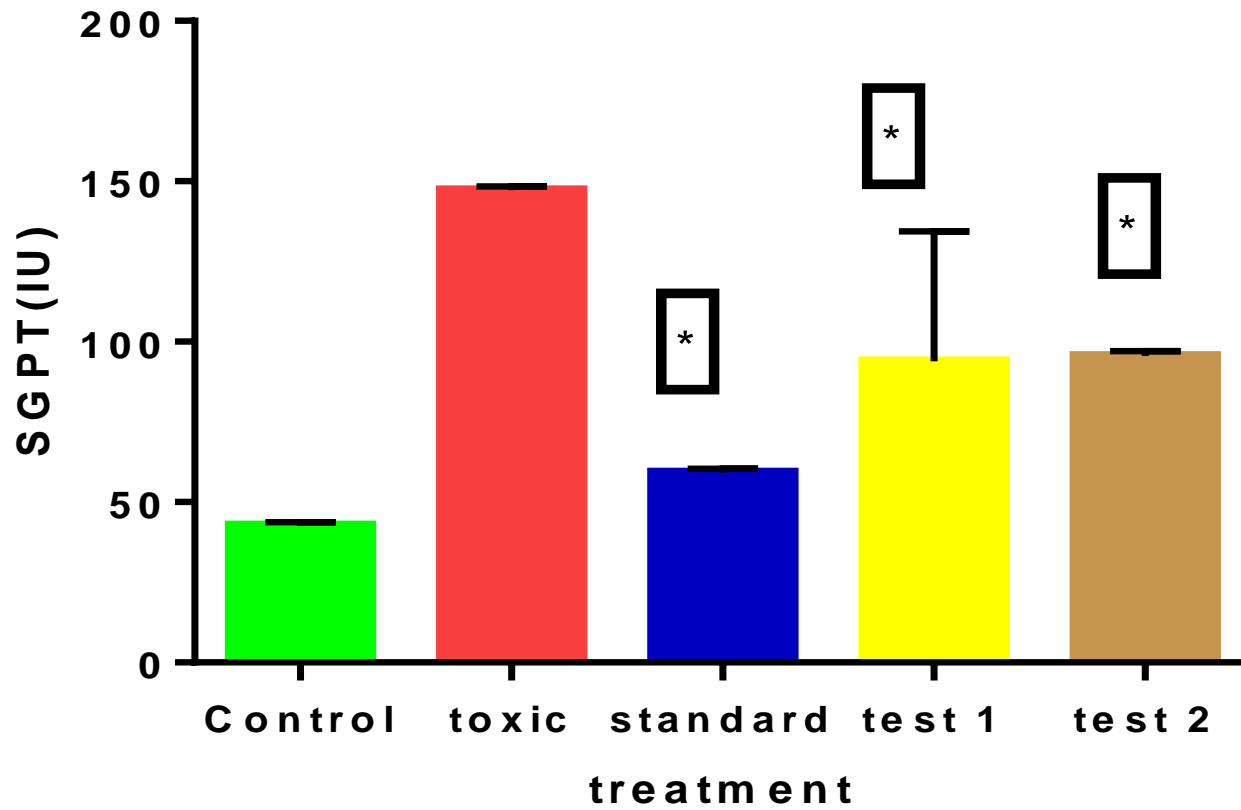
ALKALINE PHOSPHATASE :

One-way ANOVA data

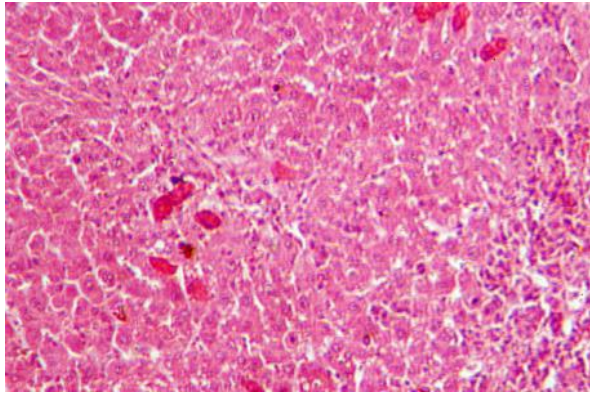


SGPT :

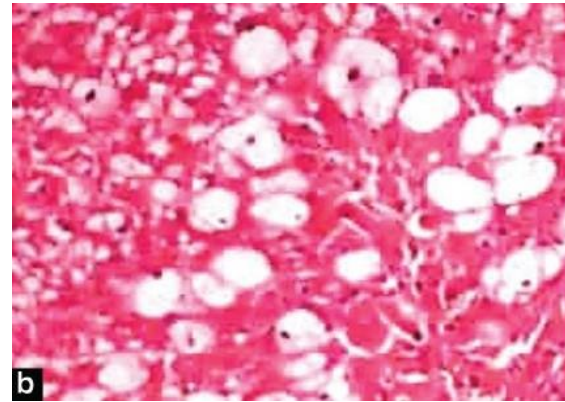
One-way ANOVA data



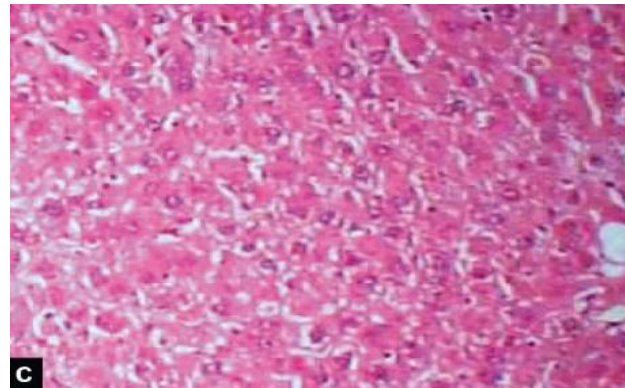
HISTOPATHOLOGY :



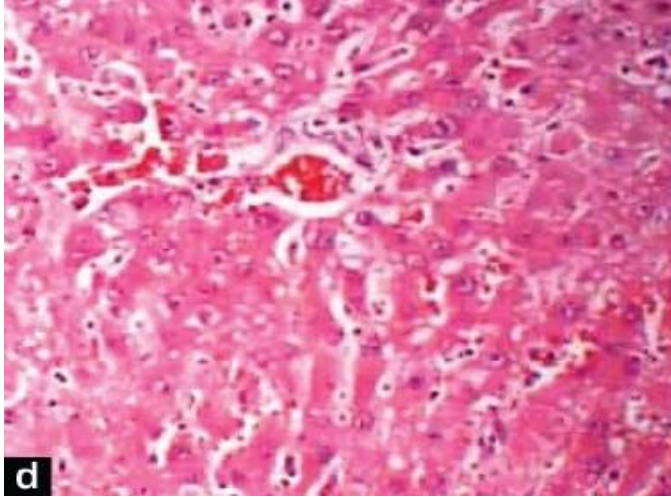
CONTROL



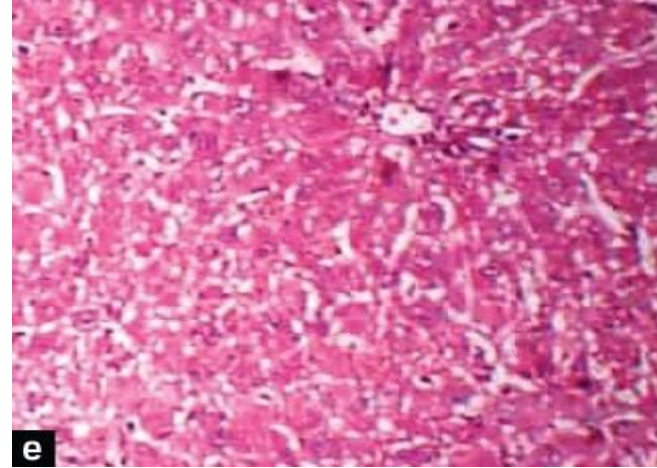
TOXIC



STANDARD



TEST 1



TEST 2

DISCUSSION :

From the obtained results it was evident that after 7 days of treatment with the test compound, Reduction in the levels of Serum Bilirubin, SGOT and SGPT towards the normal value is an indication of regeneration process.

The protein and albumin levels were raised suggesting the stabilization of endoplasmic reticulum leading to protein synthesis.

The protective effect exhibited by Test compounds at dose level of 200 mg/kg, 400mg/kg was comparable with the standard drug silymarin.

The histological examination of the liver sections reveals that the normal liver architecture was disturbed by hepatotoxin intoxication.

Normal control group shows normal hepatic cells, whereas administration of paracetamol in toxic control caused gross necrosis and periportal infiltration and the architecture was partly distorted.

Among these 2 compounds, Test compound 2 has more potent activity than Test compound 1 and at dose 400mg/kg and shows more liver protecting activity and liver sections shows normal architecture very nearer to the standard silymarin.

CONCLUSION :

Therefore the study scientifically supports the usage of the plant as hepatoprotective agent.

Further studies are required to:

- *Find the active constituent.
- *Isolate the active constituent and
- *Find the mechanism of action responsible for hepatoprotective activity.

REFERENCES :

- 1) Aashish pandit ,Drug induced hepatotoxicity,Journal of applied pharmaceutical sciences, 02(05) ,2012;233-243.
- 2). Achiliya GS, Kotgale SG, Wadodkar AK, Dorle AK. Hepatoprotective activity of *gritha* in carbontetrachloride-induced hepatotoxicity in rats. Indian Journal of Pharmacology. 2003; 35: 311.
- 3) Akhilesh Sharma, A review on the plants used in liver diseases, International journal of research in pharmacy and chemistry, 1(2), 2011; 2231-2781.
- 4). Akerele O. Summary of WHO guidelines for the assessment of herbal medicine. Herbalgram. 1993; 28: 13-19.
- 5) Anandan R, Deavaki T. Hepatoprotective effect of *Picrorrhiza kurroa* on tissue defense system in galactosamine induced hepatitis in rats. Fitoterapia. 1999; 70(1): 54-7

6.) Anil Kumar , Anthelmintic Activity of Methanolic Extract of *Murraya koenigii* Leaves (Linn) , International Journal of Research in Pharmaceutical and Biomedical Sciences, Vol. 2(4) , 1698-1700 , Oct - Dec 2011.

7) Ansari SH. Essential of Pharmacognosy, Birla Publications. Delhi. 2007; 27:87.

8) Bahar ahmed, Hepatoprotective activity of two plants belonging to the Apiaceae and the Euphorbiaceae family, journal of ethnopharmacology, Elsevier, 79, 2002; 313-316.

9) Balister WF, Shaw LM, Biochemical assessment of liver, In Fundamentals of clinical chemistry, Saunders Co, Philadelphia, 1982: 729-61.

10) Bhattacharjee SK. Habitat Handbook of Medicinal Plants. Pointer Publishers, Jaipur, 2001, 128-130.

- 11) Binduja Saraswat PKS, Dayal Visen R, Agarwal DP, Patnaik GK. Protective action of Ursolic acid against chemical induced hepatotoxicity in rats. Indian Journal of Pharmacology. 1996; 28: 232-239.
- 12) Baheti JR, Goyal RK, Shah GB. Hepato Protective activity of *Hemidesmus Indicus* in rats, Indian Journal of pharmacology. 2006; 4:399-402.
- 13) Bonoranjan phukan, Hepatoprotective activity of *Justicia gendarusa* linn, leaves in carbon tetra chloride induced liver injury in mice, Journal of natural remedies, 14(2), 2014; 2320-3358.
- 14) Casimiro, Evaluation of hepatoprotective activity of *Citrus microcarpa* bunge fruit peel against acetaminophen induced liver damage in male Sprague dawley rats, International journal of chemical and environmental engineering, 1(2), 2010; 127-132.
- 15) CK. Kokate . Practical pharmacognosy, 2nd ed. New Delhi: Vallabh Prakasham, 1988: 111-113.

- 16)C.Girish , Koner BC, Jayanthi S, Rao KR, Rajesh B, Pardhan SC. Hepatoprotective activity of six polyherbal formulations in carbon tetra chloride induced Liver toxicity in mice. Indian Journal of Experimental Biology. 2009; 47: 257-63.
- 17).Chatterjee, T.K. “Medicinal Plants with Hepatoprotective Properties”. Herbal Options. Books and Applied Allied (P) Ltd 143,2000.
- 18)Chinnari harika.V , in vitro anti microbial activity of leaf powder , international journal of Research in pharmaceutical and biomedical sciences , 1(2) , 2011.
- 19).Dinesh kumar patidar , Anti ulcer activity of aqueous extract of *Murraya koenigii* in albino rats , international journal of pharma and biosciences 2(1)524-529 , 2011.
- 20).Deepak k.dash.evaluation of hepatoprotective and antioxidant activity of *Ichnocarpus frutescens*,6(3);755-765,2007.tropical journal of pharmaceutical research.

21)Evan prince sabina , hepatoprotective and antioxidant potential of *withania somnifera* against paracetamol-induced liver damage in rats , International Journal of Pharmacy and Pharmaceutical Sciences , Vol 5, Suppl 2, 648-651 , 2013.

22)Evans WC. Trease and Evans. Pharmacognosy. WB Saunders Limited, London, 2002.

23) Ghosh MN. Fundamentals of experimental pharmacology, Hilton & Company, Kolkata.2005; 31:23-125.

24).Guptha SK. Drug Screening Methods, Pharmacology, Japee Brothers Medical Publishers 2: 511-514, 2009.

25)Gul T singh,Biochemical alteration of methanolic extract of *Amaranthus spinosus* on liver of Sprague dawley rats ,Biology and medicine,3(2),2011;365-369

26) Guyton AC, Hall JE. in Textbook of medical physiology, A Harcourt Publishers International Company, Singapore, 2006;10: 789-812.

27) H.A. Lawal, Hypoglycaemic and hypolipidaemic effects of the aqueous leaf extract of *Murraya koenigii* in normal and alloxan – diabetic rats, Nigerian journal of physiological sciences, 23(1-2), 2008; 37-40.

28) Maryam Bincy Thomas, Sharada Pal Singh, Plants used in hepatoprotective remedies in traditional Indian medicine, Indian Journal of Research in Pharmacy and Biotechnology. 2006; 47: 660-667.

29). Muthumani. P , Pharmacological studies of anticancer, anti-inflammatory activities of *Murraya koenigii* (Linn) Spreng in experimental animals , journal of pharmaceutical sciences and research , Vol.1(3), 137-141 , 2009 .

30) Mukesh tanwar, Antioxidant and hepatoprotective activity of *Trichosanthes dioica* roxb on paracetamol induced toxicity , International journal of of pharmaceutical studies and research , vol – 2-1, 2011; 110-121.

- 31).Nuratikah binti , evaluation of anti inflammatory activity of total alkaloid from *Murraya koenigii* leaves in rats.
- 32).Praveen sharma , anti ulcer activity of leaves extract of *Murraya koenigii* in experimentally induced ulcer in rats , pharmacology online , 2:818-824 , 2011.
- 33). Pravin v. Gomase , phytochemical evaluation and hepatoprotective activity of fresh juice of Young stem (tender) bark of *Azadirachta indica a.* , International journal of pharmacy and pharmaceutical sciences , vol 3, suppl 2, 55-59 ,2011 .
- 34) Rajesh kumar , hepatoprotective activity of aerial parts of *Plumbago zeylanica* linn against carbon tetrachloride-induced hepatotoxicity in rats , international journal of pharmacy and pharmaceutical sciences , 1(1) , 171-175 , 2009.
- 35)Rajasekara A, Periyaswami M. Hepatoprotective activity of ethanolic extract of *Trichosanthes lobata* on paracetamol induced liver toxicity in rats, Pubmed, 2012;26:127-129.

36).Rang, H.P., Dale, M.M., Ritte, J.M., Flower, R..J.,
Pharmacology 6:375,2007.

37) Sadhana sathaye , hepatoprotective activity of *Murraya koenigii* against ethanol induced liver toxicity model in experimental animals , international journal of pharma and bio sciences , vol 3, issue 1 , 430-438 , jan – mar 2012

38)Simran Aneja, Manisha Vats, Phytochemistry and hepatoprotective activity of aqueous extract of *Amaranthus tricolor* Linn roots, Journal of Ayurvedha and Integrative medicine. 2013;4:211-215.

39).Syed benazir firdaus , protective effect of anti oxidant rich aqueous curry leaves extract , toxicology report , Elseiver , 1 , 987-1003 , 2014.

40)Sree Ramamurthy M, Srinivasan M. Hepatoprotective effect of *Tephrosia purpurea* in experimental animals. Indian Journal Pharmacology. 1993; 25: 34-36.

41).Tortora, G.J, Grabowski,A.R, Principles of Anatomy and Physiology, John Wiley and Sons, Inc, United States of America 10:876-880, 2003.

42)Vandana,An updated review of *Murraya koenigii*,International journal of ayurvedic and herbal medicine,2:4,2012;607-627.

43)Veena Nayak, Gincy TB, Prakash M, Chitralkha Joshi, Soumya SR, Somayaji SN, Nelluri Venu Madhav, Bairy KL.
Hepatoprotective activity of *Aloe vera* Gel against Paracetamol Induced Hepatotoxicity in albino rats, Asian J Phar Bios Res. 2001;2:94-98.

44).Vinod kumar kanaujia,Evaluation of hepatoprotective activity on the leaves of *Ficus benjamina* linn,Scholars research library,1(3),2011,59-69.

Thank

