

Curcumin prolongs graft survival in mouse corneal allografts

Dr. Radhakrishna G Pillai
Department of Life Sciences
University of Calicut

Corneal transplantation

- Corneal grafting is the most common form of solid tissue transplant
- The possibility proposed by Erasmus Darwin 250 years ago
- 32,000 grafts every year in the US alone
- Cornea- immune privileged
- Corneal transplantation is a highly successful procedure
- Still significant rates of graft failure



Rejection of corneal transplants

- long-term survival -approximately 75% at 5 years and 60% at 10 years
- *high risk groups, the incidence of graft failure is higher*
- *The most common form of graft failure-*
immune reaction against the allogeneic grafts
- Important to develop strategies to prevent or reduce the impact of graft rejection

Corneal graft rejection and chemokines

- In animal models of corneal allograft rejection - considerable up-regulation of chemokine expression
- increased expression of RANTES (CCL5), MIP-1 (CCL3), MIP-1 (CCL4), MIP-2 (CXCL2), and MCP-1 (CCL2) in both combinations, with stronger IP-10 up-regulation
- Little up-regulation of Eotaxin (CCL11) seen in murine transplants *though there was up-regulation of Eotaxin in a guinea pig to mouse xenograft setting*

Corneal graft rejection and chemokines

- *In murine* grafts performed into a vascularized corneal bed (high risk graft) -more rapid and higher up-regulation of
 - MIP-1, MIP-2, eotaxin, MCP-1, and RANTES early after transplantation (before onset of rejection) when compared with low risk grafts
 - This is associated with an increase in infiltrating macrophages and neutrophils
- *Treatment of animals* with agents to prevent rejection resulted in a decrease in chemokines that were measured
- vMIPII experience

Curcumin- anti-inflammatory agent

- Extensively used in Ayurvedic preparations for centuries
 - Antioxidant
 - Anti-inflammatory
 - Antiseptic activity
 - Analgesic
- Inhibits nuclear factor NFκB – regulates angiogenesis
- Constrains VEGF and angiopoietin
 - Prevents angiogenesis

Curcumin- an inflammatory agent

- Previous reports revealed the effect of curcumin in
 - Scavenging NO
 - blocking the release of cytokines like;
 - IL1 β , IL4, IL6, IL10, IL17, IL22
 - TNF α
 - MCP1
- Almost 100 companies produces curcumin products
- Over 100 clinical trials focusing on chronic diseases including diabetes and cancer

Animals used

Orthotopic corneal transplantation was performed in the right eye of 6- to 10-week-old mice, as described

Transplant

Syngeneic: BALB/c mice recipients and BALB/c donor

Allogeneic: BALB/c mice recipients and C3H/HeJ as donors

Curcumin treatment- recipient mice were treated with curcumin

**Anaesthetic – 50mg/kg
Pentobarbital (ip)**

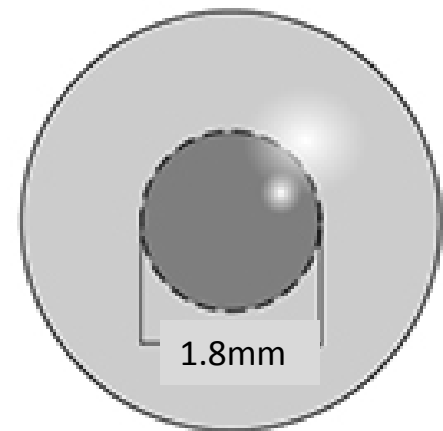
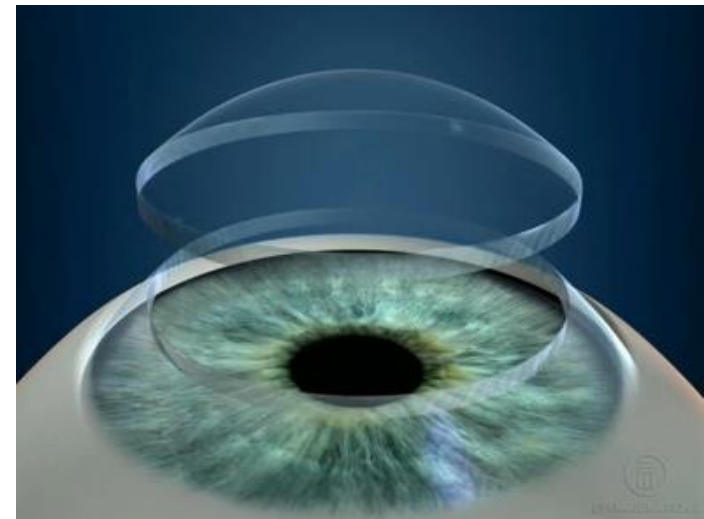

Curcumin administration

- 1g Curcumin (Sigma) was dissolved in 10ml 0.1 N NaOH and was diluted to a concentration of 50 *mg/ml* using PBS which brought down the pH to 7.2
- The integrity of the curcumin was checked by TLC analysis
- The experimental group received 50mg/kg curcumin each day by IP injection
- Curcumin administration started on the day before transplantation
- The control group was sham given with NaOH+PBS in the same manner
- The mice received regular, non-fortified food pellets

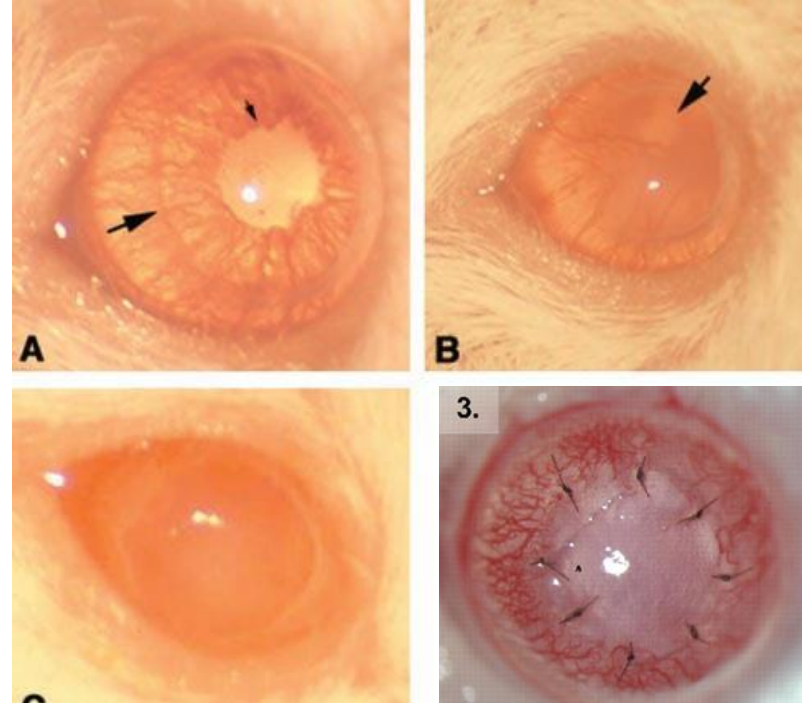
Corneal transplantation

- The central 2-mm area of the donor cornea was excised with Vannas scissors
- Secured in the host graft bed of 1.8-mm diameter with eight interrupted 11-0 nylon sutures
- Antibiotic ointment was applied to the corneal surface
- The eyelids were closed for 3 days with a tarsorrhaphy using 8-0 nylon sutures



Examination and scoring

- All grafted eyes were examined 3 days after surgery
- Transplants were examined on every second day using slit lamp microscopy to assess signs of rejection
- Under Isoflurane anaesthesia
- Sutures were removed on the seventh day post-transplantation



Technically satisfactory grafts had corneal opacity grade 0 to 1 at all times until suture removal on day 7

Signs of rejection were scored using a standard grading scheme

Scoring rejection

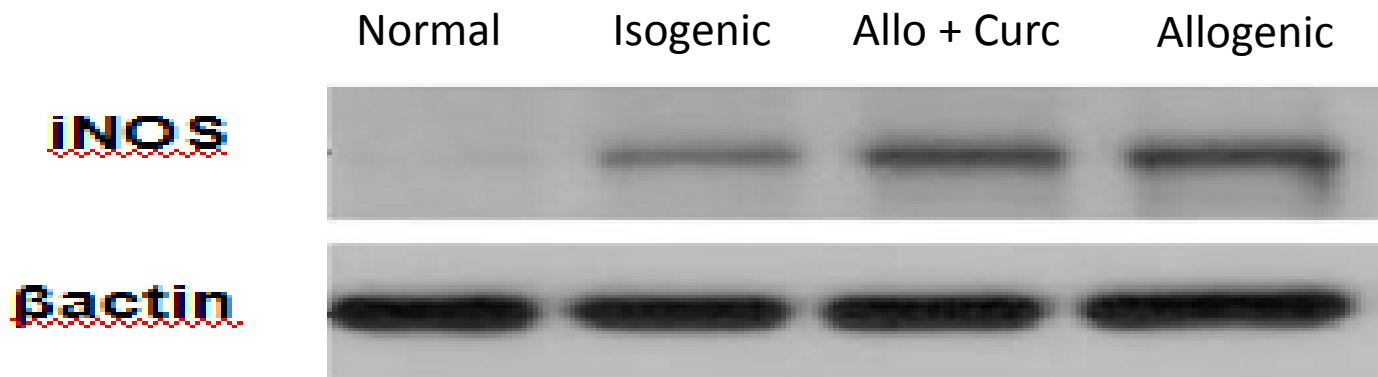
- 0: clear graft
- 1: minimal superficial opacity
- 2+: mild stromal opacity with pupil margin and iris vessels visible
- 3+: moderate stromal opacity with only pupil margin visible
- 4+: intense stromal opacity with the anterior chamber visible and
- 5+: maximal corneal opacity with total obscuration of the anterior chamber
- Grafts with an opacity score of 3+ or higher at 2 weeks that never cleared were regarded as rejected
- Grafts with an opacity score of 2+ or higher after 3 weeks were considered to be rejected

Detection of iNOS Protein by Western Blotting

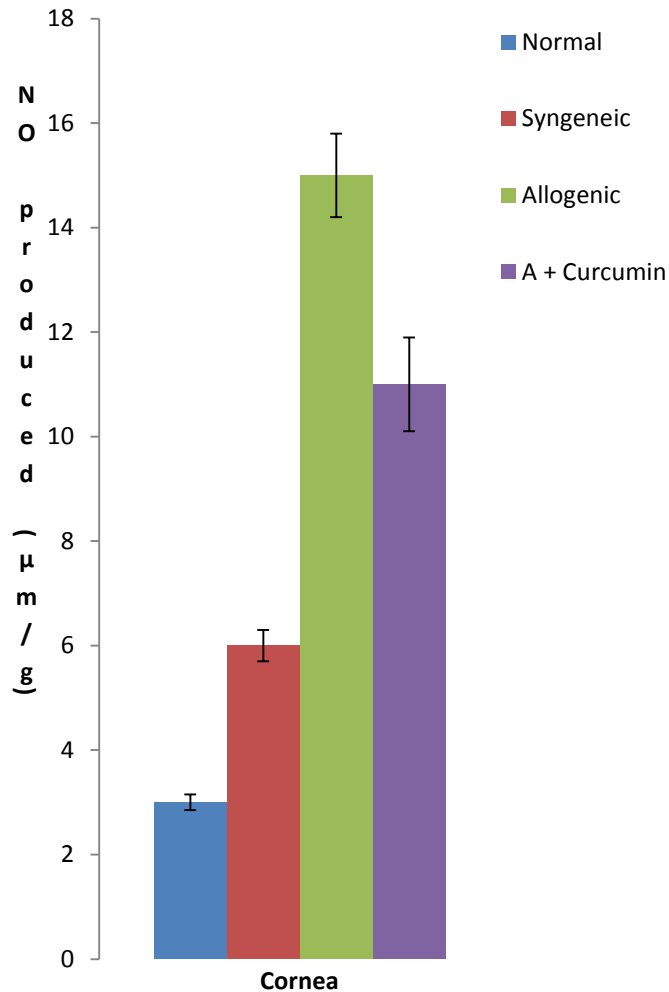
- Protein extracted by homogenization with protein extraction buffer (50 mM Tris-HCl (pH 7.4), 150 mM NaCl, 10 mM EDTA, 1% Triton X-100, 1% SDS, and 1% protease inhibitors) and
- Separated by 8% SDS-PAGE and transferred to PVDF membranes at 90 V for 2 hours on ice (Mini-PROTEAN tetra cell; Bio-rad Laboratories, Richmond, CA, USA)
- The membranes were blocked with 5% blocking buffer
- Dissolved nonfat dried milk in TBST as blocking buffer (1X TBST- **1X TBST** : 50 mM Tris.HCl, pH 7.4, 150 mM NaCl, 0.1% Tween 20)
- **Incubated with diluted anti-iNOS (1 : 1,000, milipore, Temecula, CA, USA)**
- **anti- β -tubulin (1 : 500,000, Abcam, Cambridge Science Park, UK)**
- in 5% blocking buffer for overnight with shaking

iNOS protein estimation

- After several washes with TBST, membranes were reacted with ECL and exposed to X-ray medical film (AGPA)
- Band density was analyzed by the scion image software



Nitric oxide production



Nitric oxide (NO) was measured using Biodiagnostic kits (Tarpey et al.)

In corneal homogenate

Initially, nitrate was converted into nitrite by the enzyme nitrate reductase

Followed by quantitation of nitrite using Griess reagent at 550 nm

NO was assayed by measuring total nitrate plus nitrite ($\text{NO}_3^- + \text{NO}_2^-$), the stable end products of NO metabolism

NO concentration was expressed as $\mu\text{mol/g}$ tissue

NO/iNOS

- iNOS gene is under the transcriptional control of variety of inflammatory cytokines
- Increase in iNOS activity reported in other transplants
 - eg myocardial allografts
 - led to rejection
- Activates guanylyl cyclase
- NO reacts with SO radicals forming peroxynitrite
- Role of iNOS in transplant rejection not yet defined
 - Rats- cytotoxic
 - Human –low/medium expression found beneficial
- Further studies are needed

Gene expression studies

- A few cytokines and other genes found upregulated after transplantatin
- Expression of mRNA in corneal tissue
- Real time PCR of
 - IL1 β , IL6, IL10
 - RANTES
 - TN α
 - iNOS
 - Tgf β 1

Reverse Transcription

- 5µg of extracted RNA was subjected to RT using
- Random primers (Invitrogen, Life Technologies, UK) and
- Moloney murine leukemia virus (M-MLV) reverse transcriptase (Invitrogen, UK)
- The protocol provided by the enzyme manufacturer was strictly followed

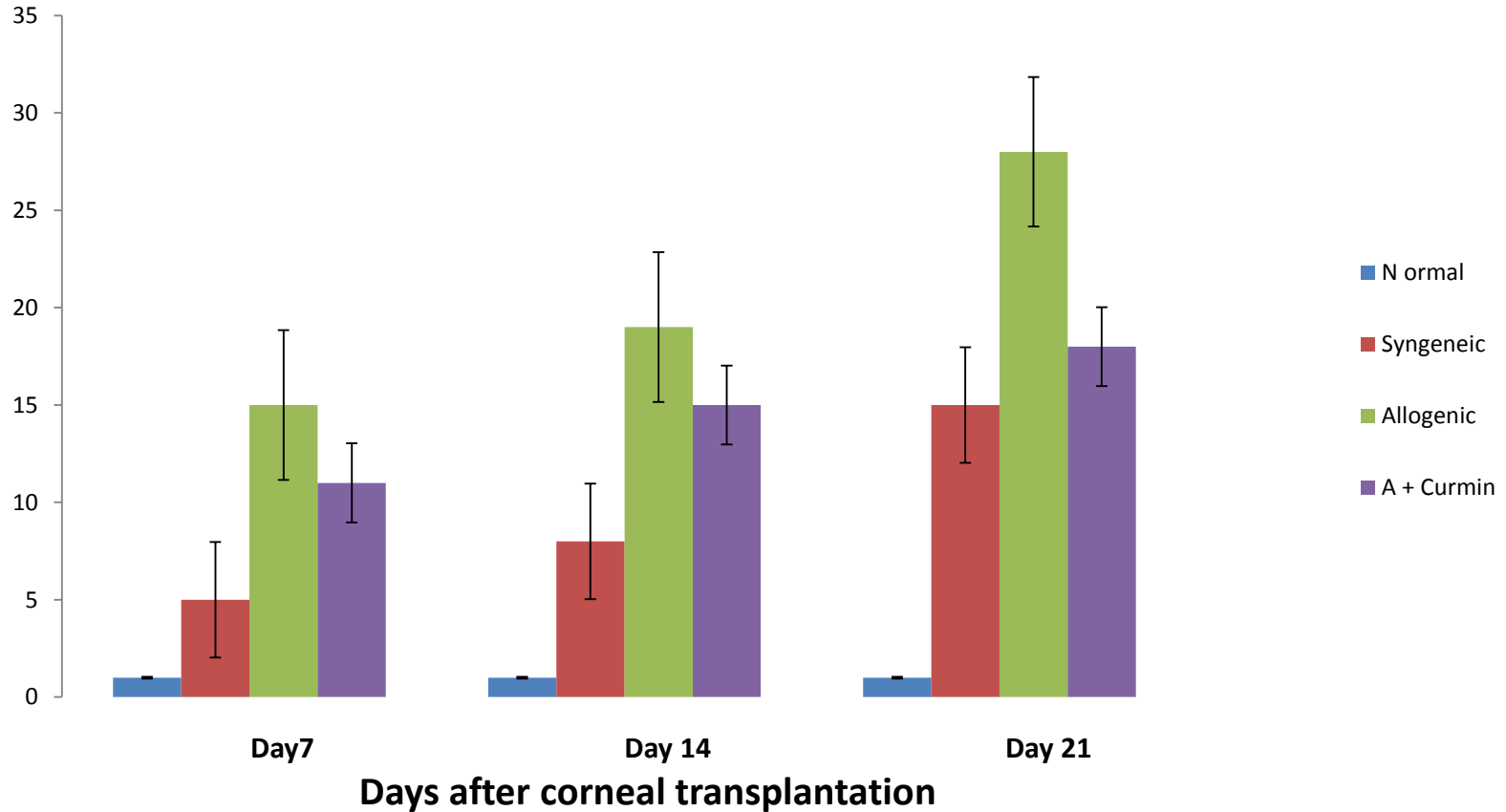
PCR conditions

- Amplification conditions for each primer set consisted of;
 - 03 min initial denaturation at 95°C
 - followed by 35 repeats of
 - 45 s at 95°C
 - 30 s at 60°C and
 - 60 s at 72°C
 - Followed by a final extension at 72°C for 120 s

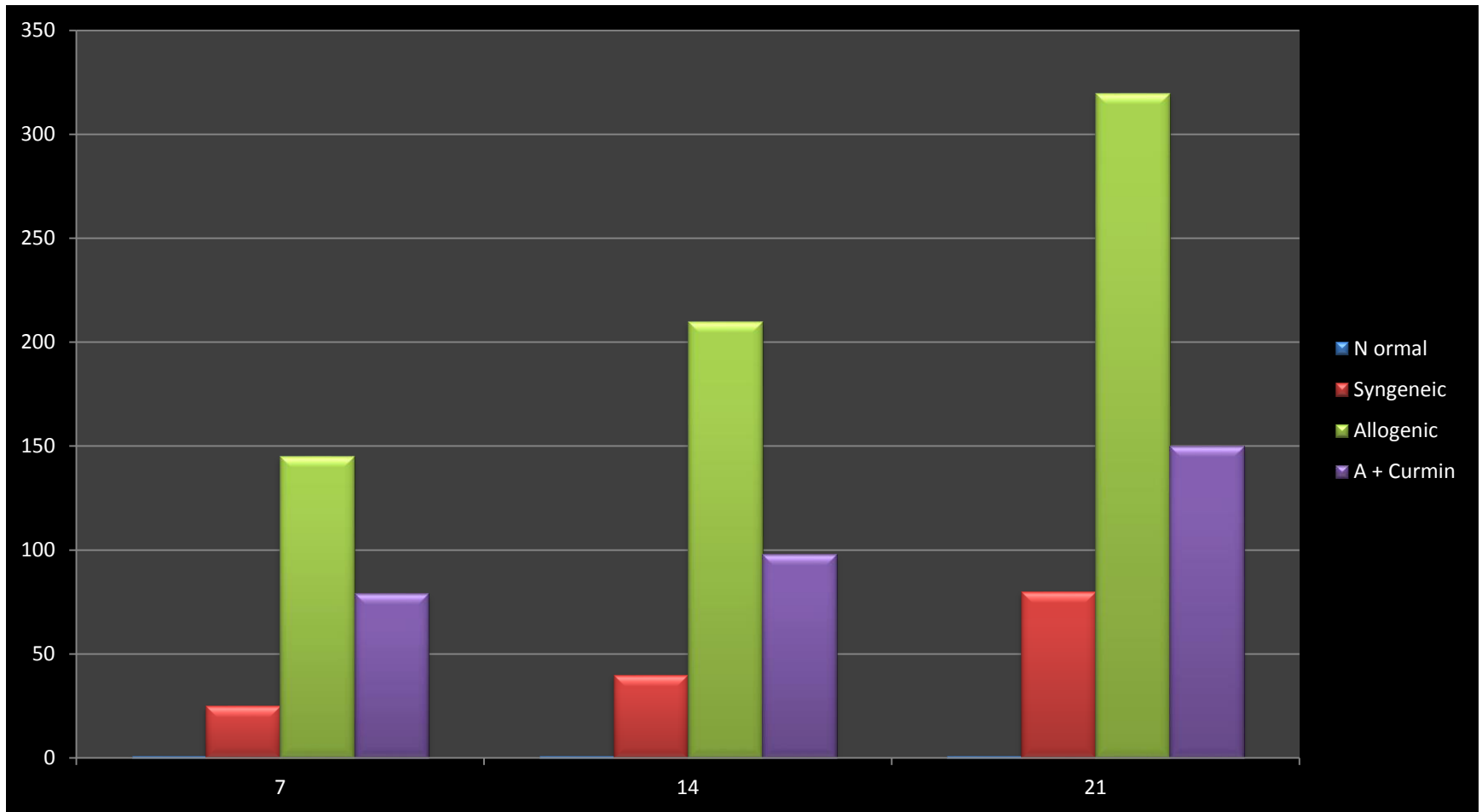
Primers used for estimation of gene expression

Genes	Forward Primer (5'-3')	Reverse Primer (5'-3')
IL1 β	CCAGGATGAGGACCCAAGCA	TCCCGACCATTGCTGTTTCC
IL6	ACTGGTCTGTTGTGGGTGGT	AGTTGCCTTCTTGGGACTGA
IL10	ATTTTGGAGAGAGGTACAAACGAG	TAGTGCTCAGAGATTCCTTACTGC
TN α	GGTTCCGTCCCTCTCATACA	AGACACCGCCTGGAGTTCT
iNOS	AATCCTACCAAGGTGACCTGAA	TGGCCAGATGTTCTCTATTTT
RANTES	GCCCACGTGAAGGAGTATTTTT	AGAGCAAGCAATGACAGGAAAG
Tgf β 1	GCAACAACGCAATCTATGACA	GAAAGCCCTGTATTCCGTCTC

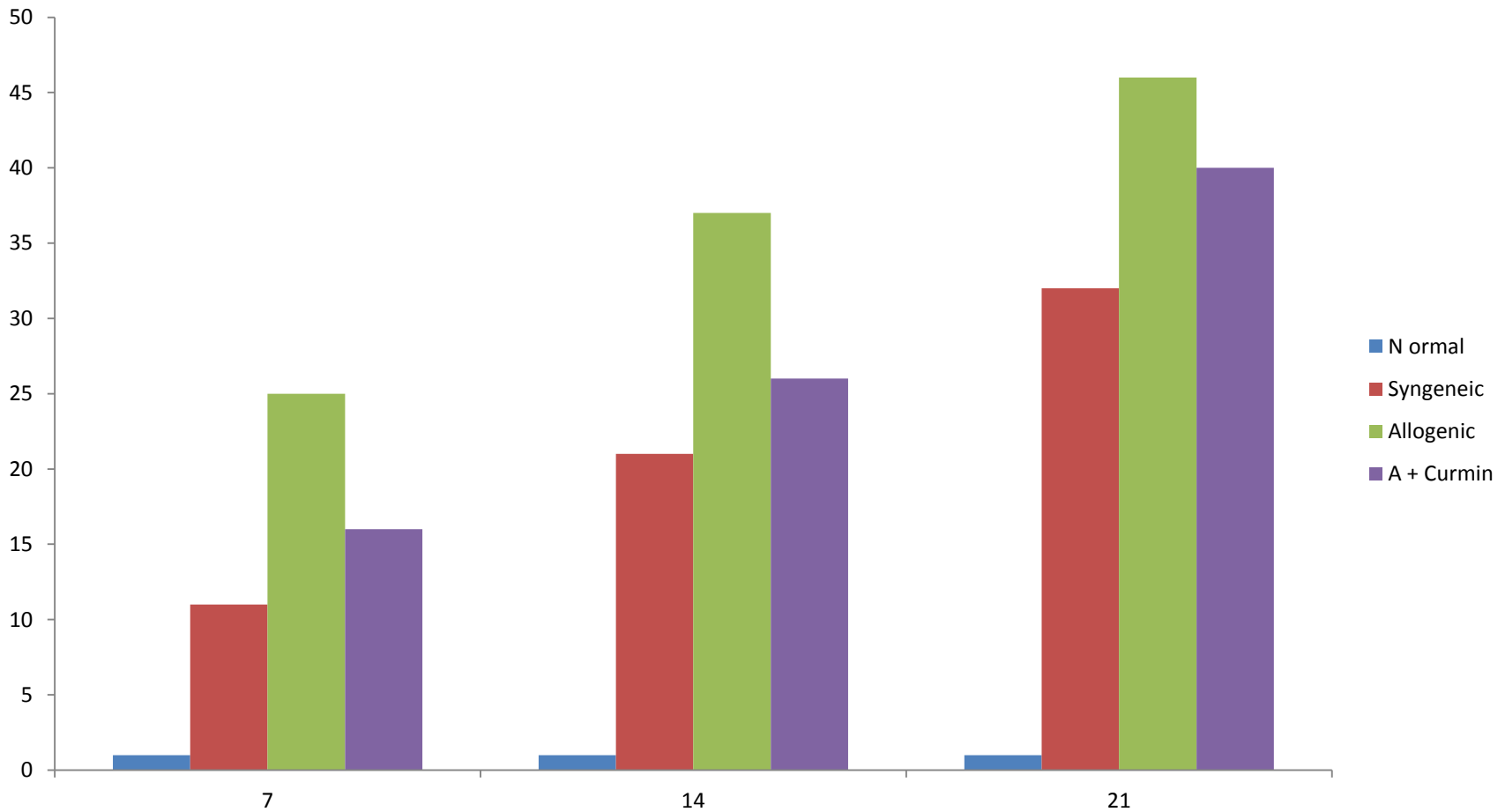
Cytokine levels in cornea –IL 1 β



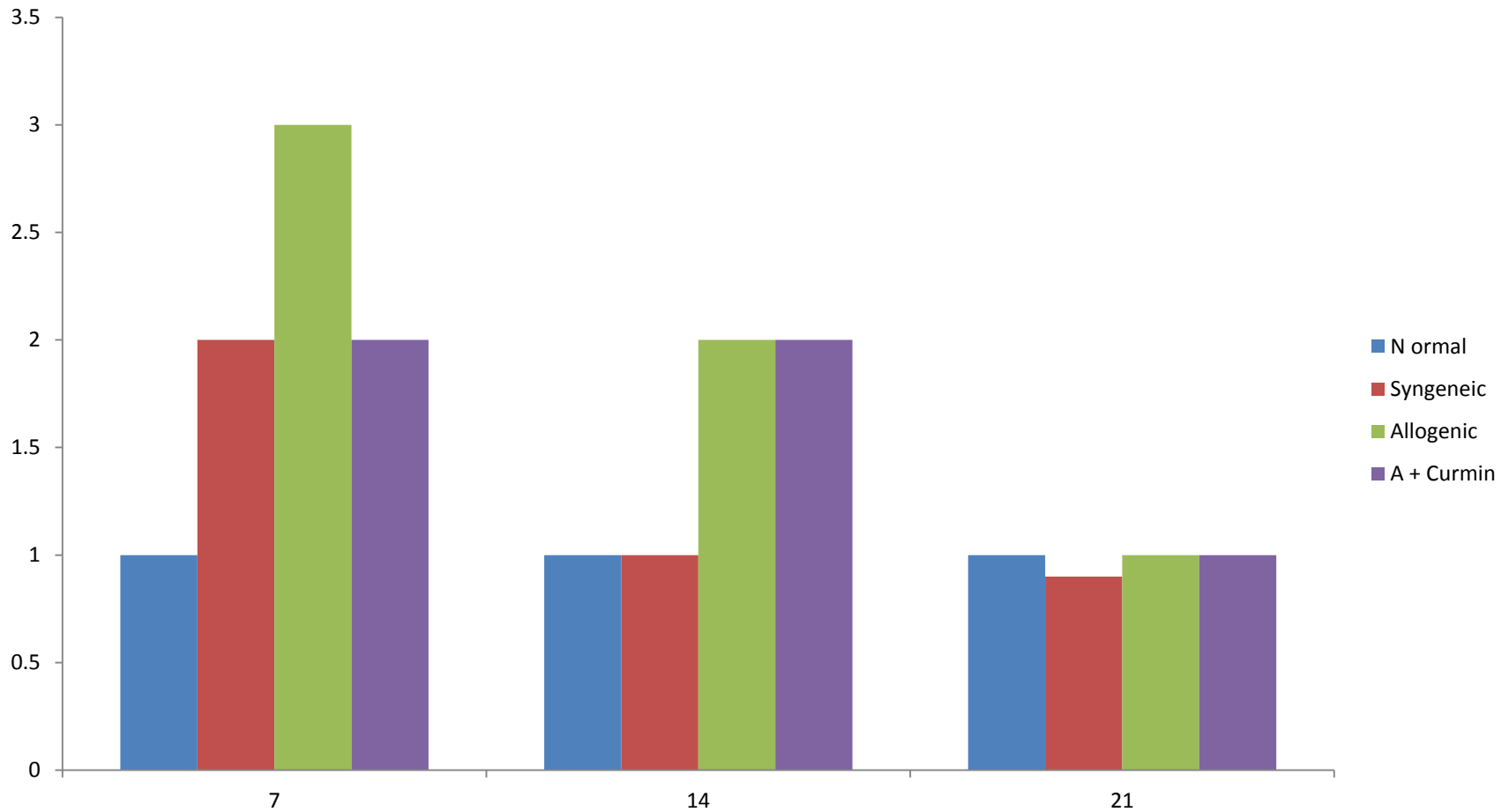
Cytokine levels in cornea –IL6



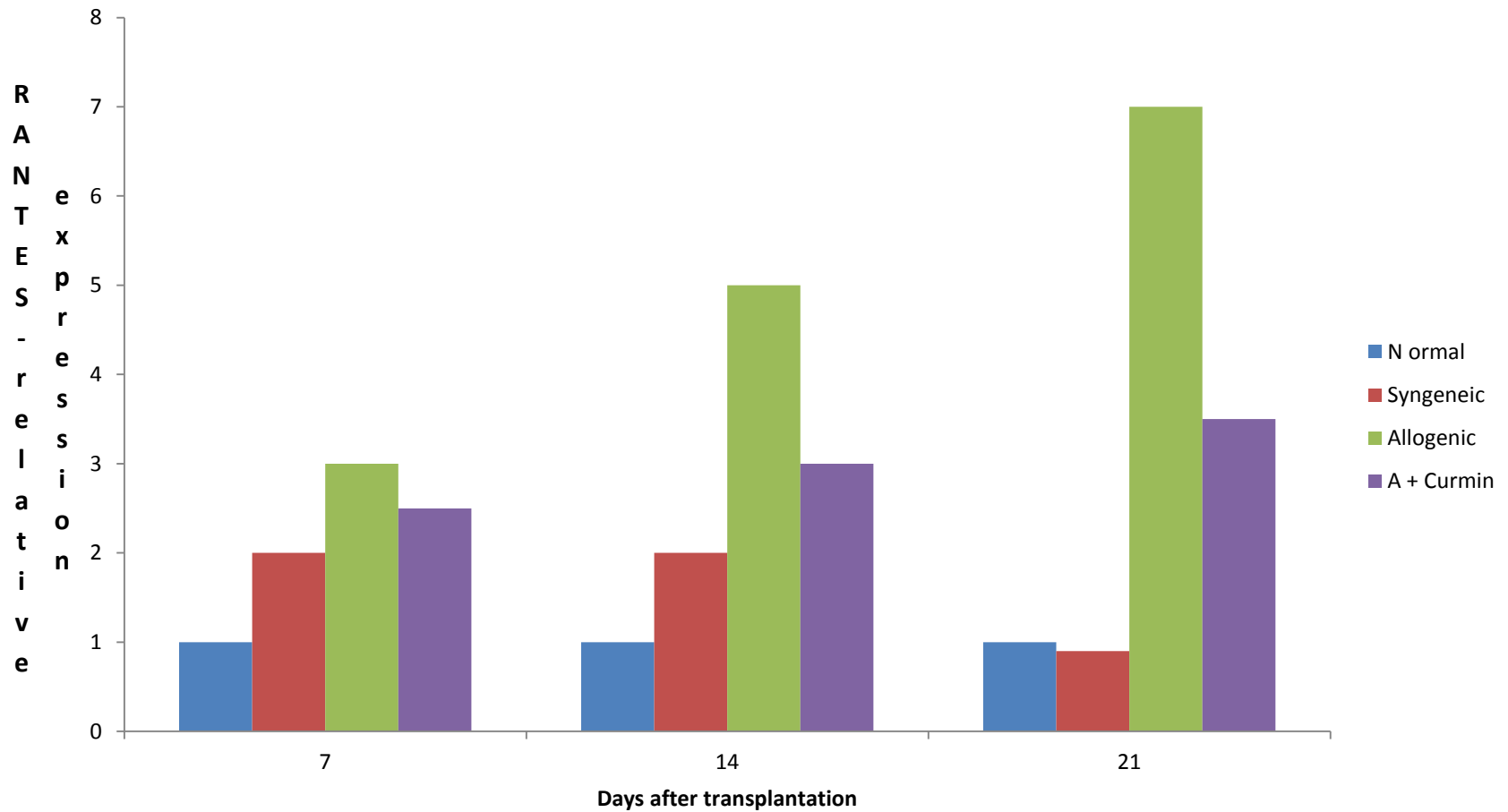
Cytokine levels in cornea –TNF α



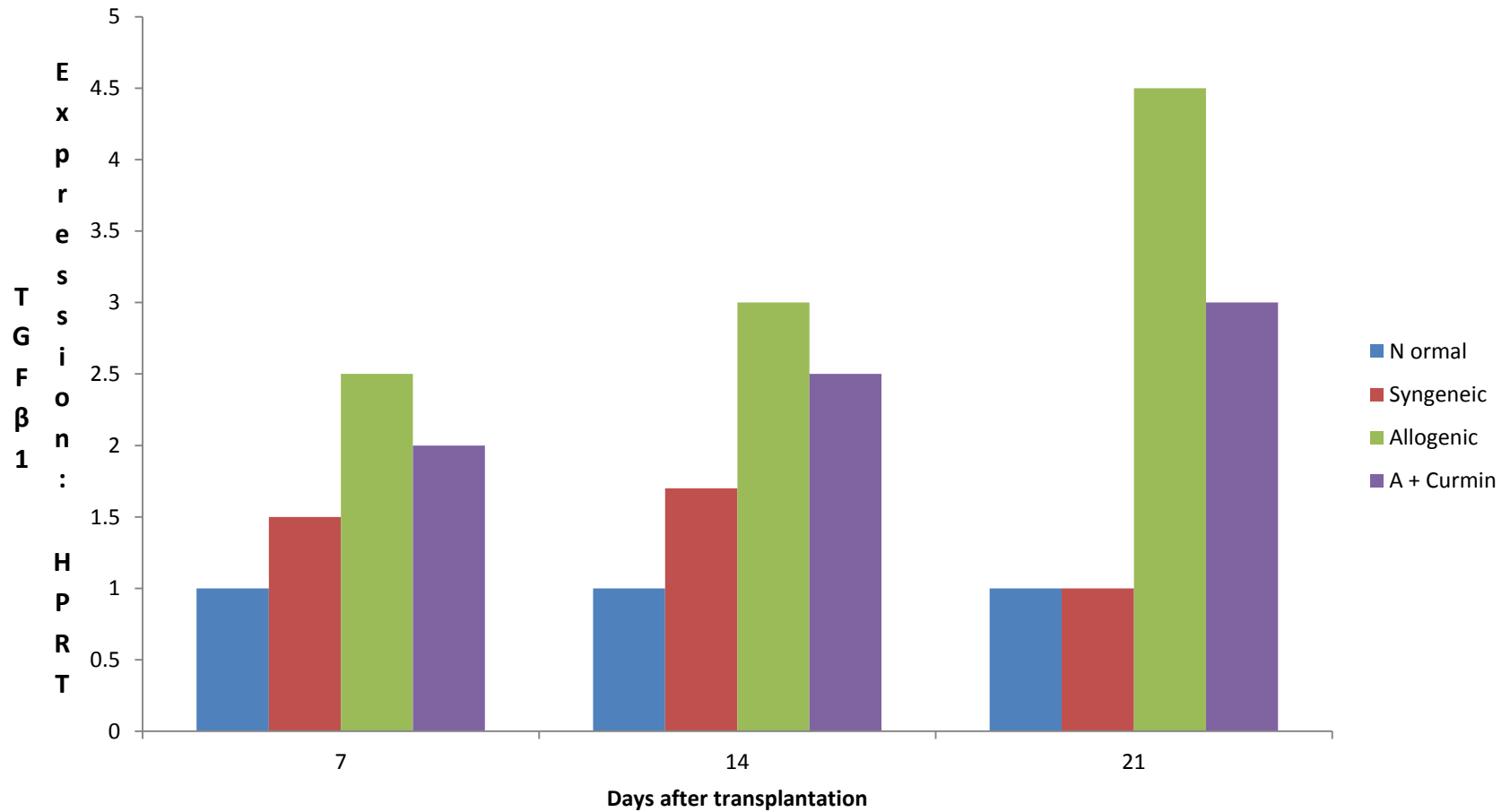
Cytokine levels in cornea –IL10



RANTES relative expression



TGF β 1 expression normalised to HPRT



Survival of various types of transplants

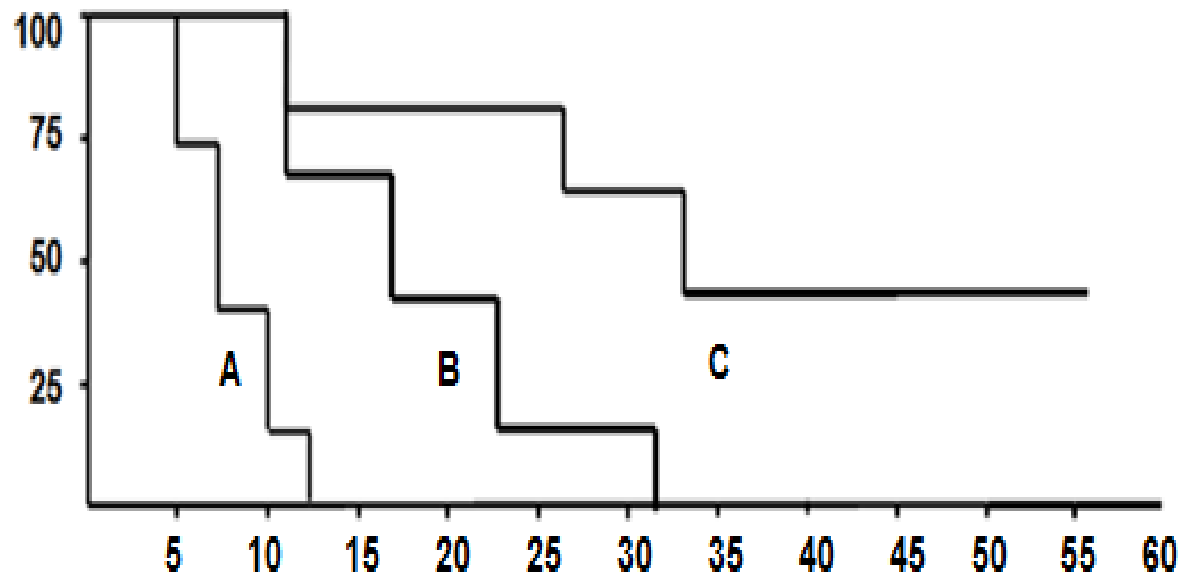


Fig Kaplan Meier Survival Curve showing the survival rate of corneal transplants in mice. A: allograft, B: syngeneic graft and C: allograft with curcumin treatment

Discussion

- Expression of iNOS and chemokines were nominal in normal cornea
- Transplantation increased expression of all
- Allogenic transplants showed highest increase
- Curcumin administration reduced expression
- Survival curve shows the influence of change in expression
- Curcumin offer a potential alternative to anti-inflammatory drugs in transplantation

Major drawbacks of curcumin

- **Poor absorption**
- **Rapid metabolism**
- **Short biological half life**
- **High doses needed to produce medicinal effect**
- **Strategies under consideration**
 - **Use of nanotechnology**
 - **Modification of the curcumin compound**
 - **Use of bioenhancers-piperine**