

Reversing Aging and Stem Cell

Dr. Ibrahim El Achkar

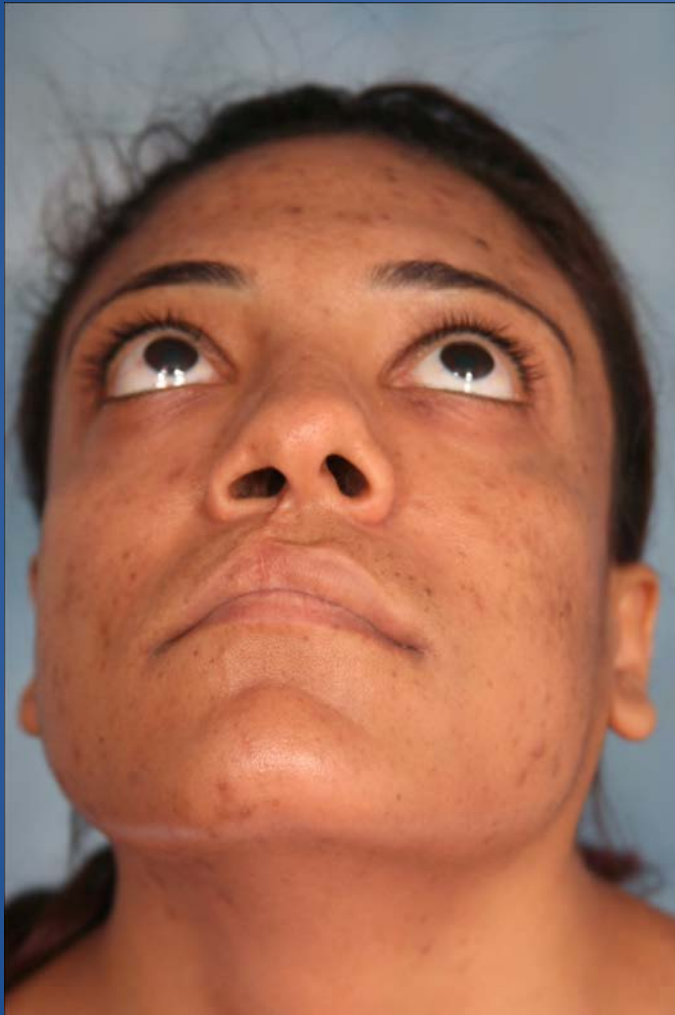St. Elie Center – Antelias - Lebanon

Tel: 009613246625 – ibachkar@hotmail.com

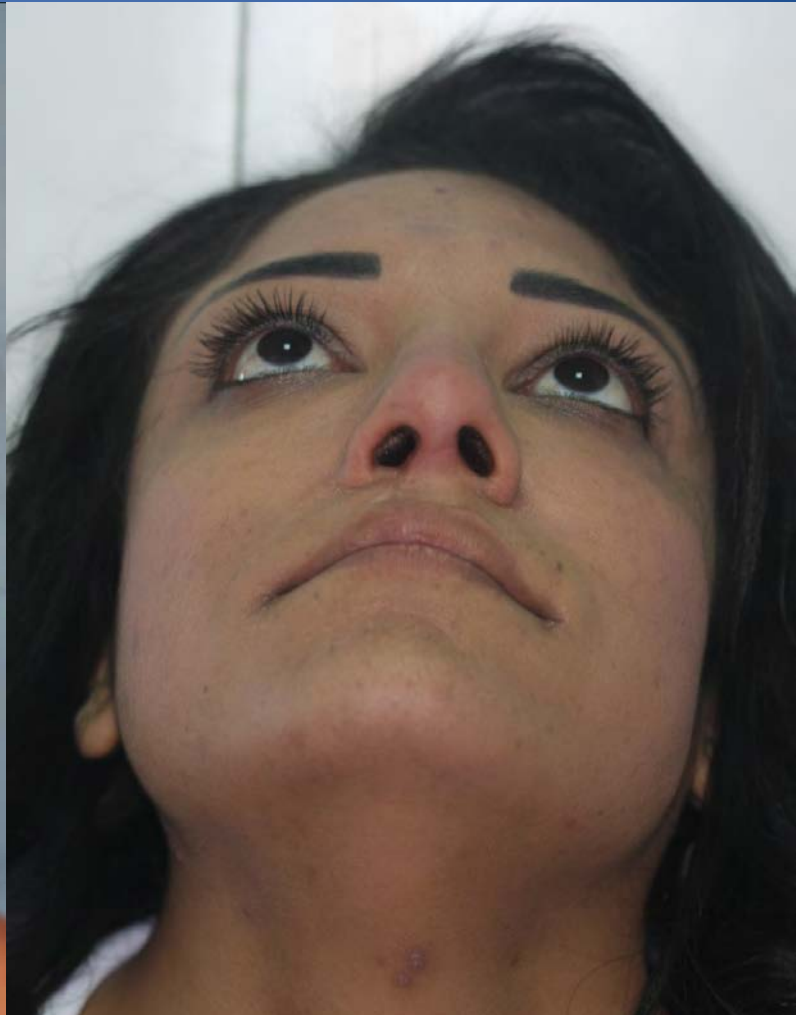**21st to 24th June
Cosmetology 2015
Philadelphia USA**

Dr. Ibrahim EL ACHKAR

Before



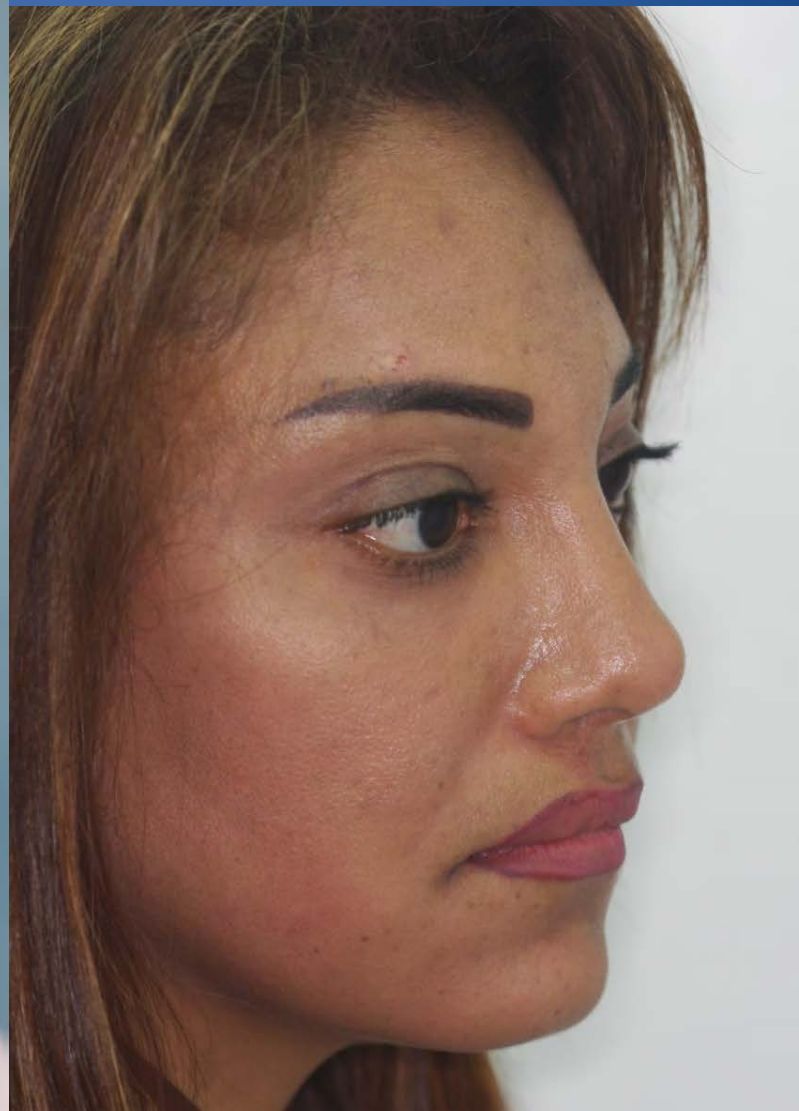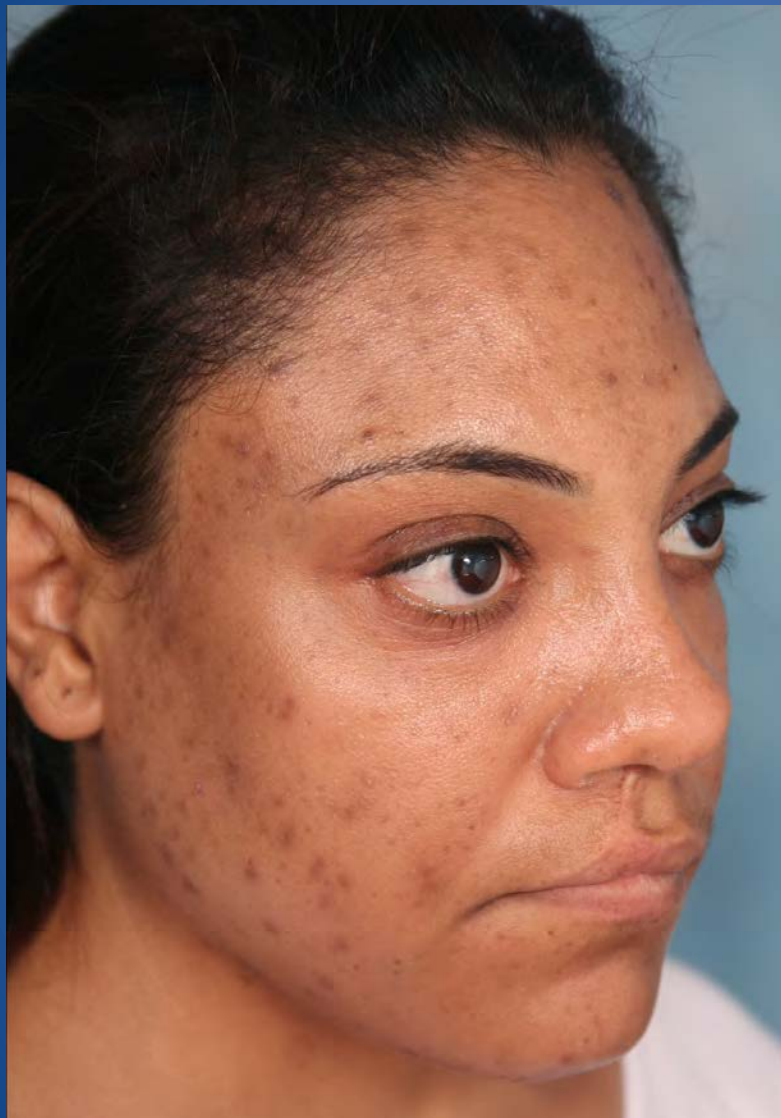After



Dr. Ibrahim EL ACHKAR

Before

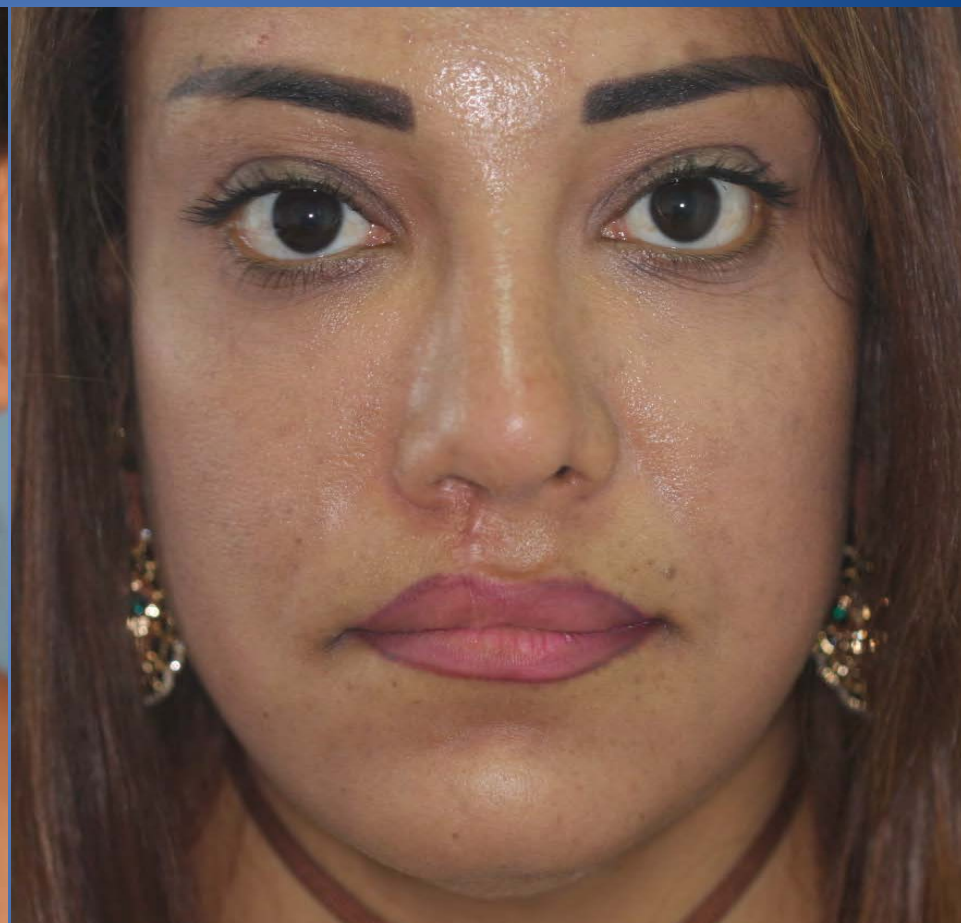
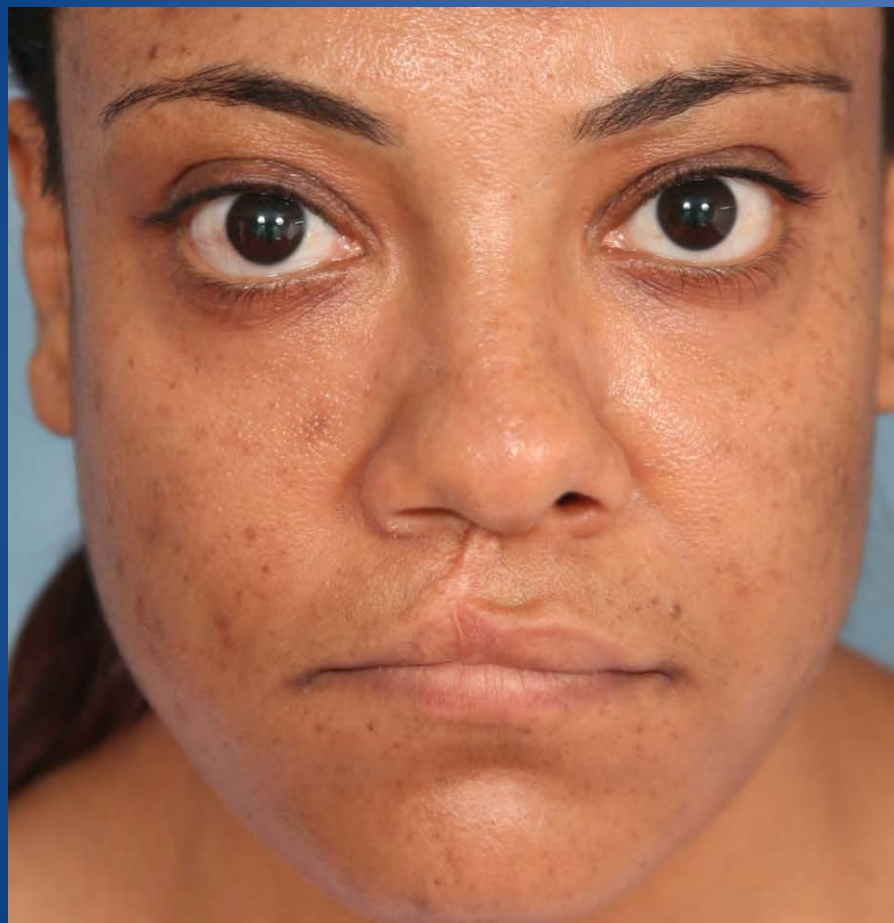After



Dr. Ibrahim EL ACHKAR

Before

After



Dr. Ibrahim EL ACHKAR

Lower face:

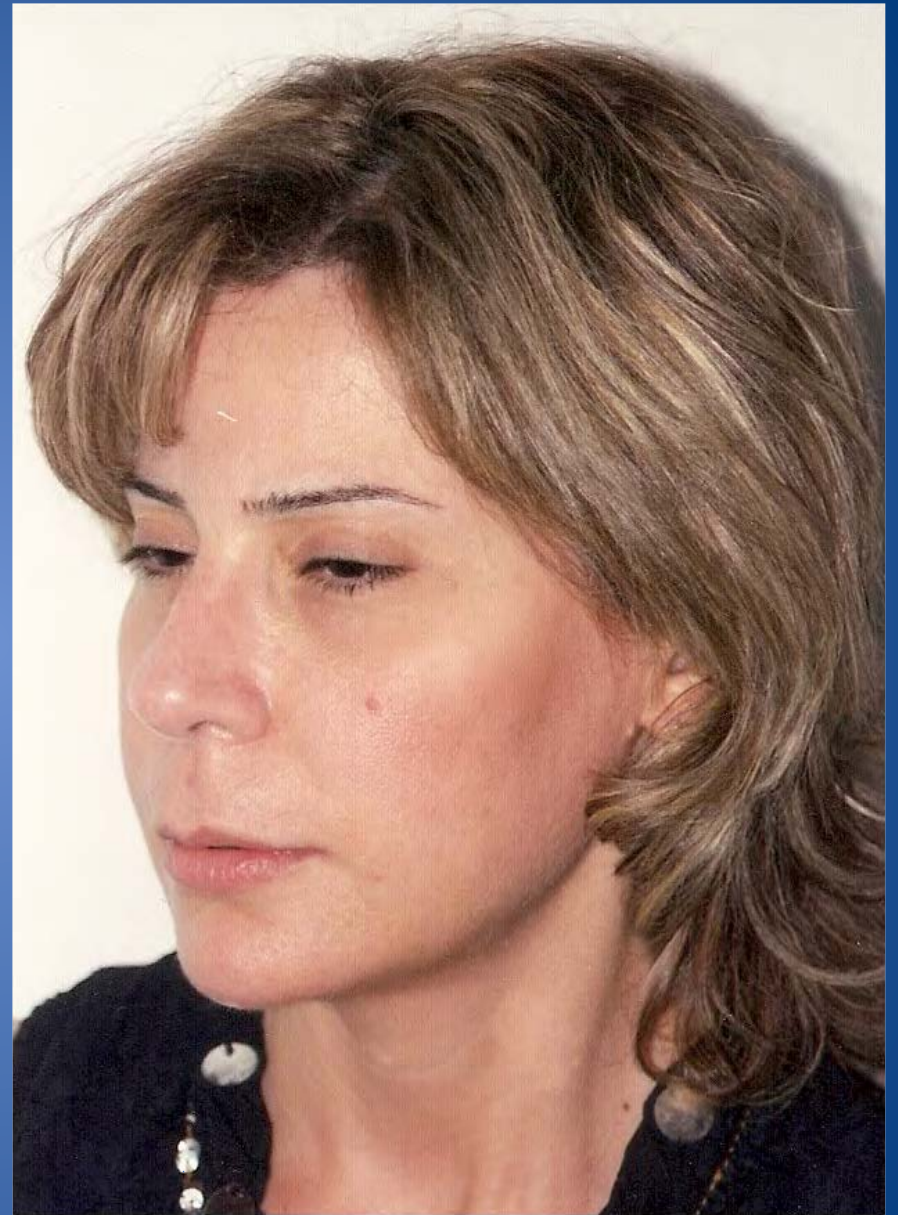
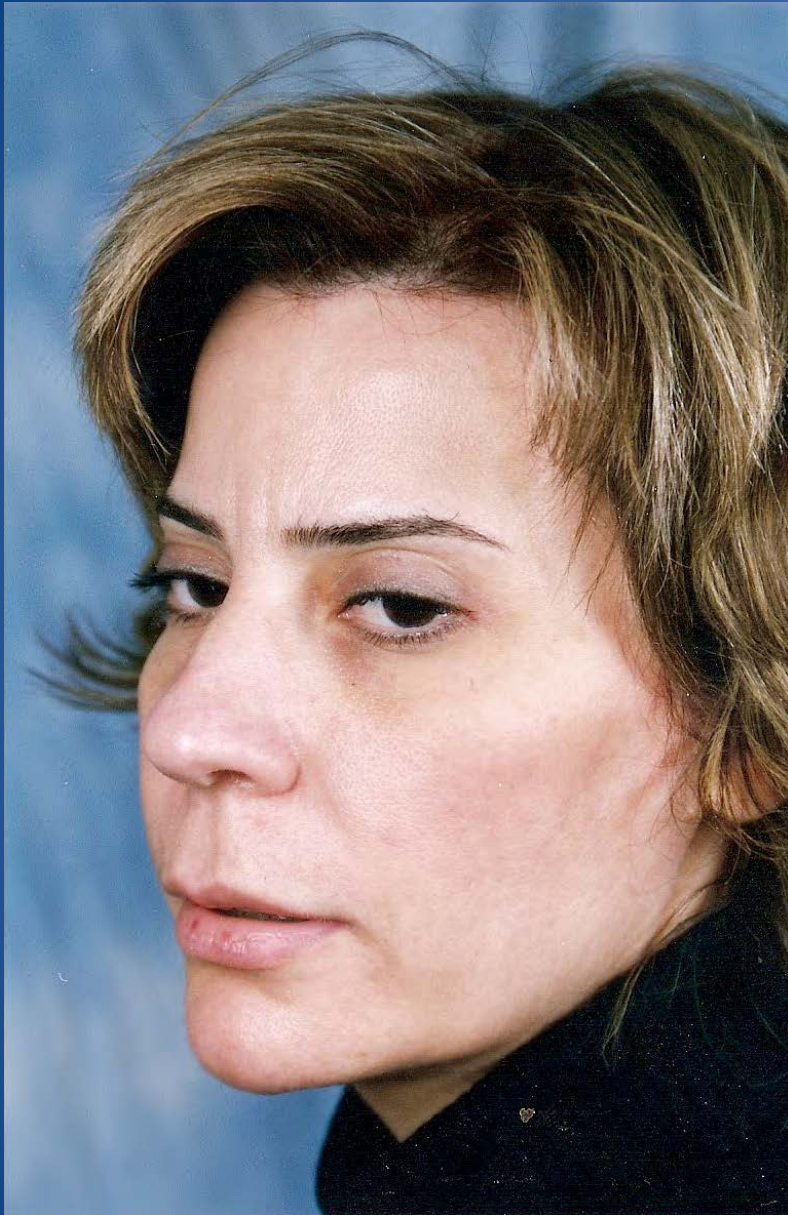- ✓ Lips
- ✓ Labial comissur
- ✓ Chin

Before

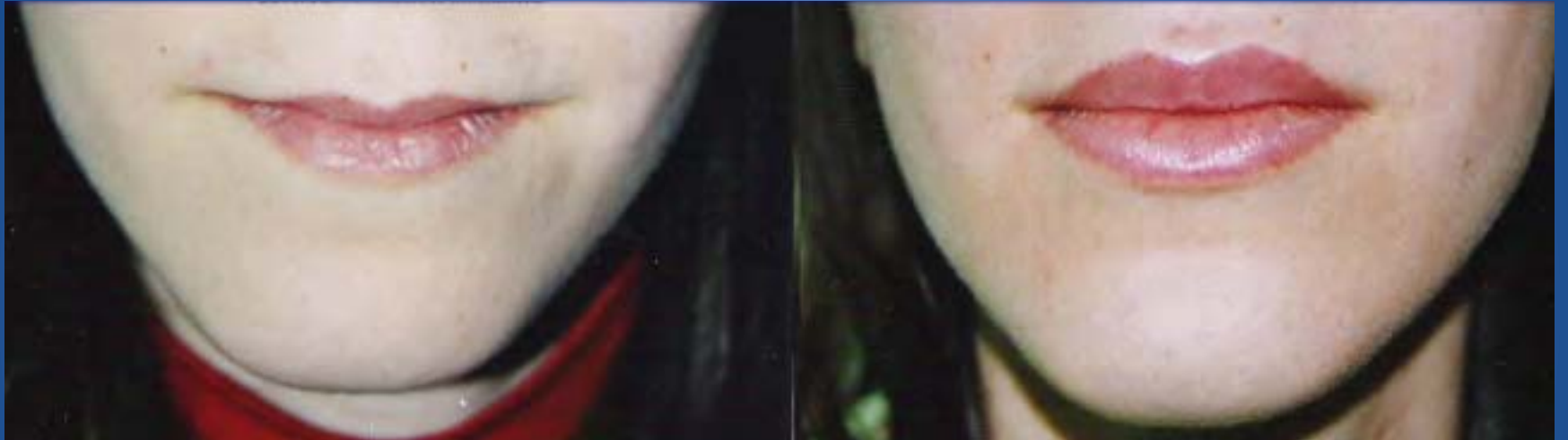After



Dr. Ibrahim EL ACHKAR



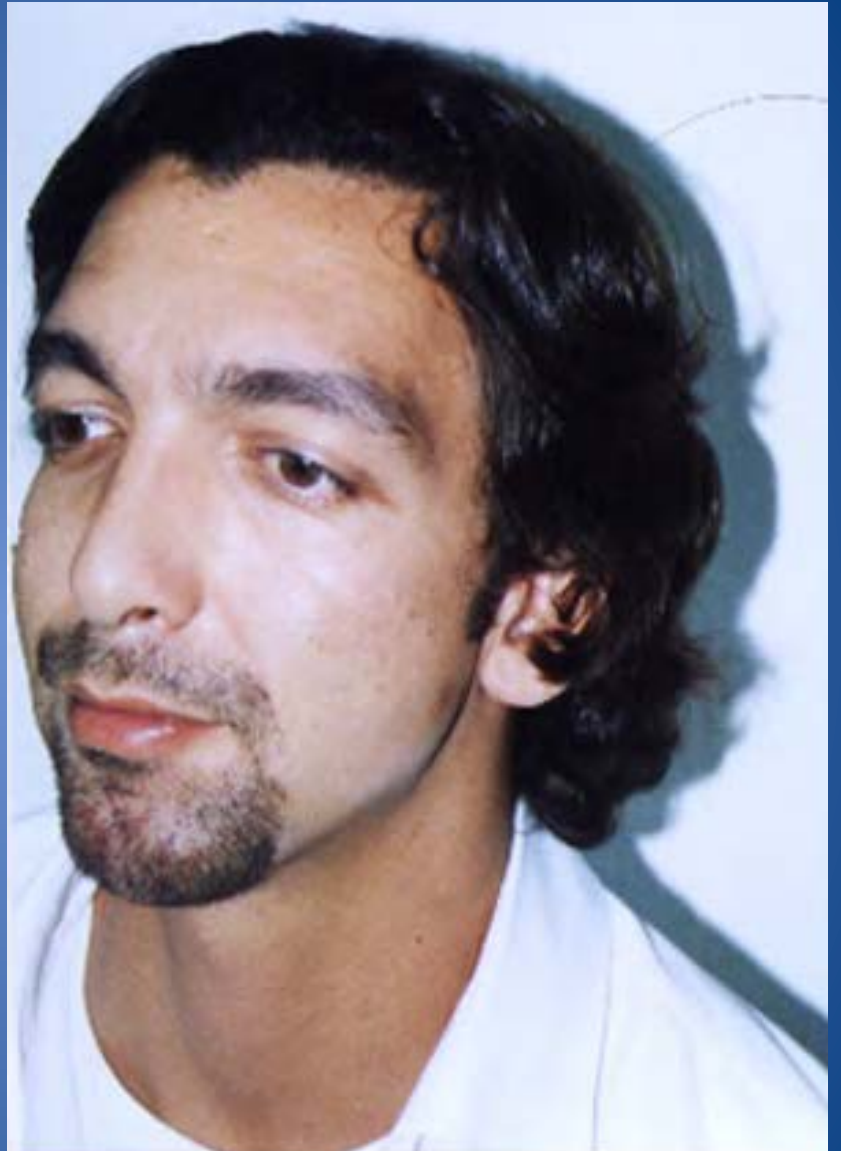Dr. Ibrahim EL ACHKAR



Dr. Ibrahim EL ACHKAR

Before

After



Dr. Ibrahim EL ACHKAR

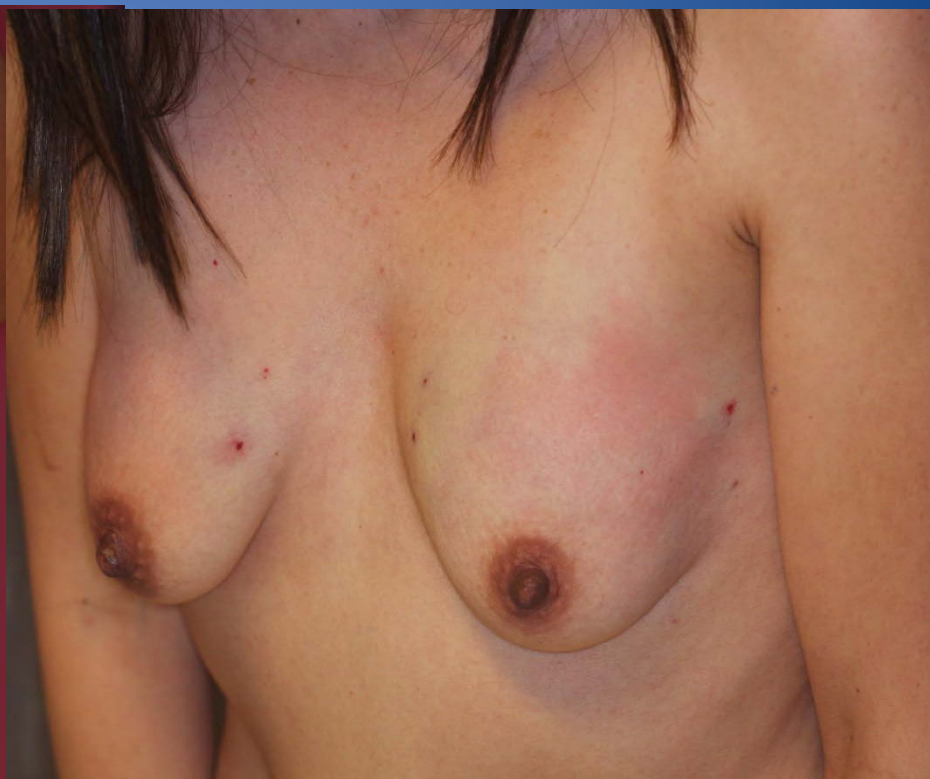Body:

- ✓ Upper limbs
- ✓ Breasts
- ✓ Buttocks
- ✓ Lower limbs

Before



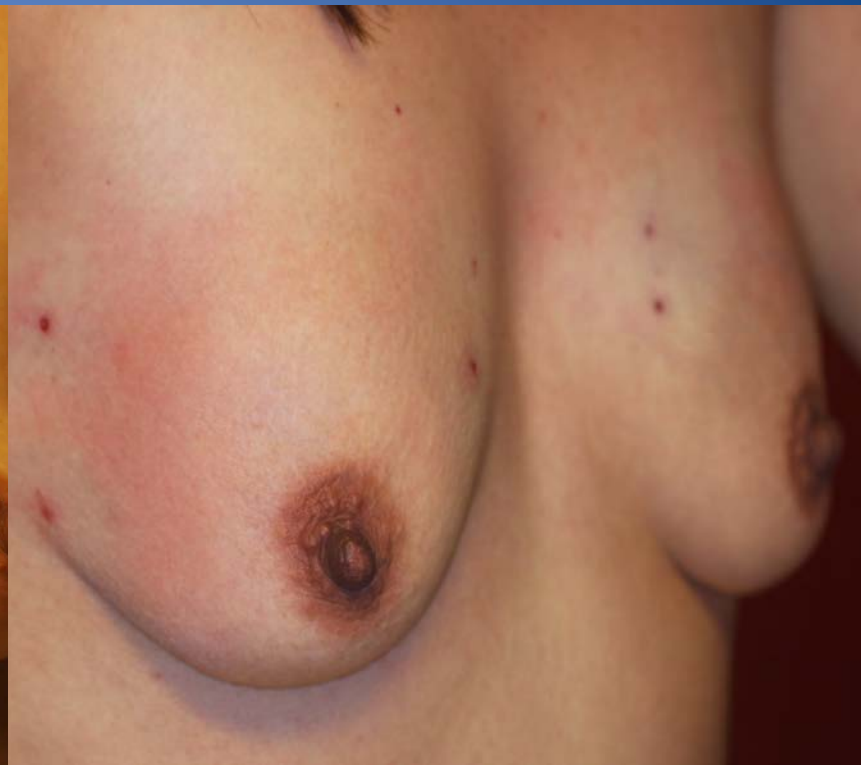
After



Dr. Ibrahim EL ACHKAR

Before

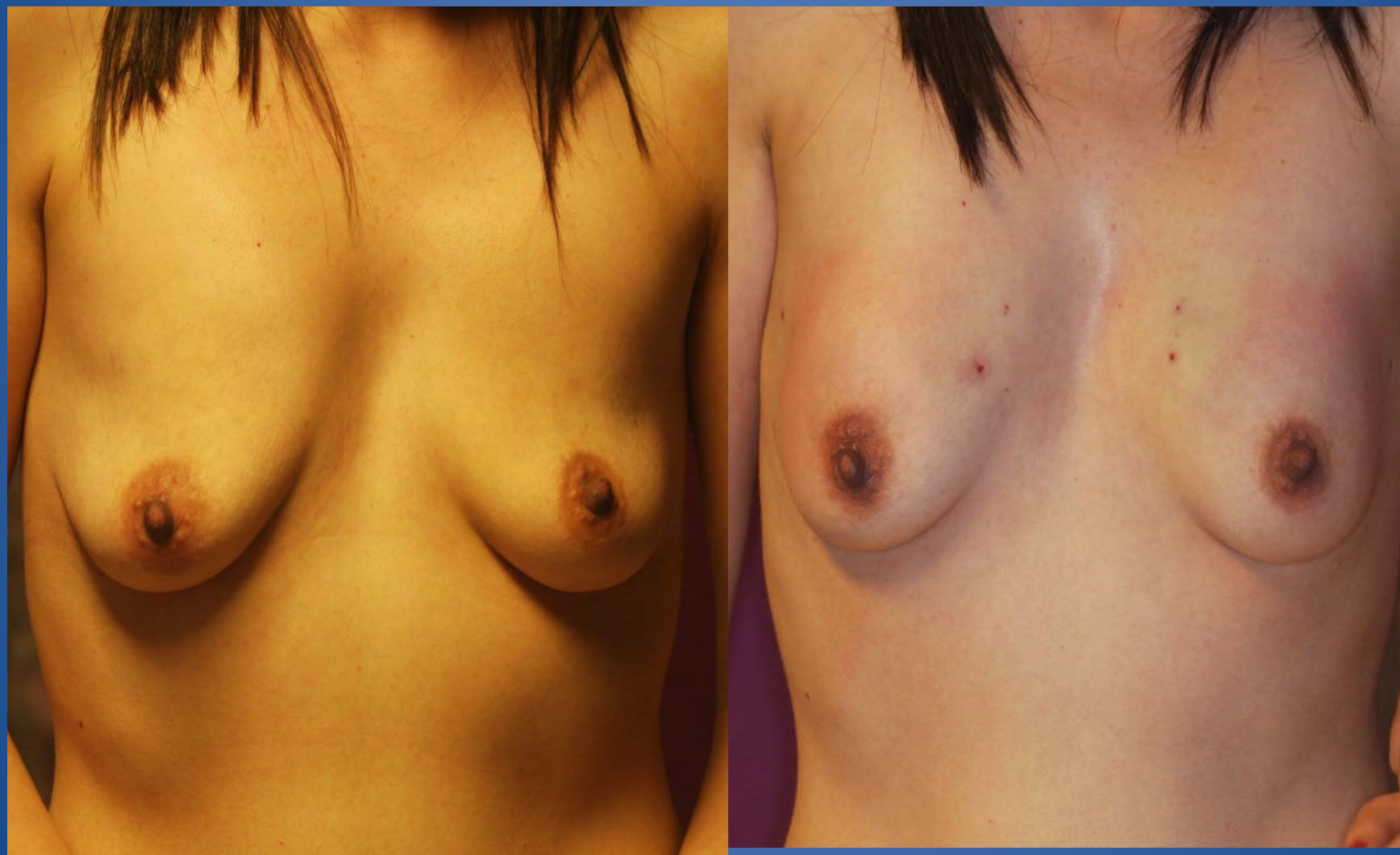After



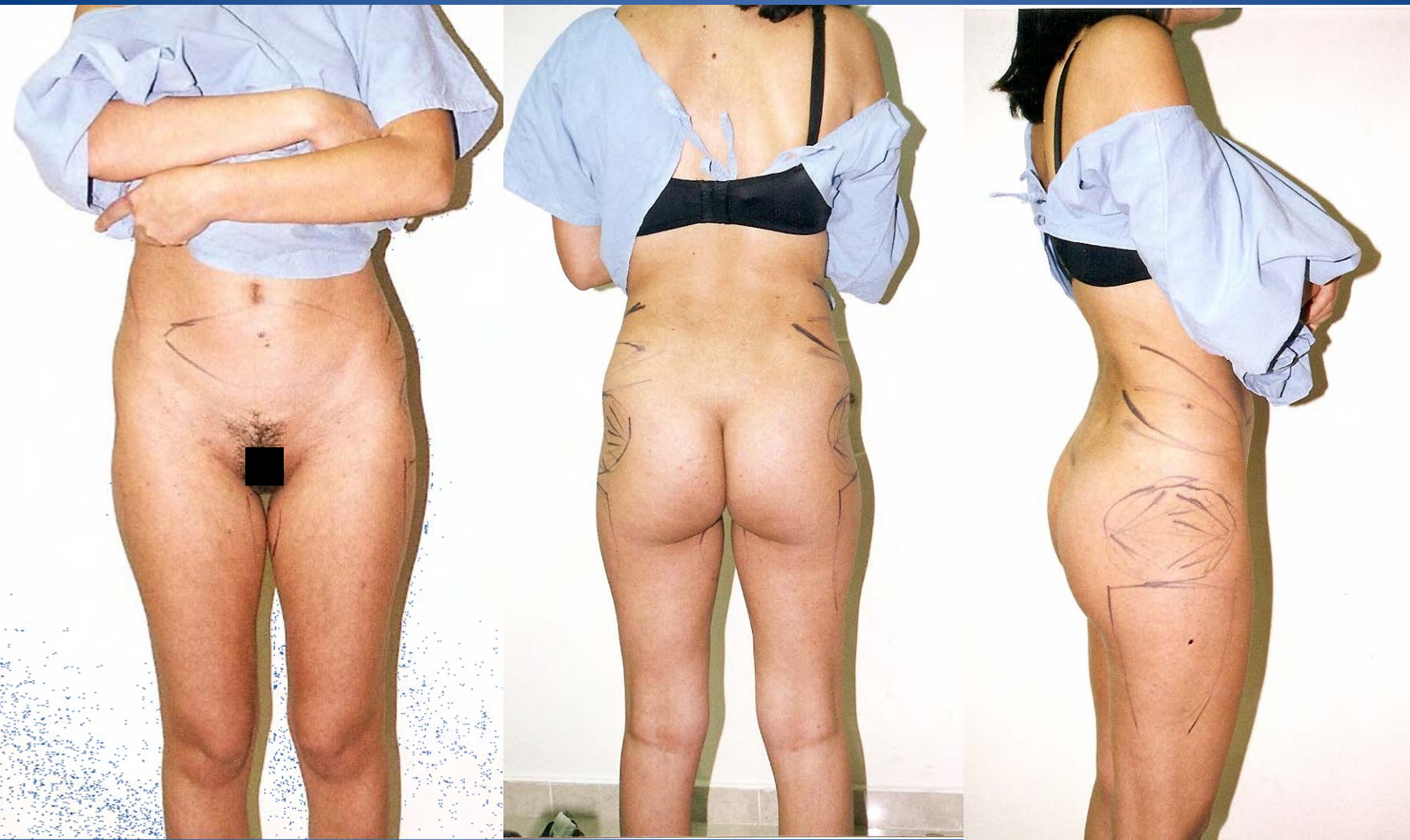Dr. Ibrahim EL ACHKAR

Before

After

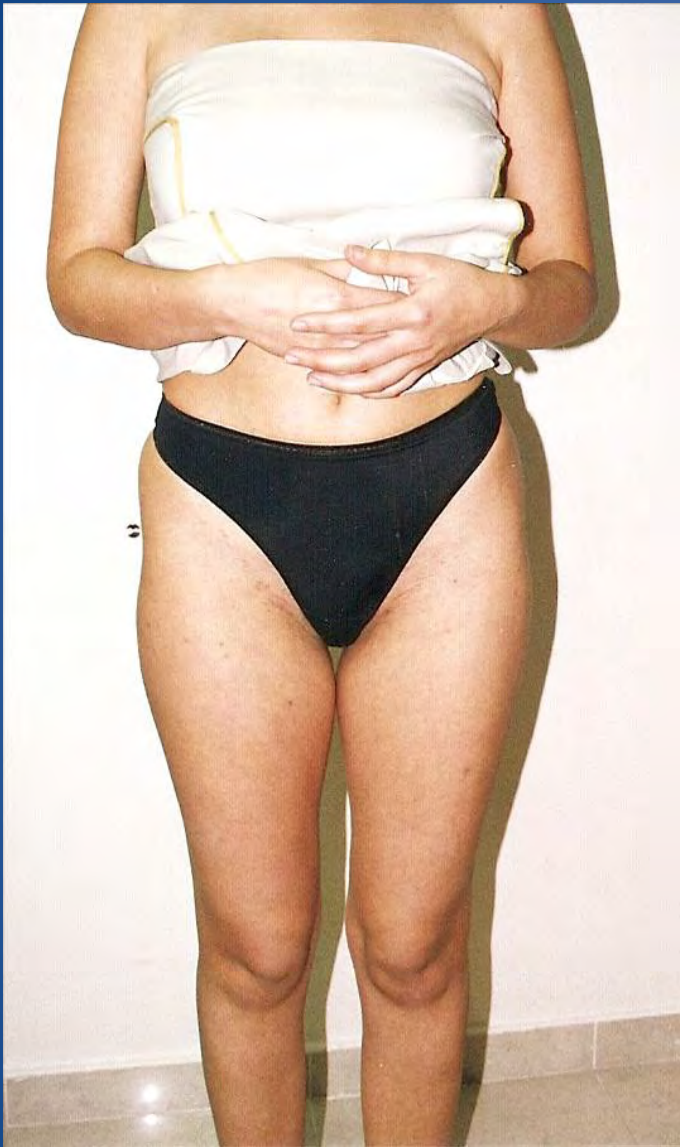

Dr. Ibrahim EL ACHKAR

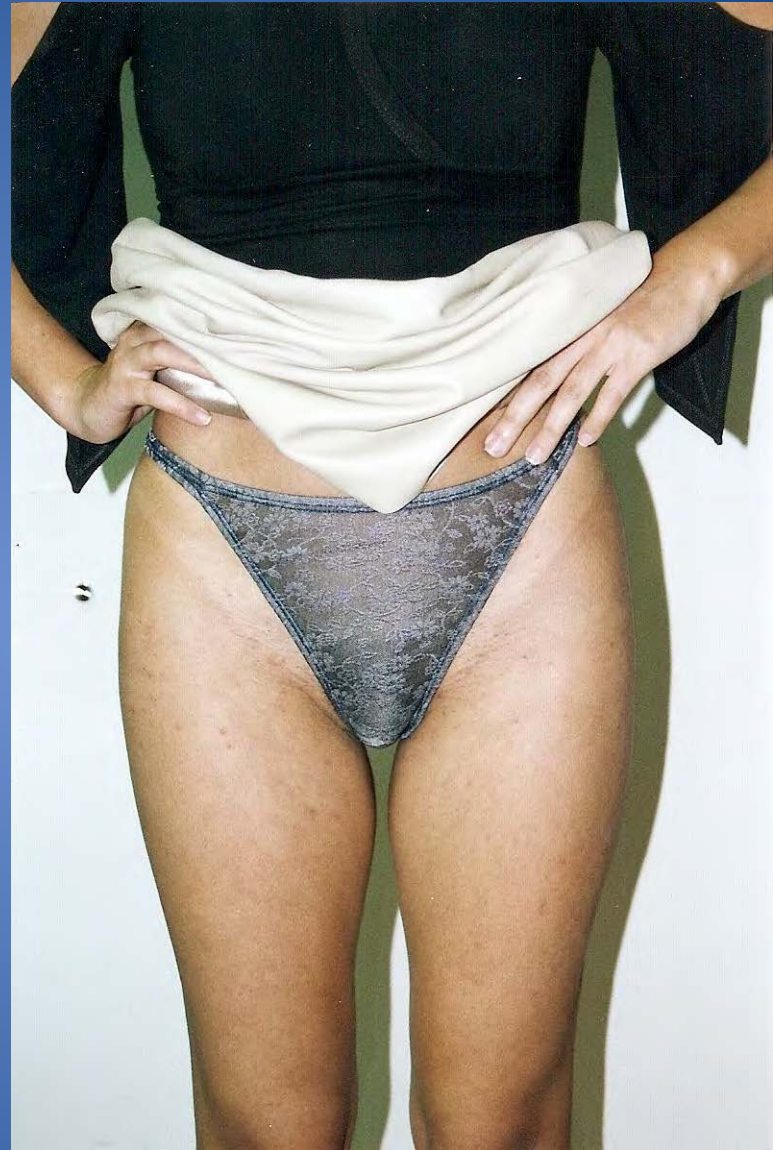

Dr. Ibrahim EL ACHKAR

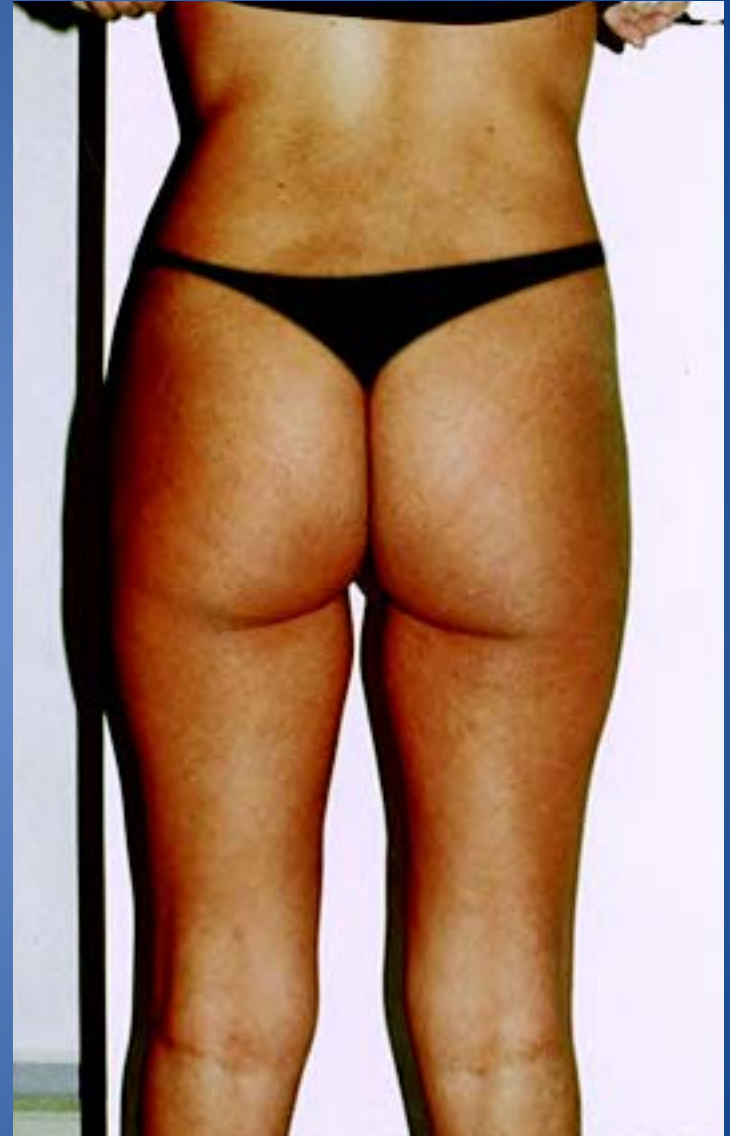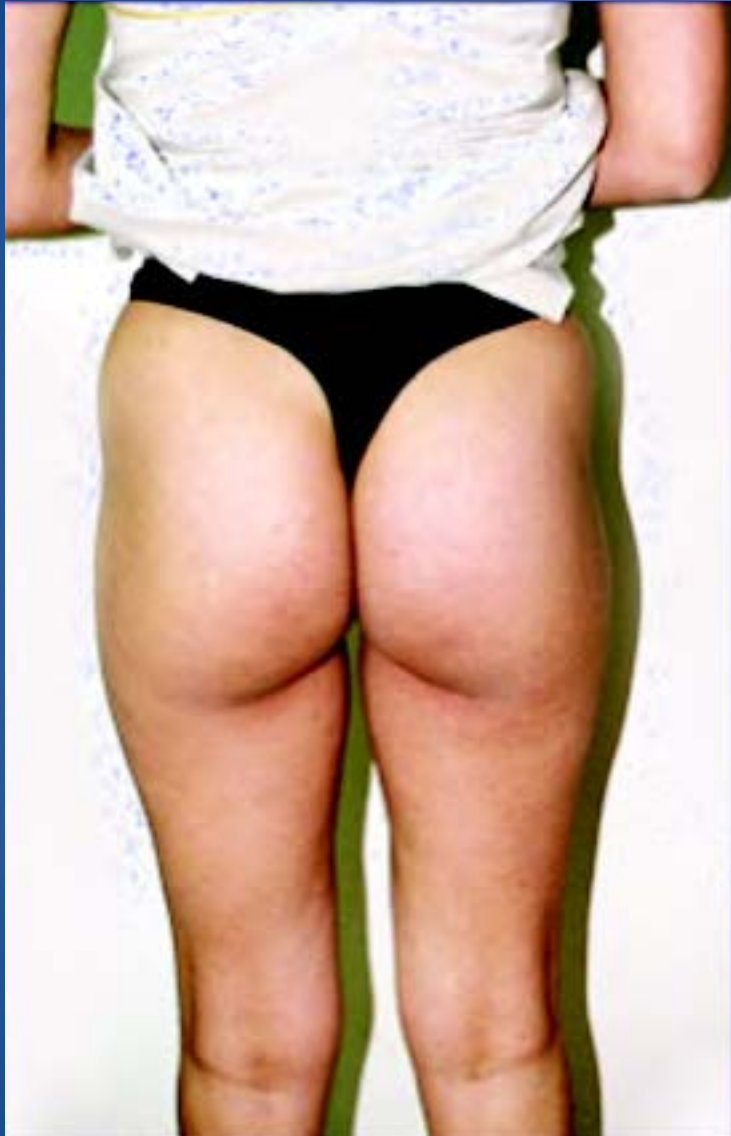Before



After



Dr. Ibrahim EL ACHKAR

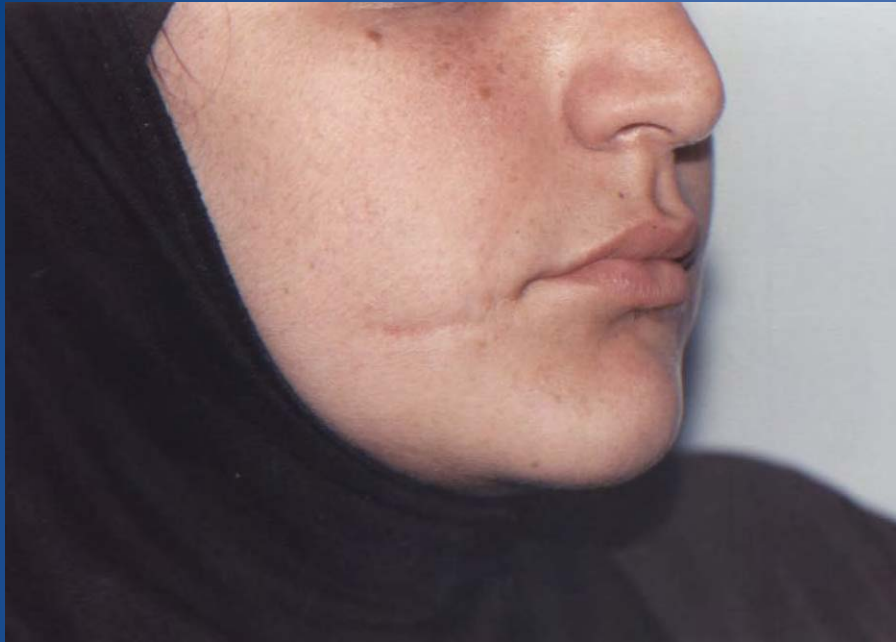

Dr. Ibrahim EL ACHKAR

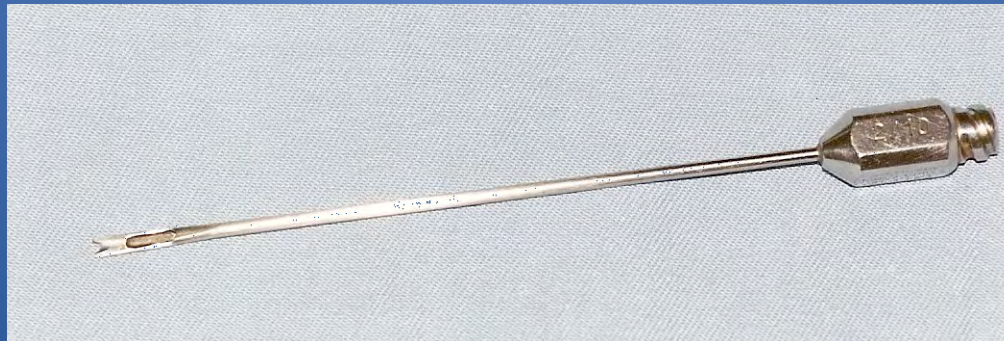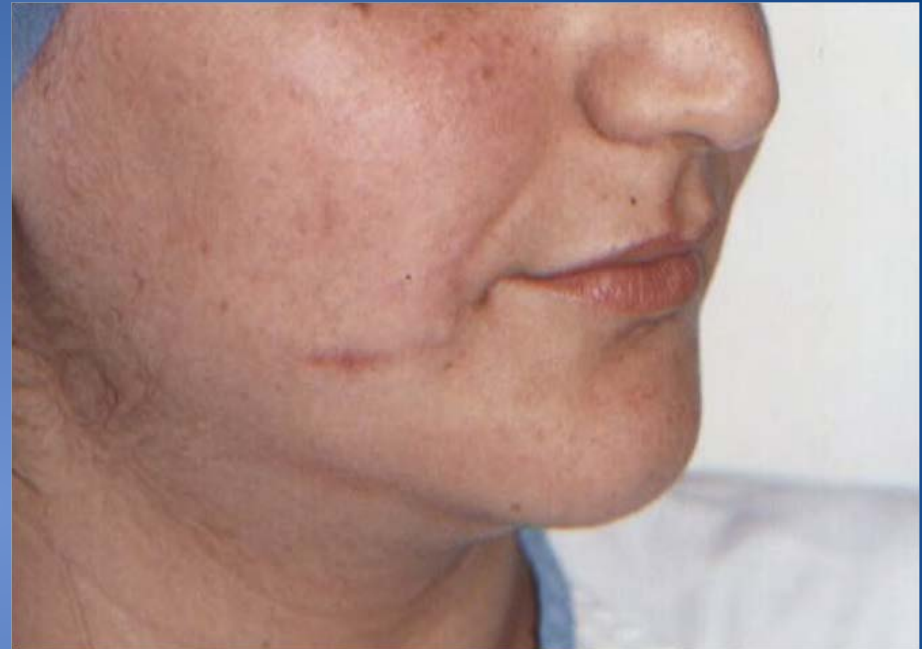Scars

Dr. Ibrahim EL ACHKAR

Before



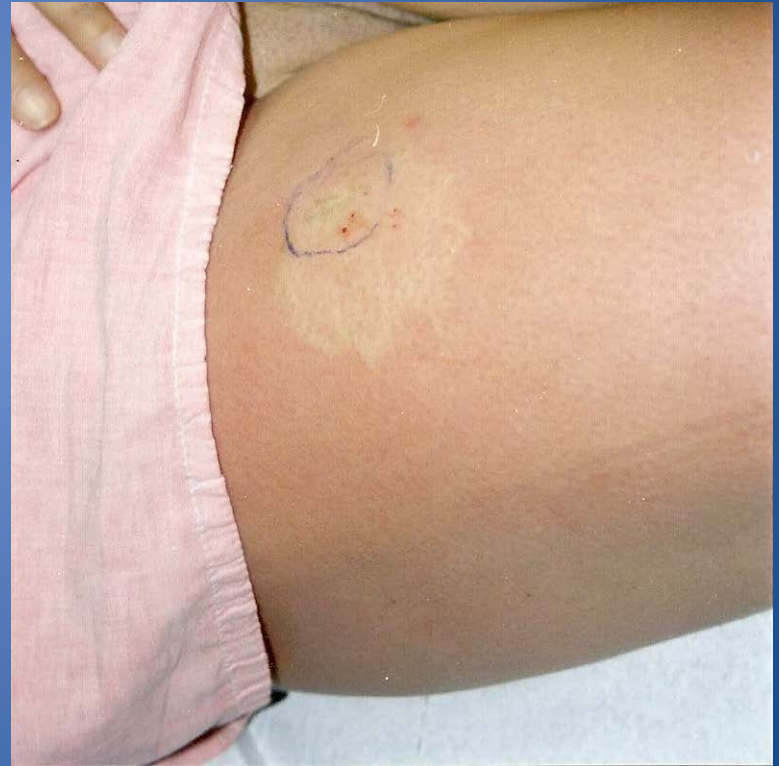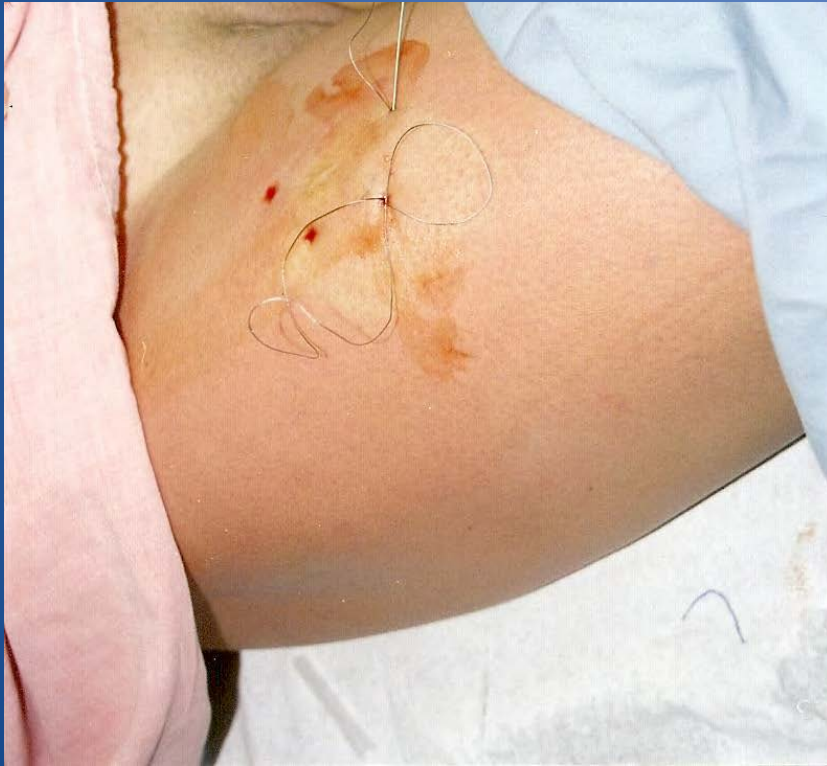After



Dr. Ibrahim EL ACHKAR

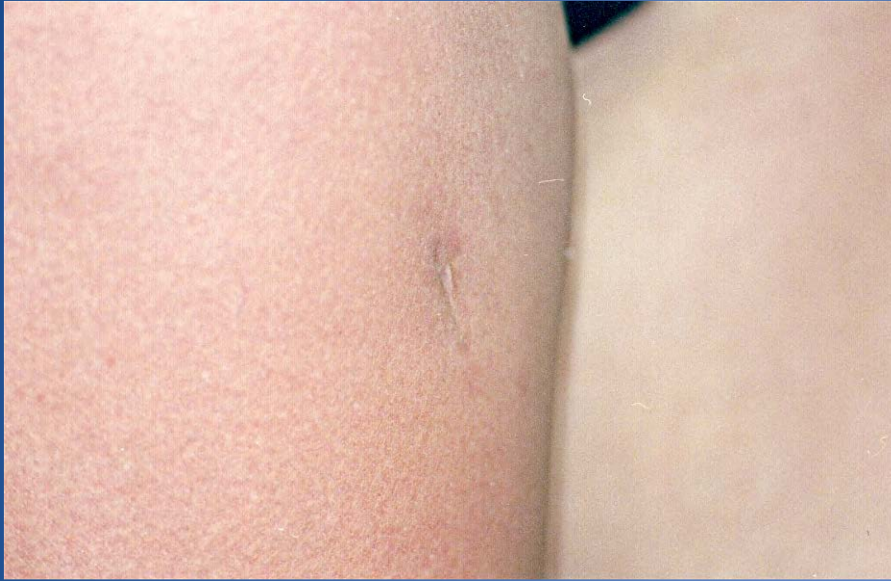
Before

After

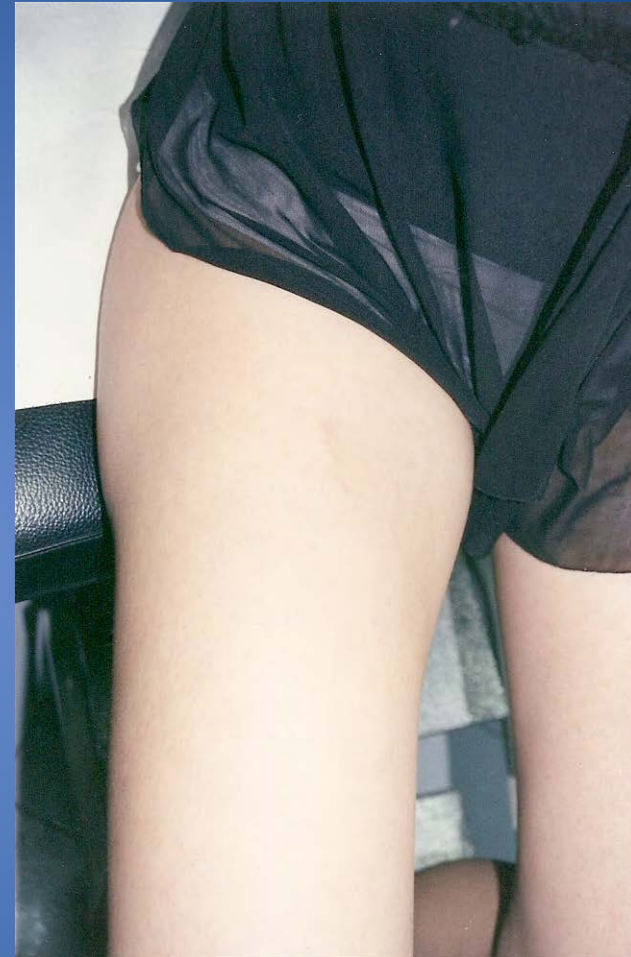

Dr. Ibrahim EL ACHKAR


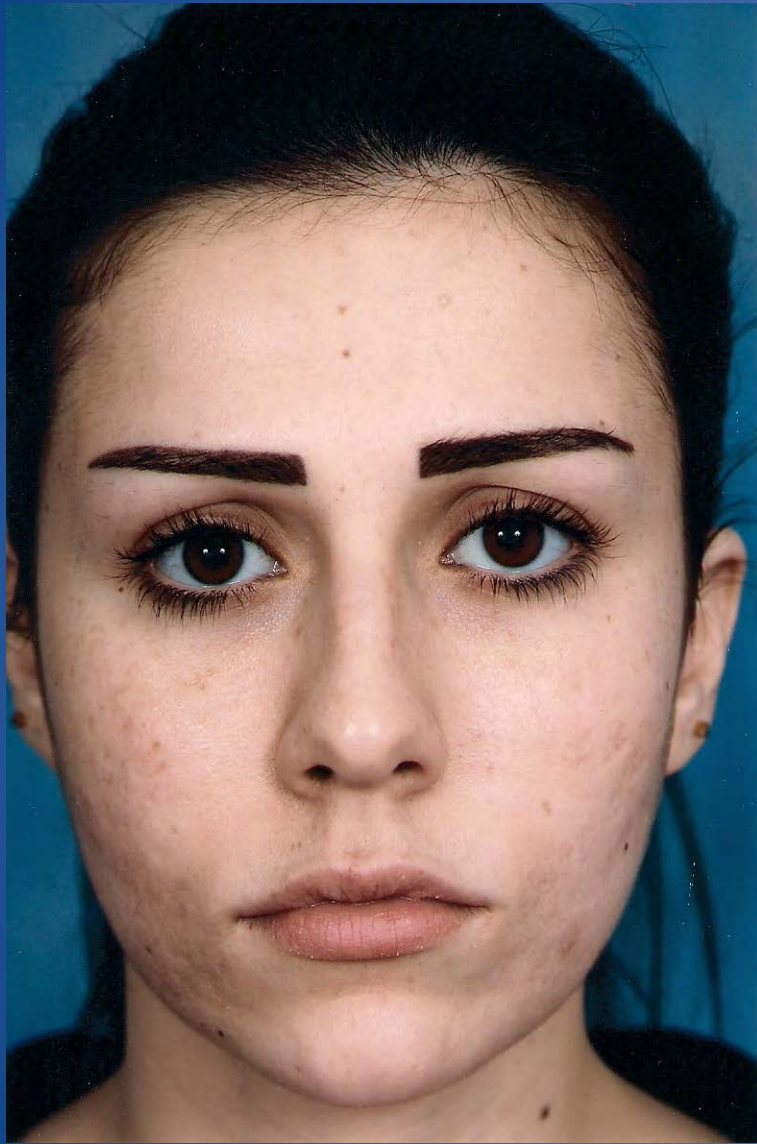
Before



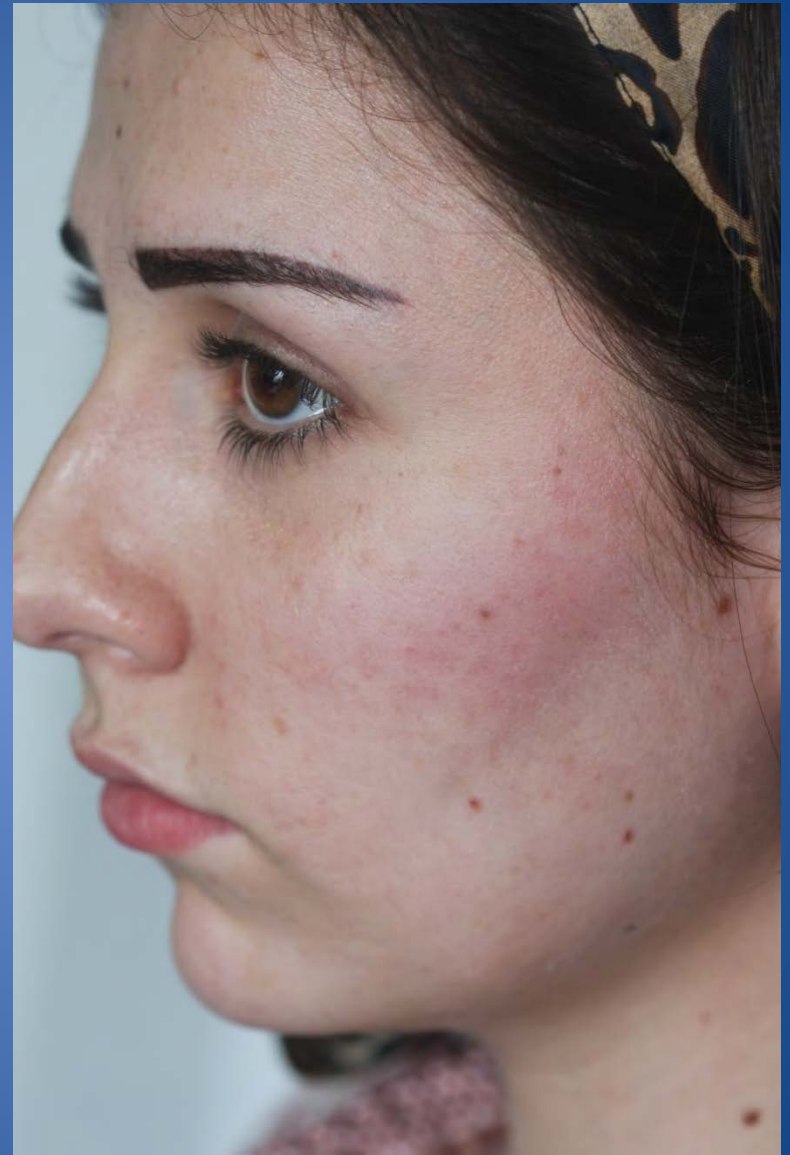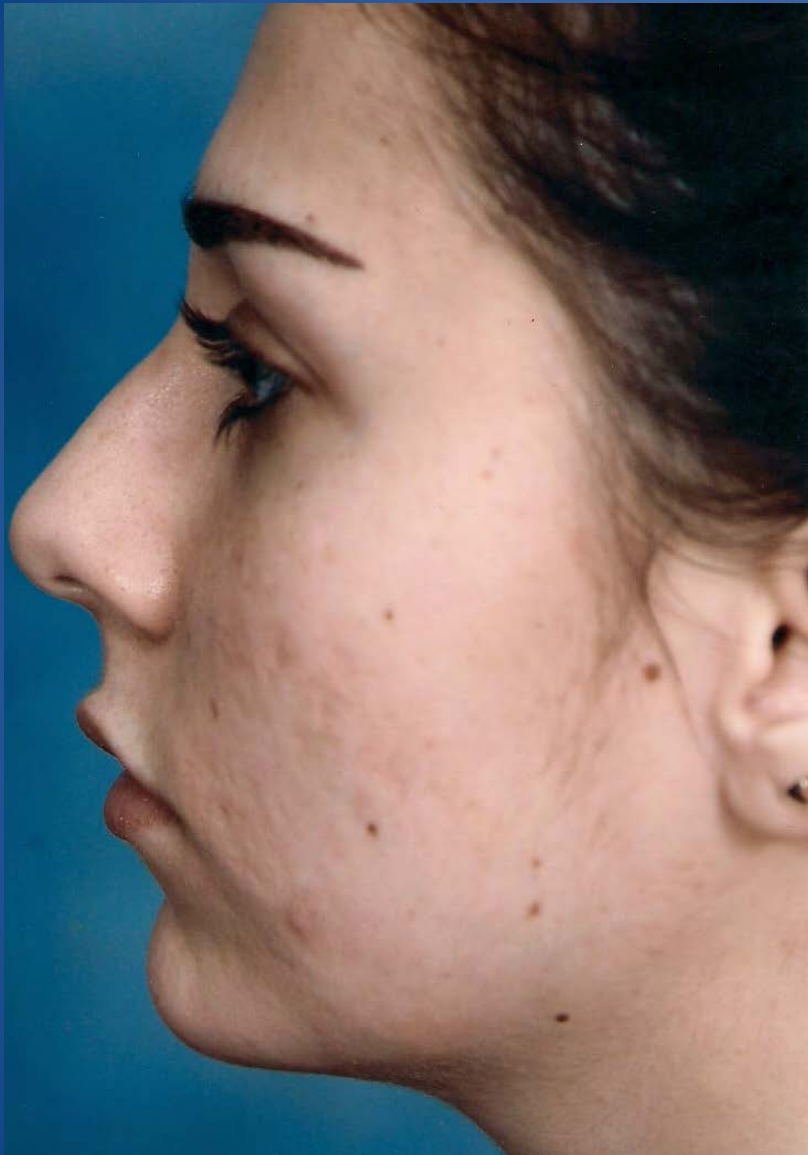After



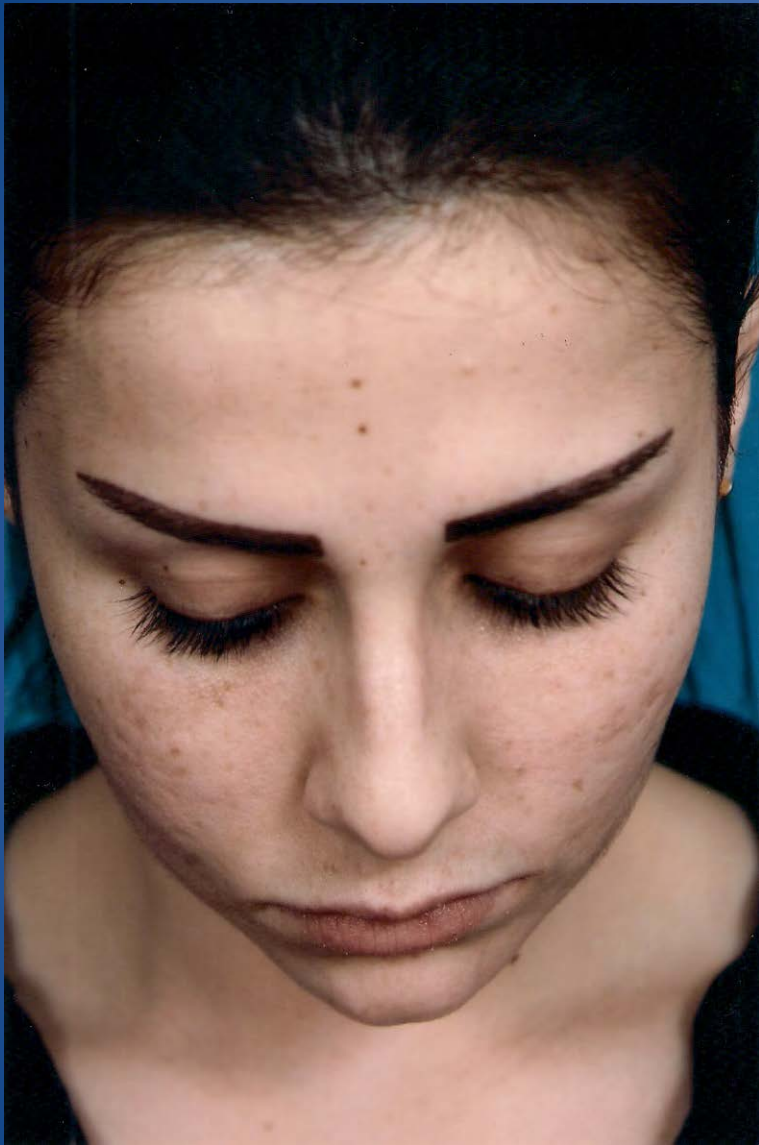
Dr. Ibrahim EL ACHKAR



Dr. Ibrahim EL ACHKAR



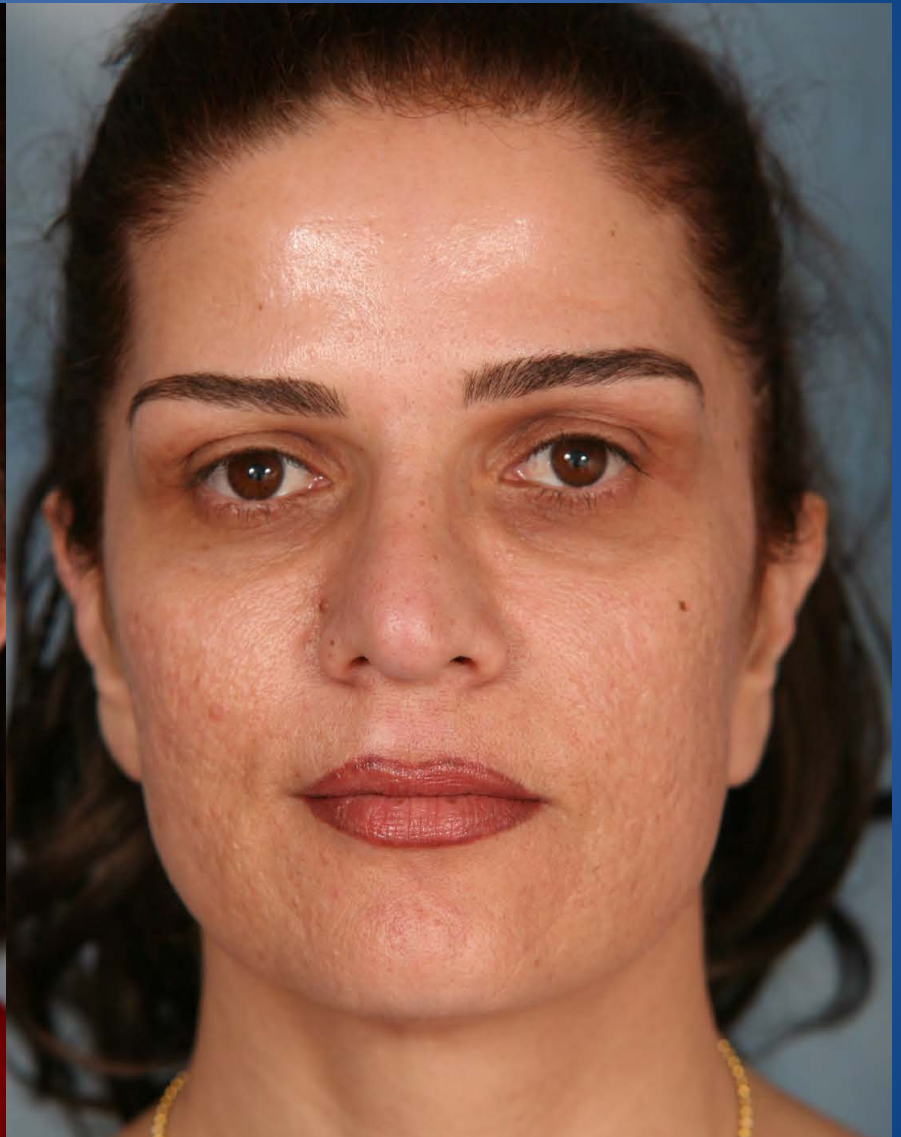
Dr. Ibrahim EL ACHKAR



Dr. Ibrahim EL ACHKAR

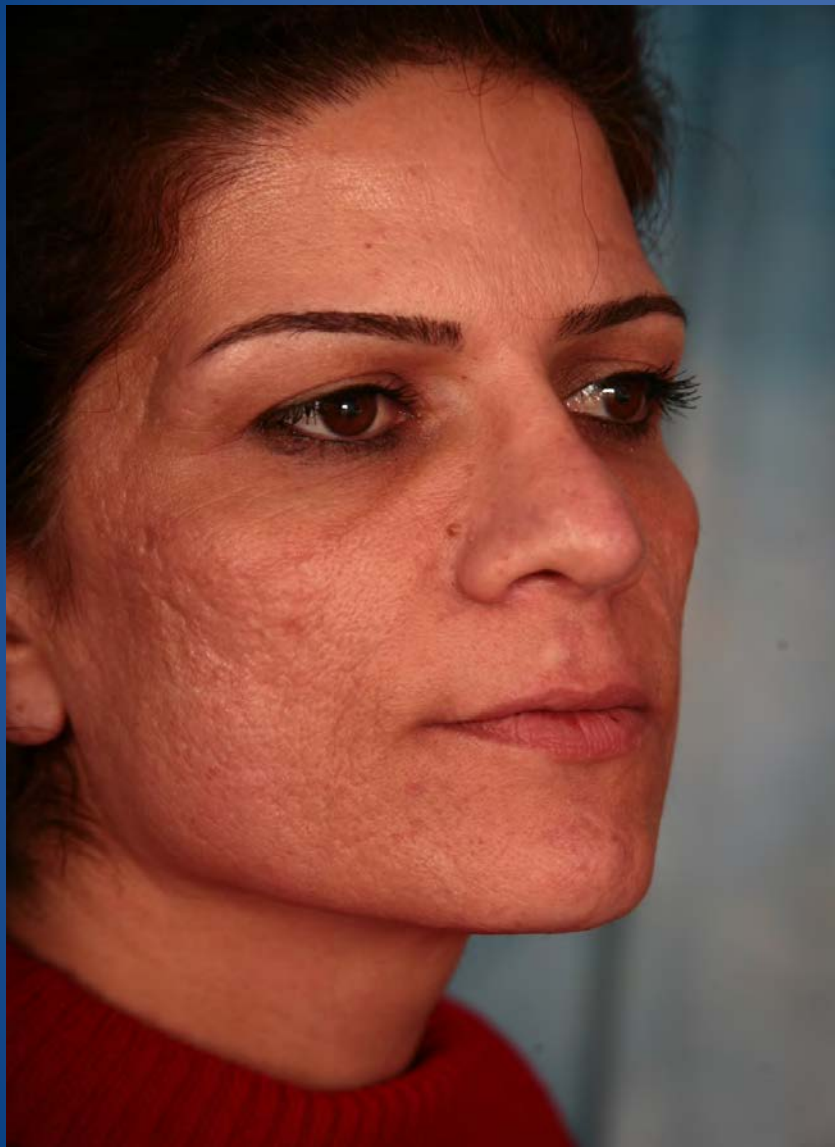Before

After



Dr. Ibrahim EL ACHKAR

Before



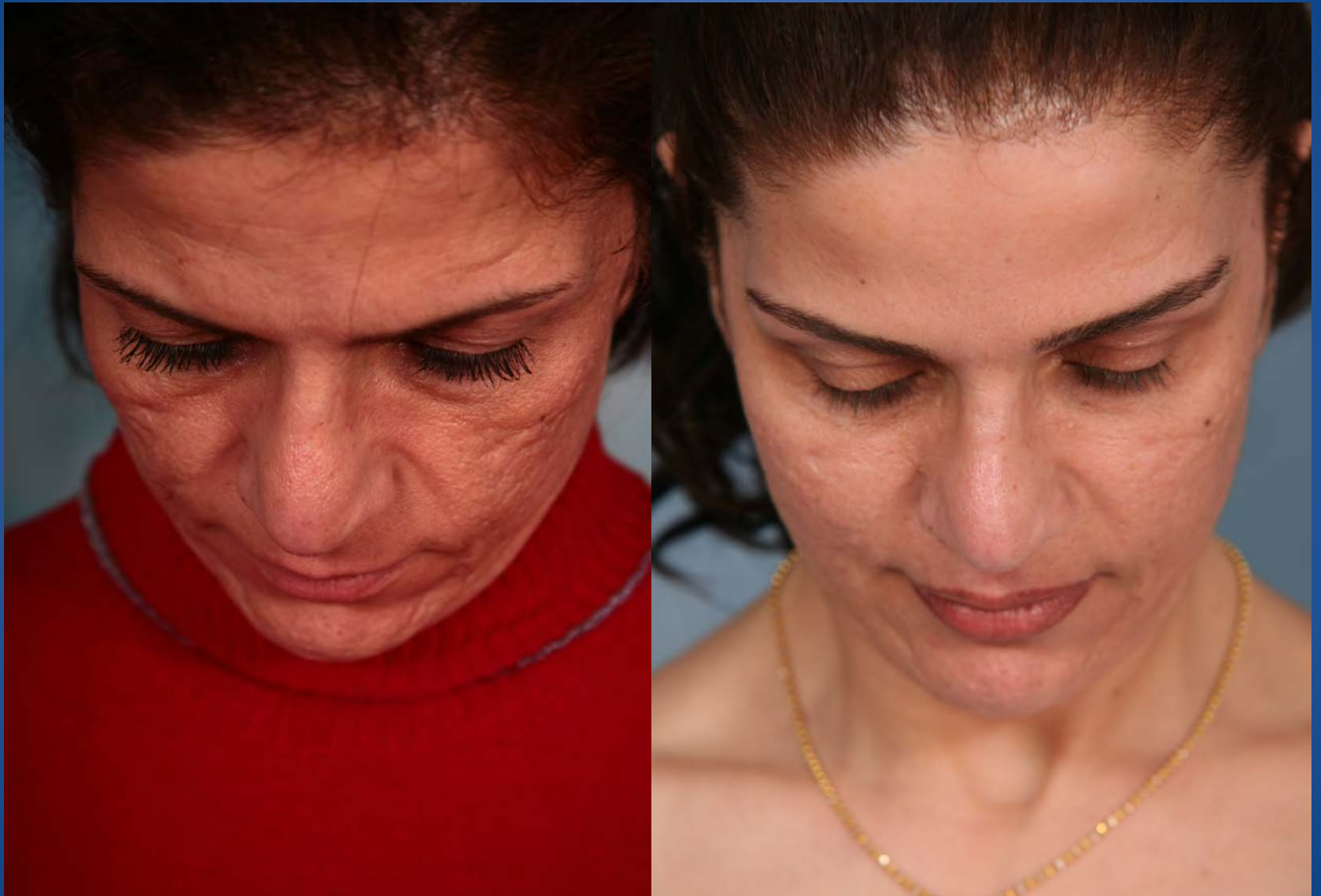After



Dr. Ibrahim EL ACHKAR

Before

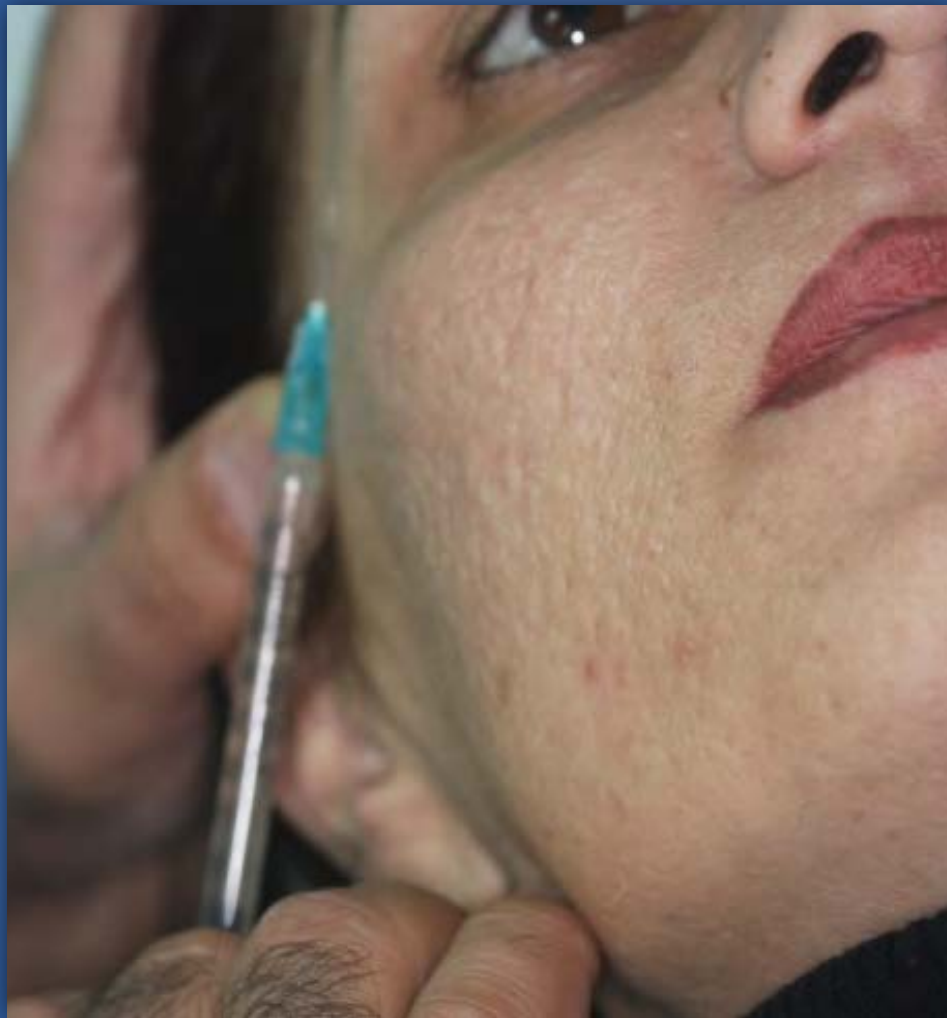After



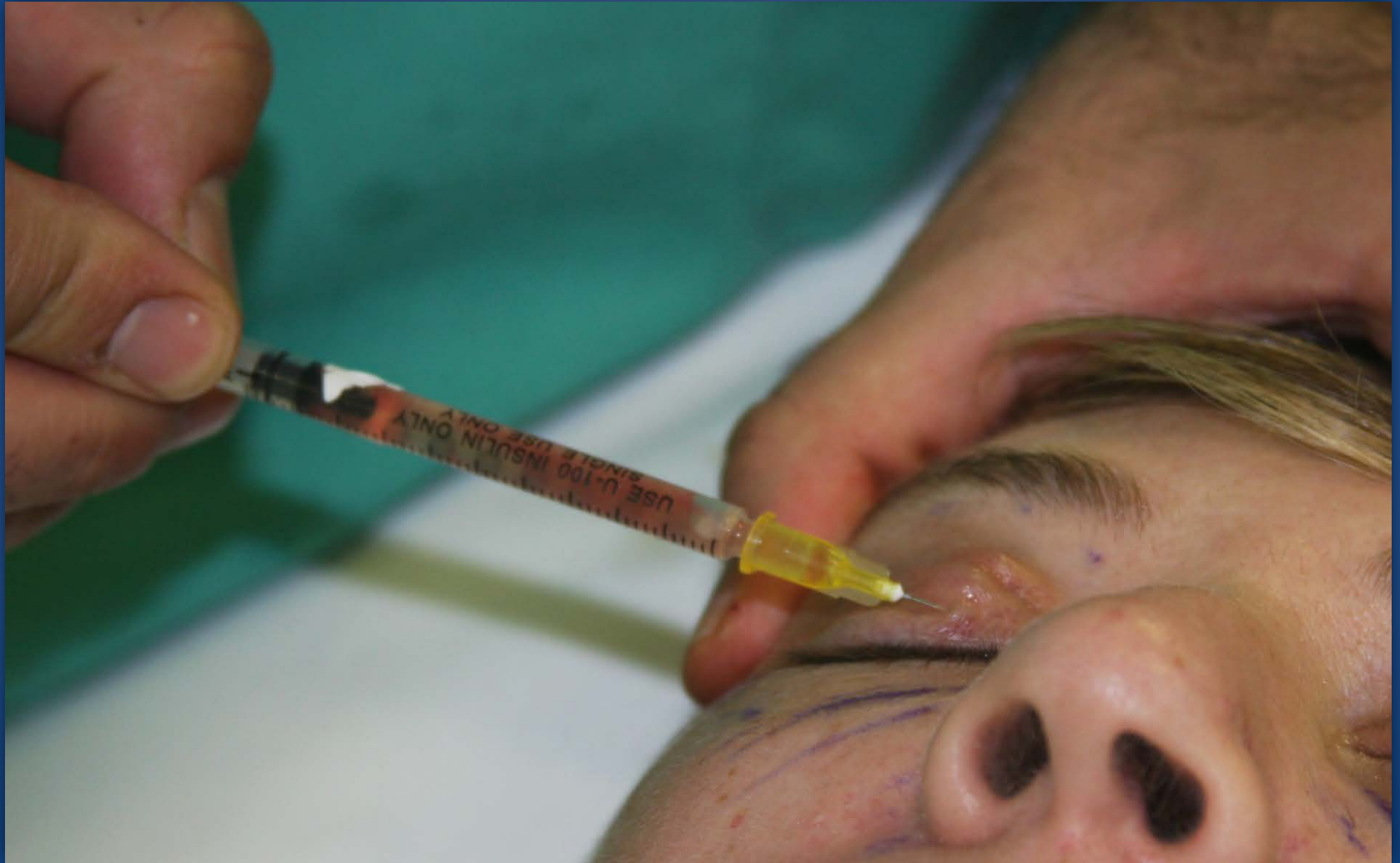Dr. Ibrahim EL ACHKAR

Discussion

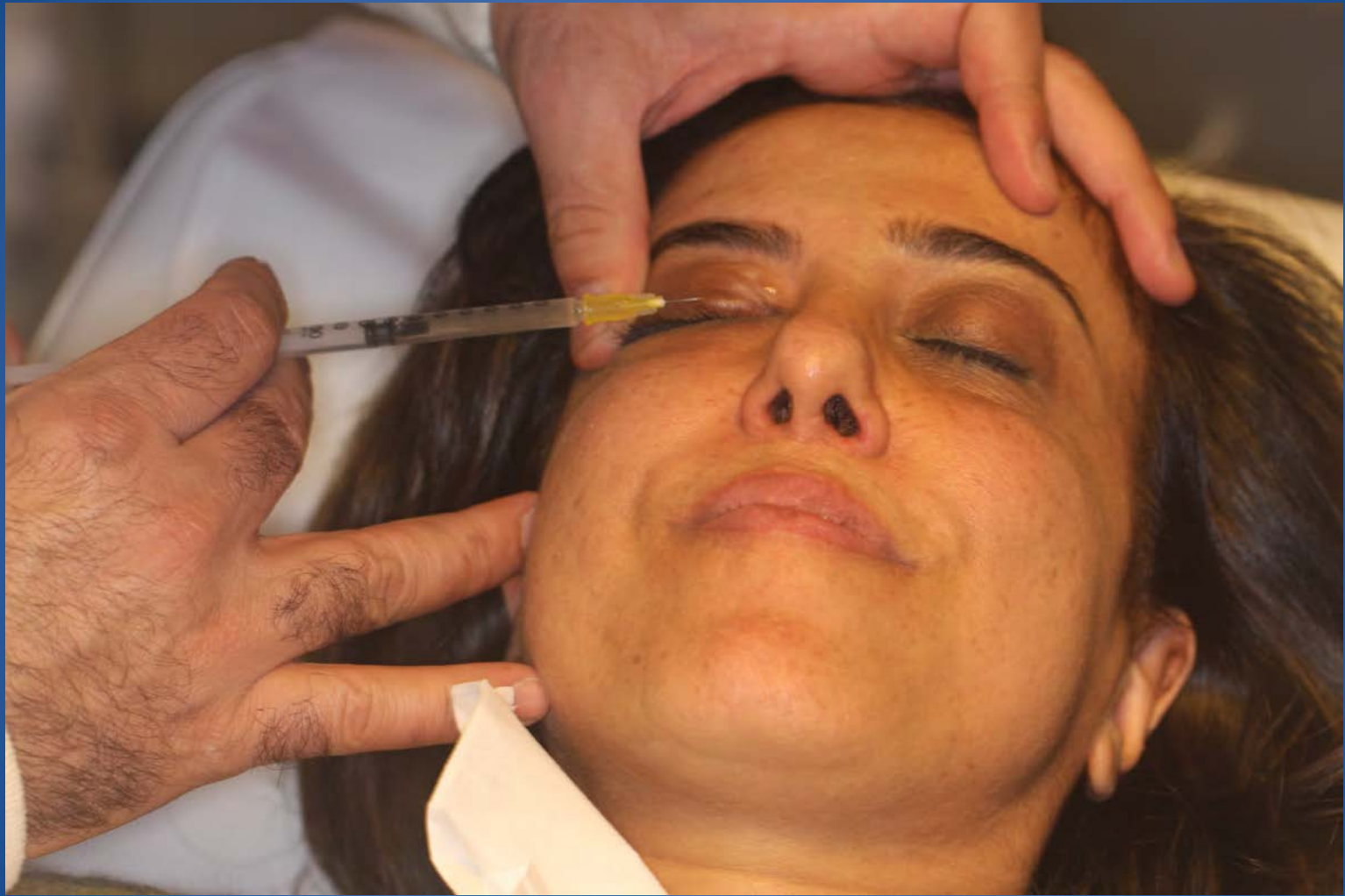Dr. Ibrahim EL ACHKAR



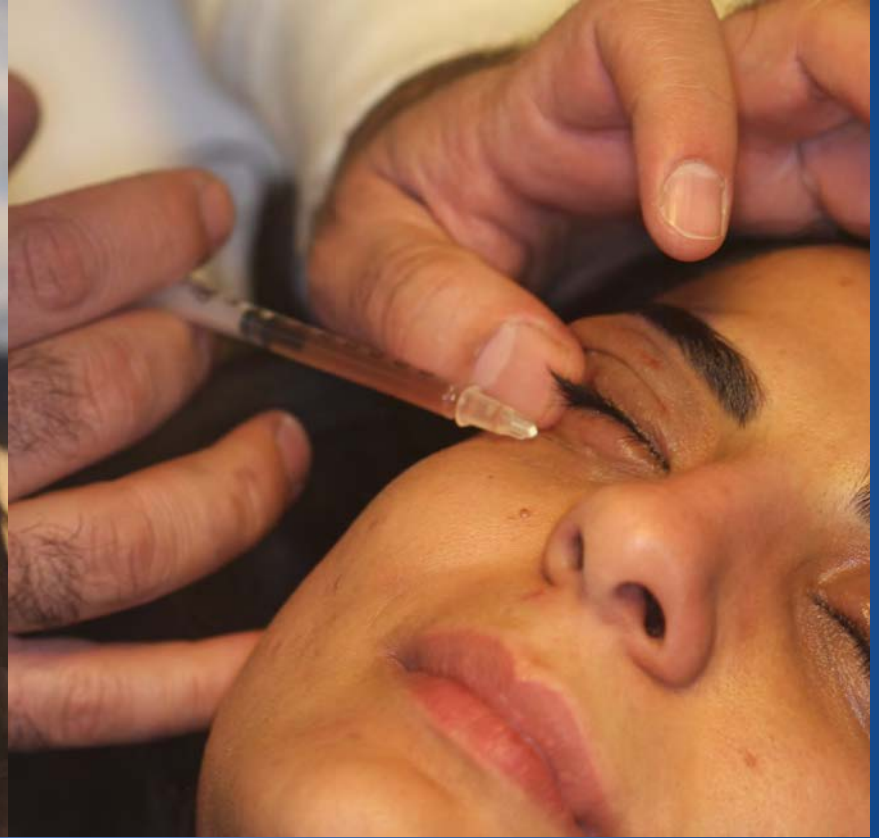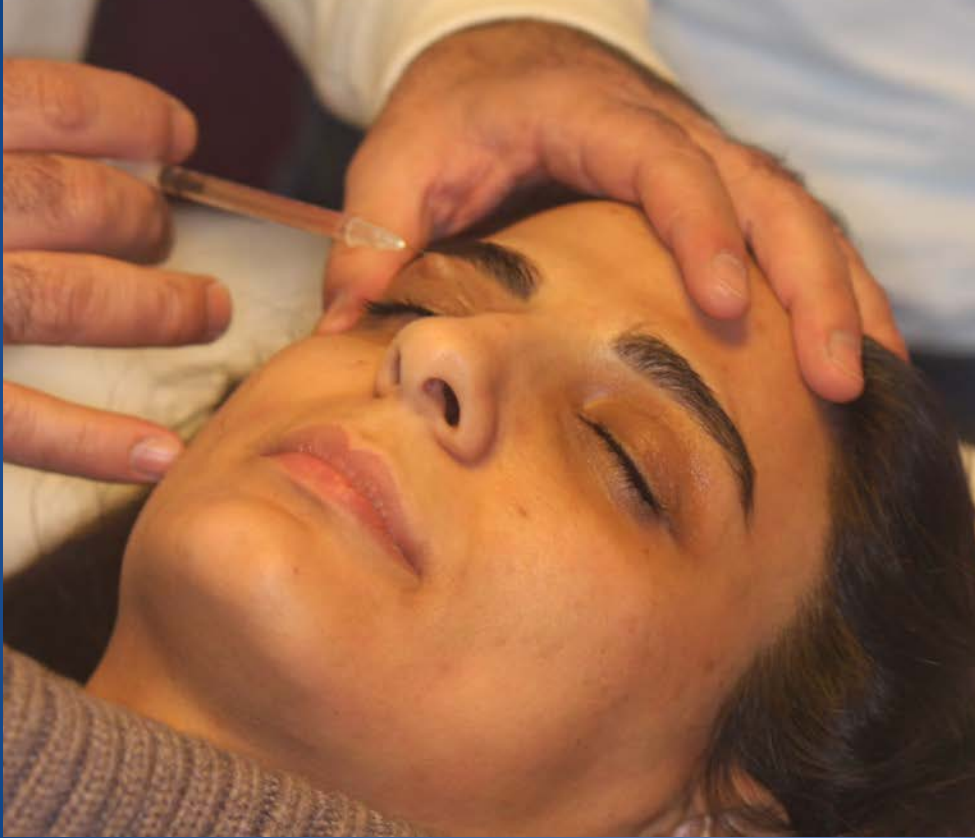Dr. Ibrahim EL ACHKAR



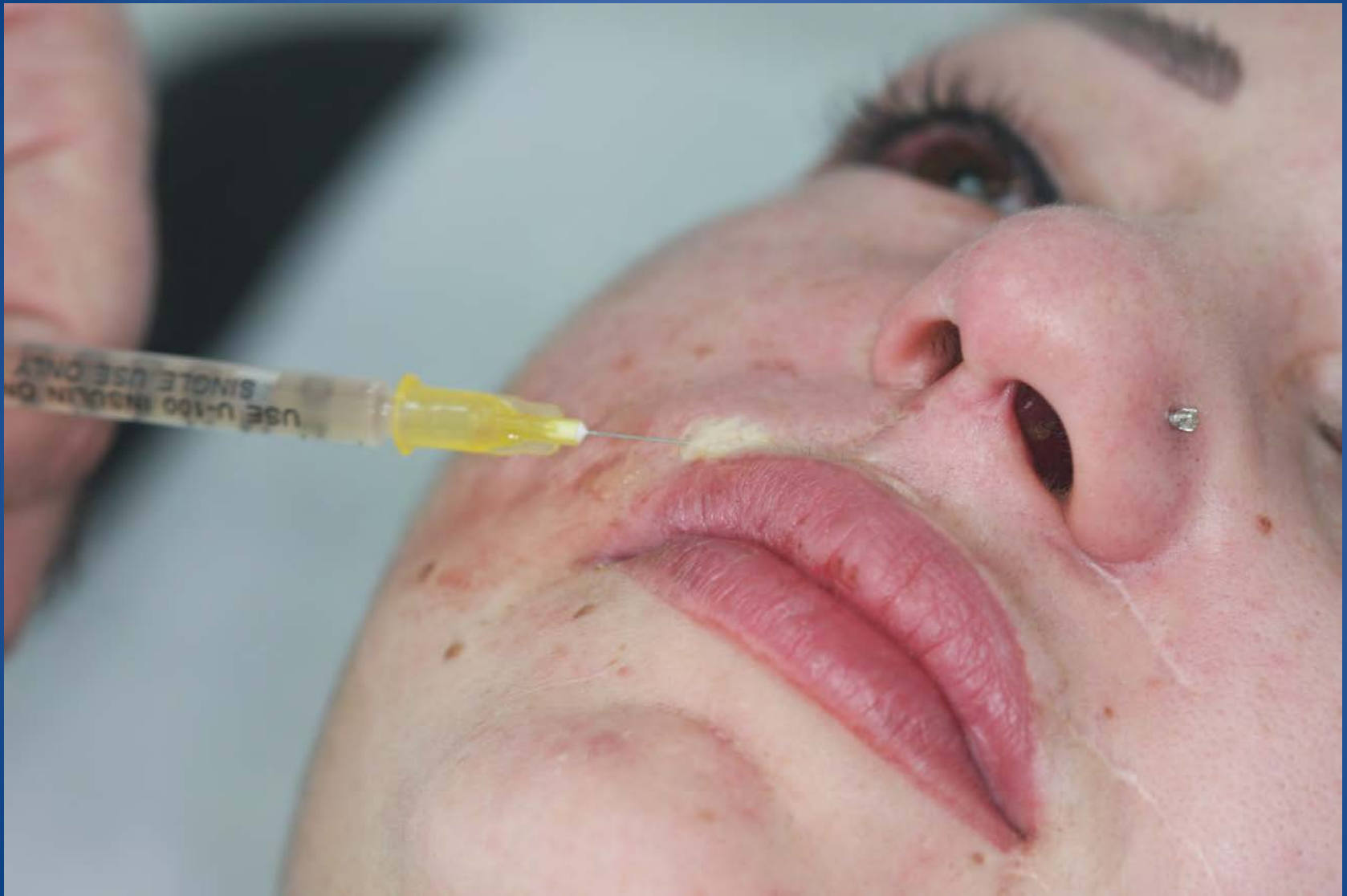Dr. Ibrahim EL ACHKAR



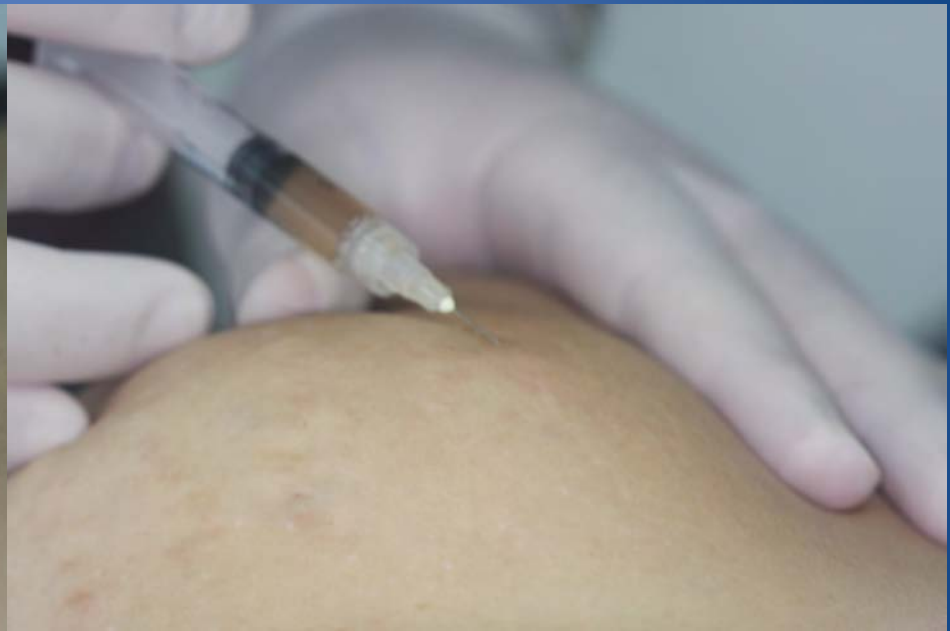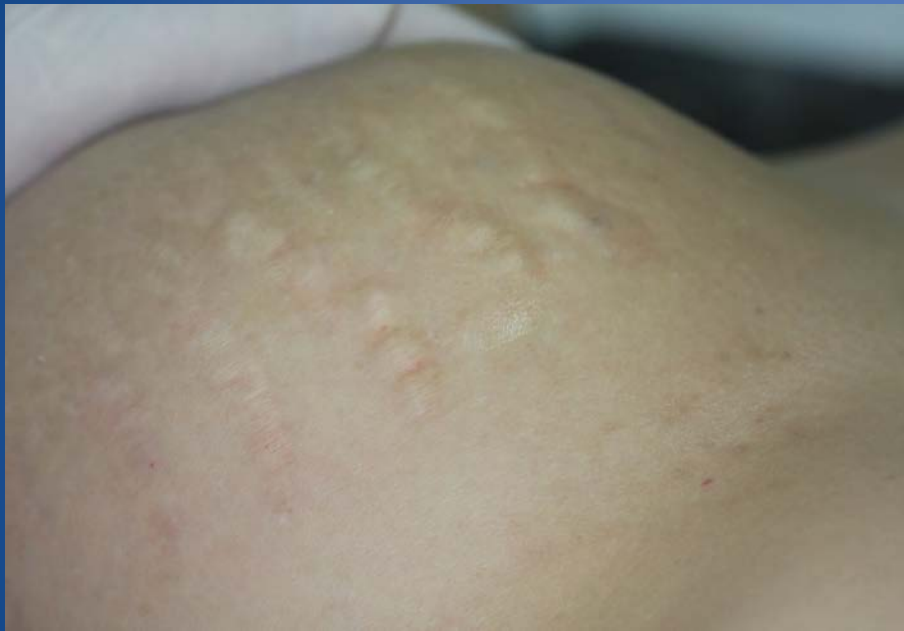Dr. Ibrahim EL ACHKAR



Dr. Ibrahim EL ACHKAR



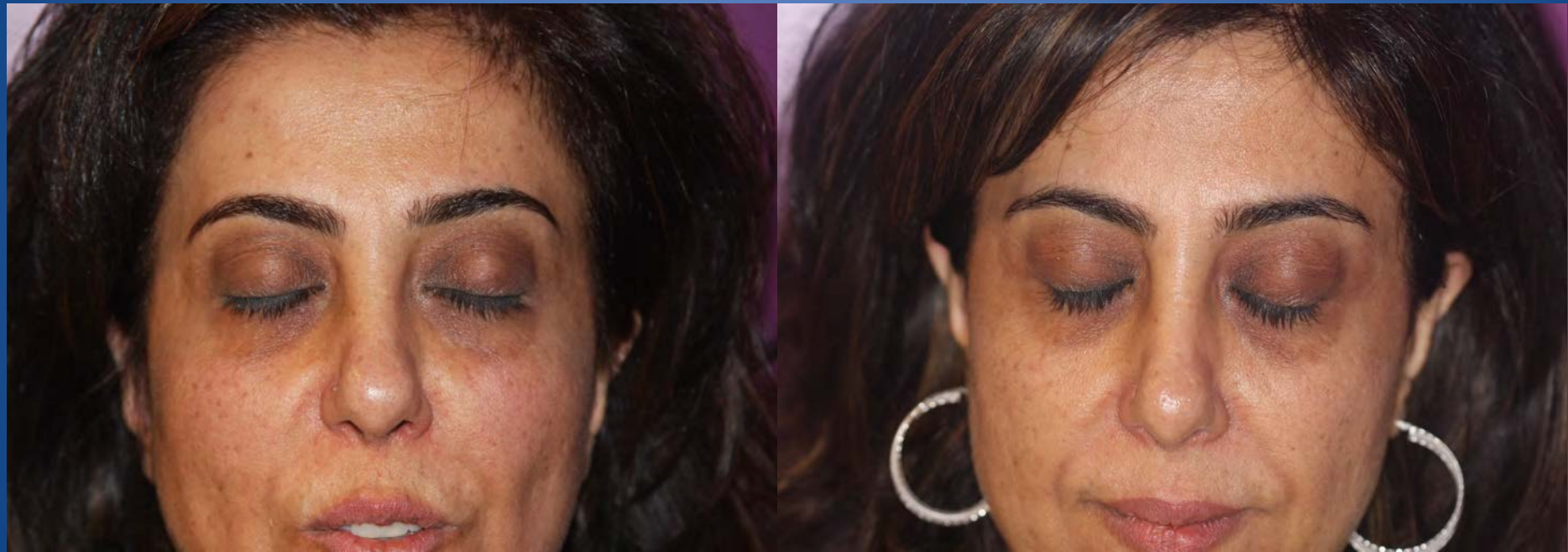Dr. Ibrahim EL ACHKAR



Dr. Ibrahim EL ACHKAR

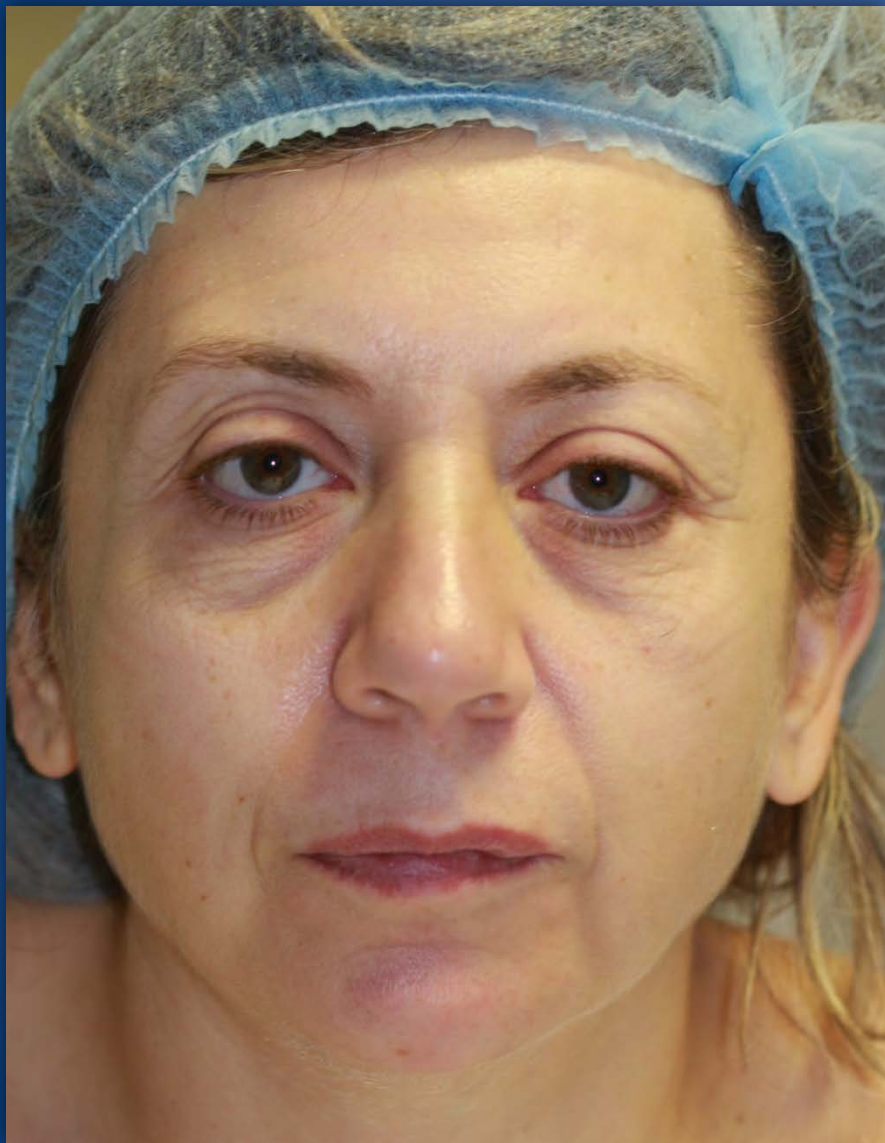Before

After



Dr. Ibrahim EL ACHKAR

Before



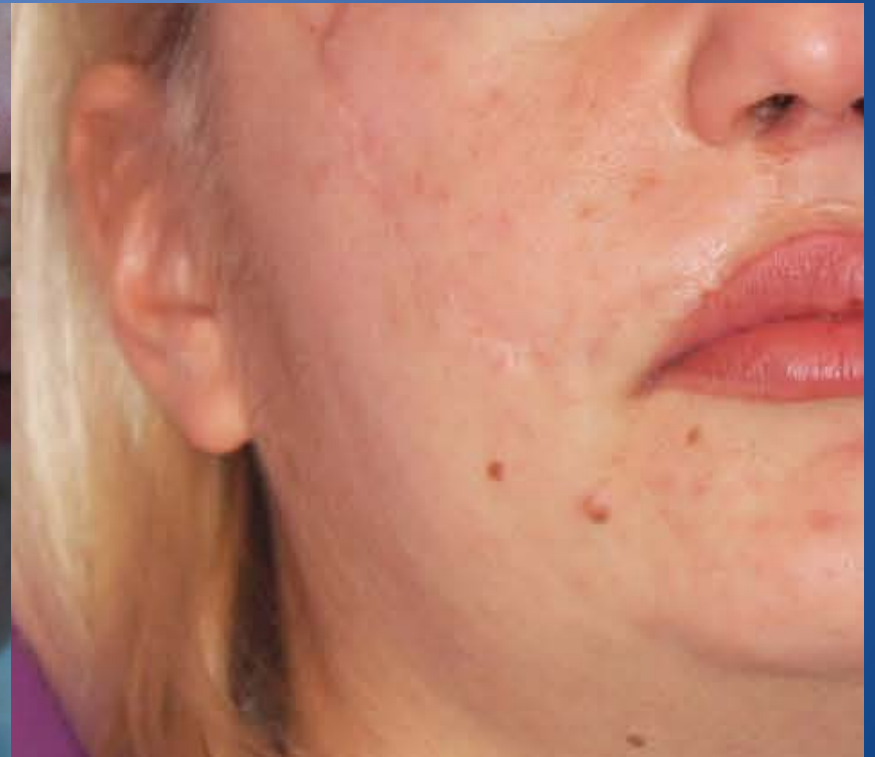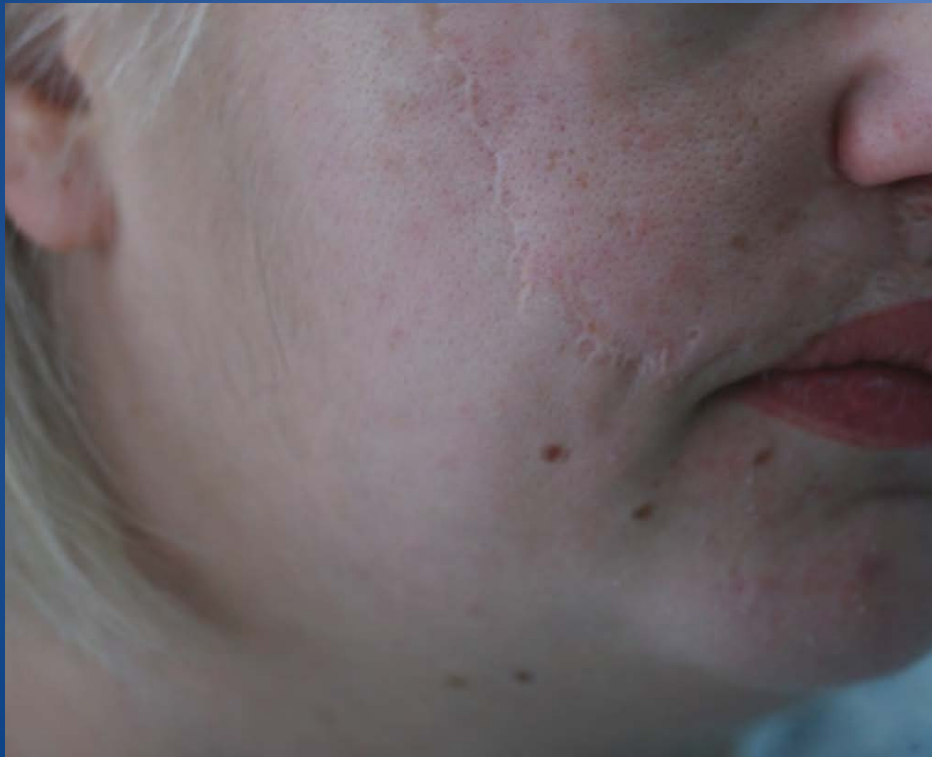After



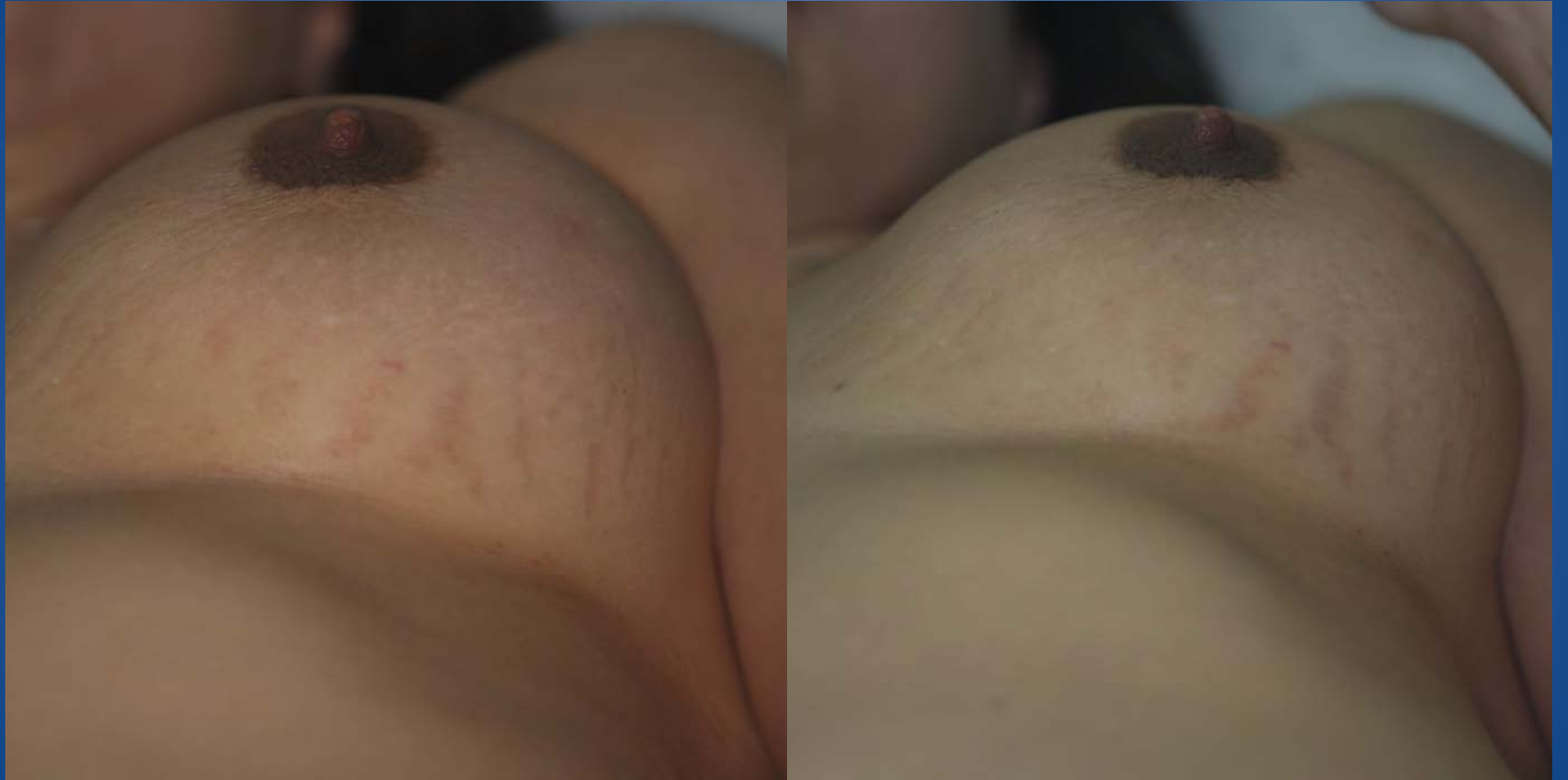Dr. Ibrahim EL ACHKAR

Before

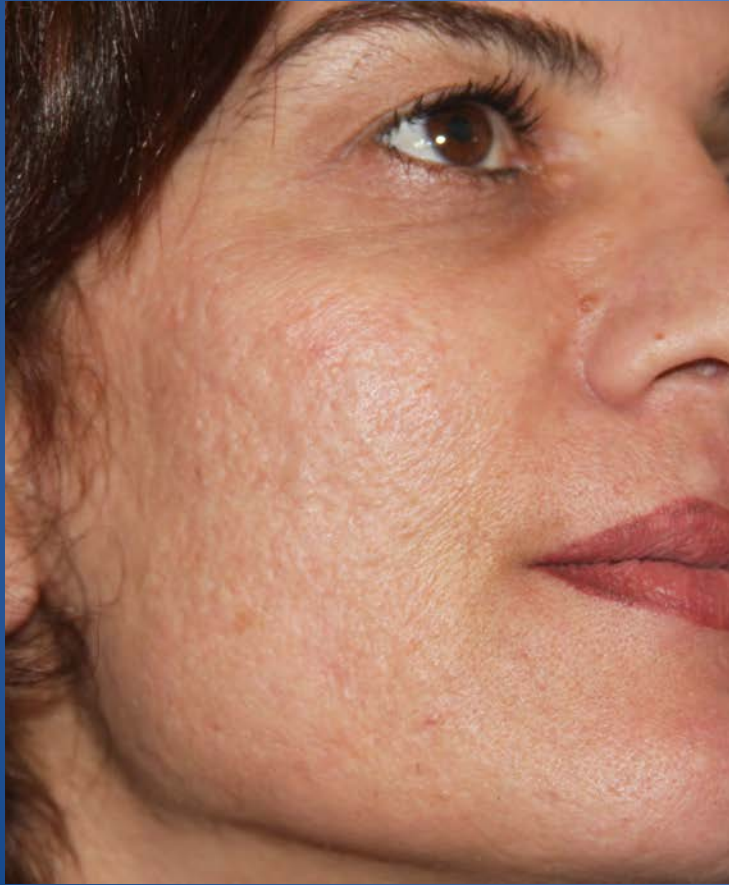
After



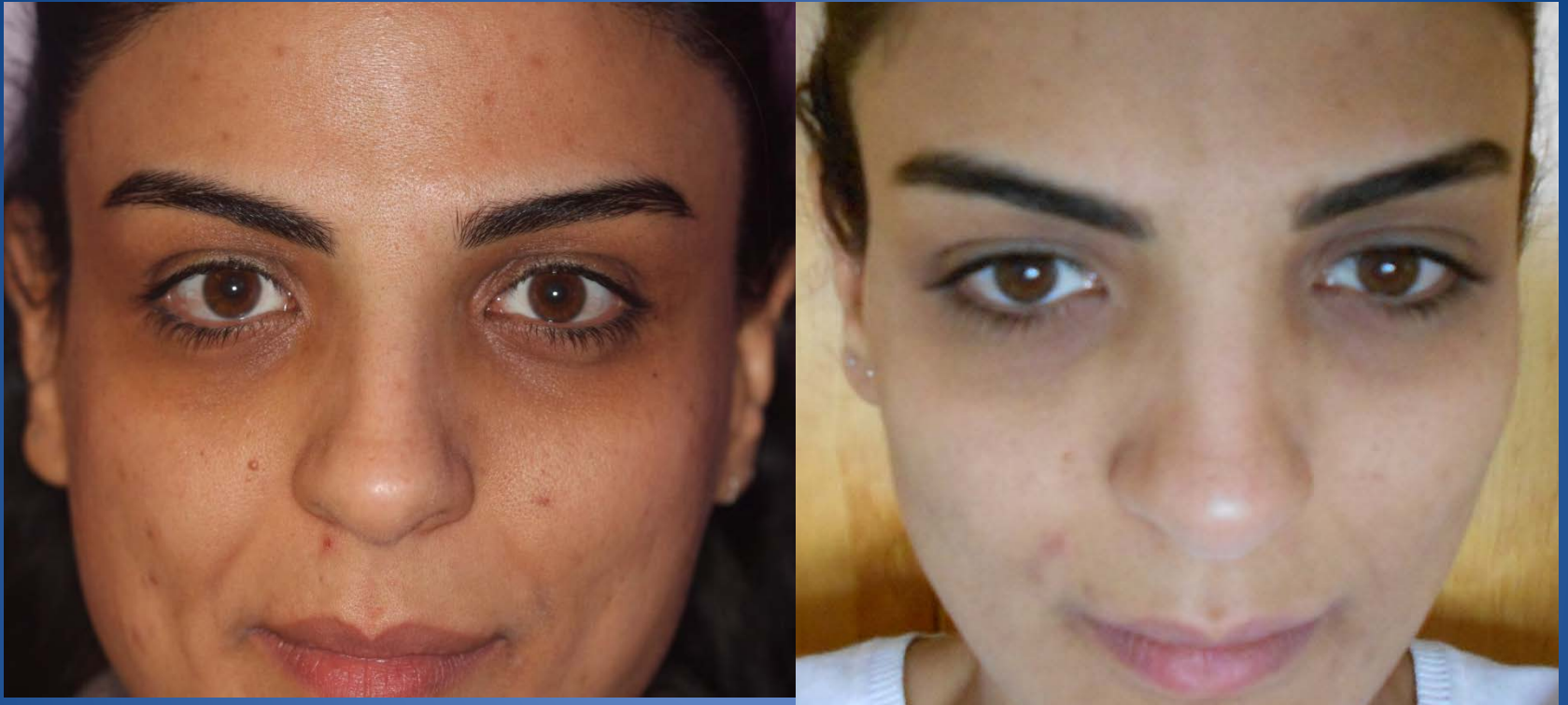
Dr. Ibrahim EL ACHKAR



Dr. Ibrahim EL ACHKAR



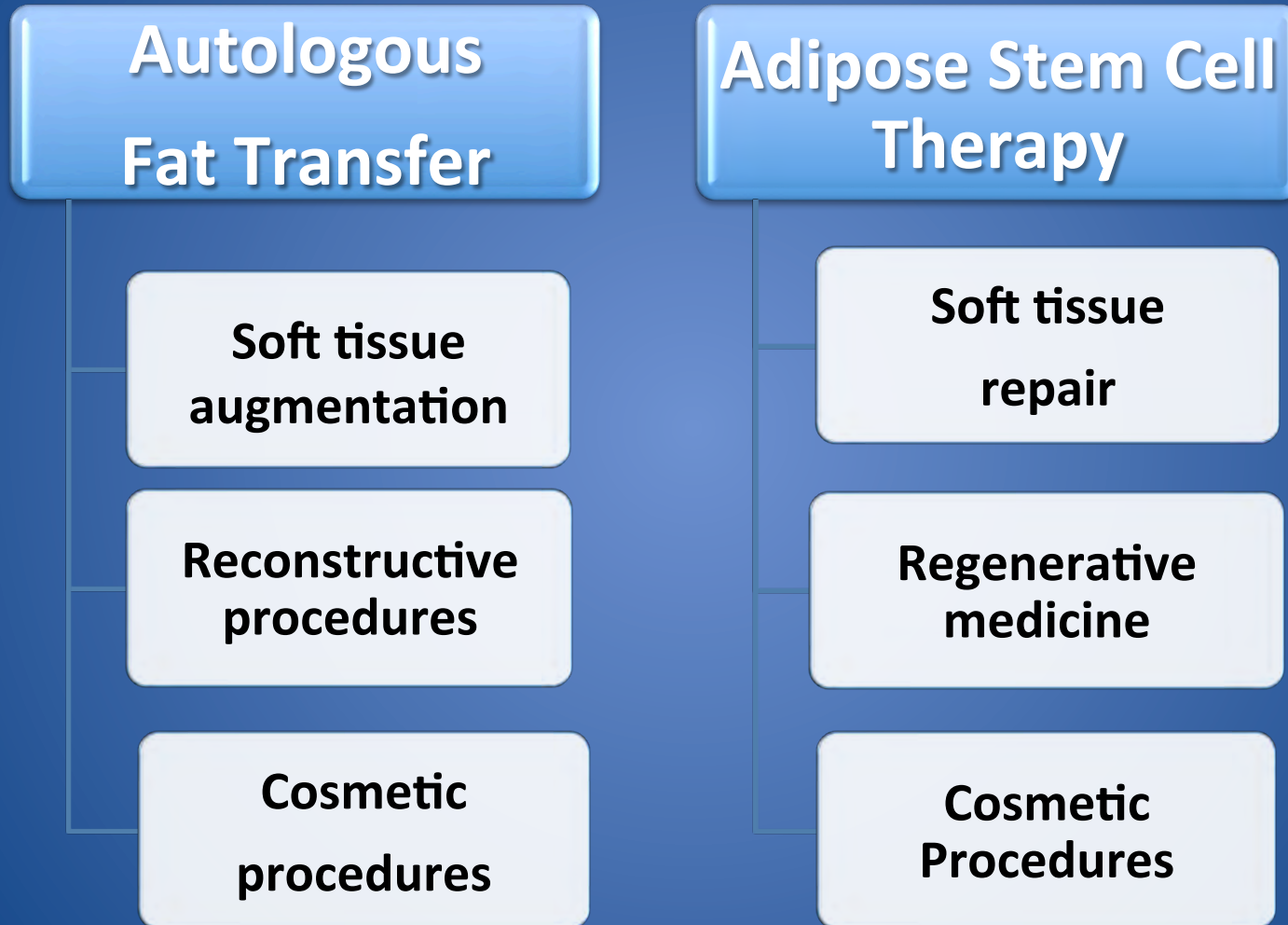
Dr. Ibrahim EL ACHKAR



“Yes they are better, i guess i can feel about 30% better which is not bad after 2 months of the treatment. I will follow it up to see if it is still improving.”

Dr. Ibrahim EL ACHKAR

Discussion



ASC Challenges

- ❖ Understanding mechanism of action
- ❖ Regulatory hurdles & safety concerns
- ❖ Perception of hype vs hope
- ❖ Manufacturing methods & standards
operating procedures

Design and Dynamic Culture of 3D-Scaffolds for Cartilage Tissue Engineering

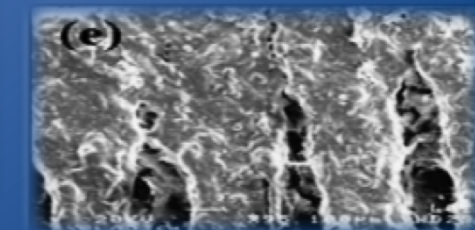
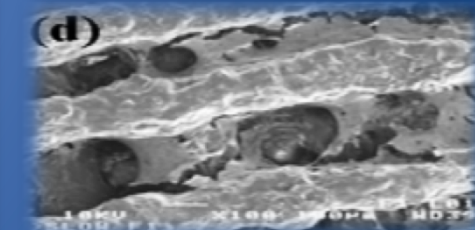

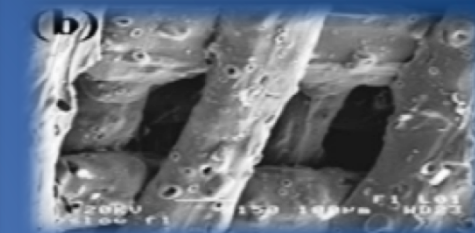

ROUWAYDA EL-AYOUBI, CHRISTIAN DEGRANDPRÉ, ROBERT DIRADDO,
AND AZIZEH-MITRA YOUSEFI*

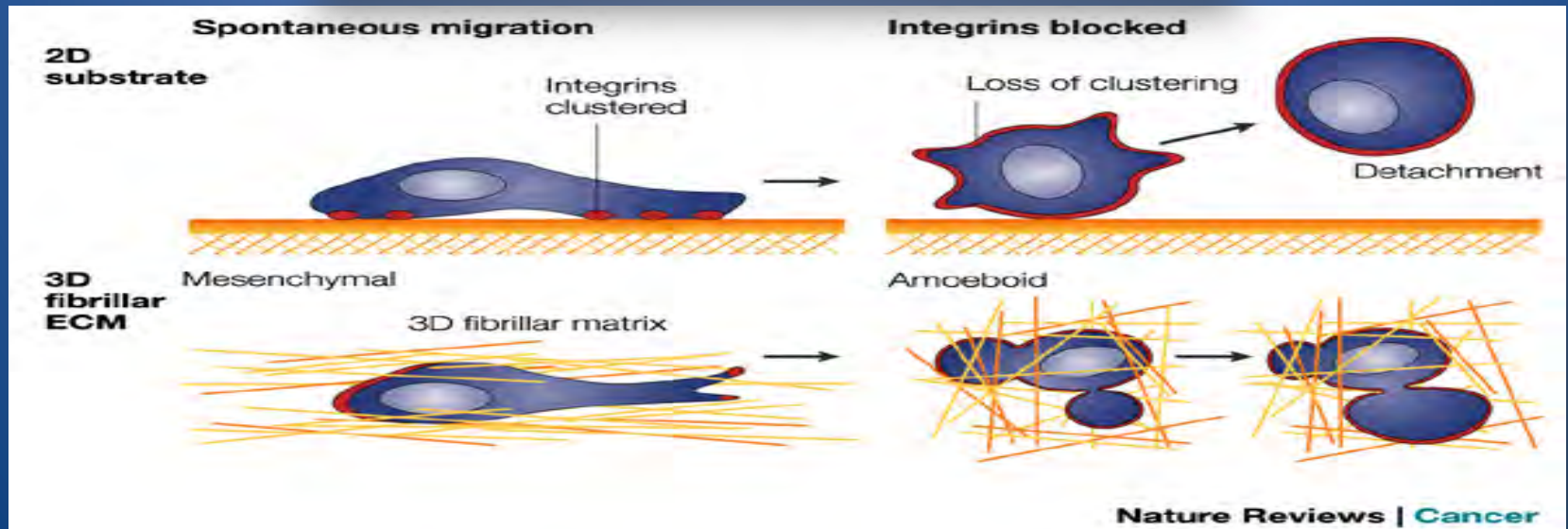
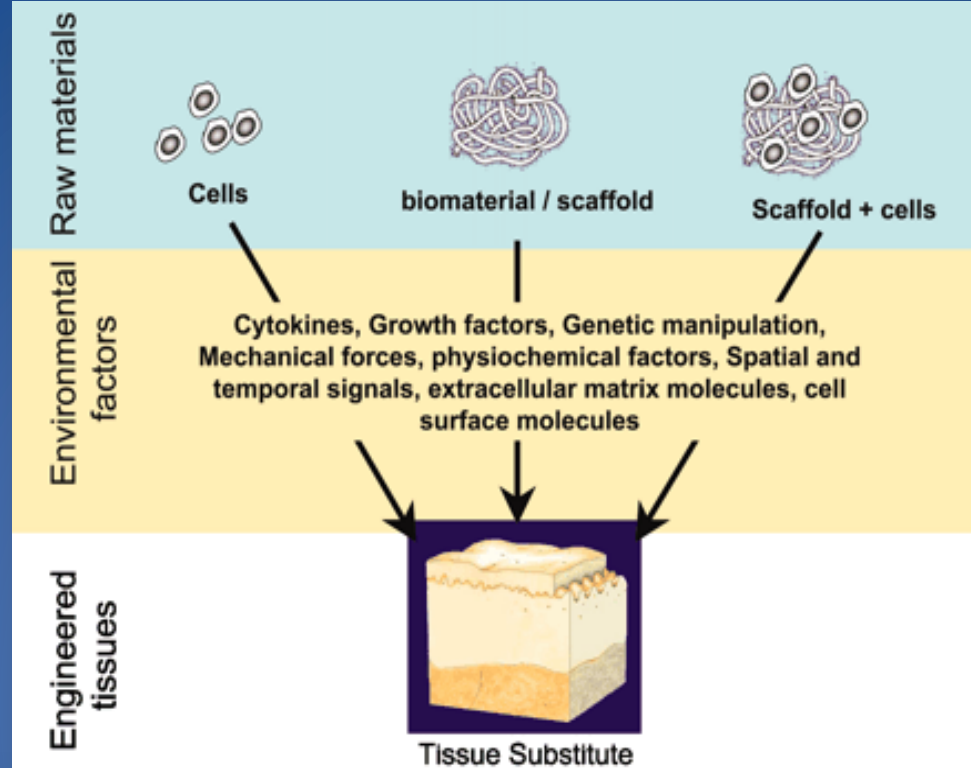
*Industrial Materials Institute, National Research Council of Canada
Boucherville, QC, Canada*

PATRICK LAVIGNE

Maisonneuve-Rosemont Hospital, Montreal, QC, Canada


ABSTRACT: Engineered scaffolds for tissue-engineering should be designed to match the stiffness and strength of healthy tissues while maintaining an interconnected pore network and a reasonable porosity. In this work, we have used 3D-plotting technique to produce poly-L-Lactide macroporous scaffolds with two different pore sizes. The ability of these macroporous scaffolds to support chondrocyte attachment and viability were compared under static and dynamic loading *in vitro*. Moreover, the 3D-plotting technique was combined with porogen-leaching, leading to macro/microporous scaffolds, so as to examine the effect of microporosity on the level of cell attachment and viability under similar loading condition.

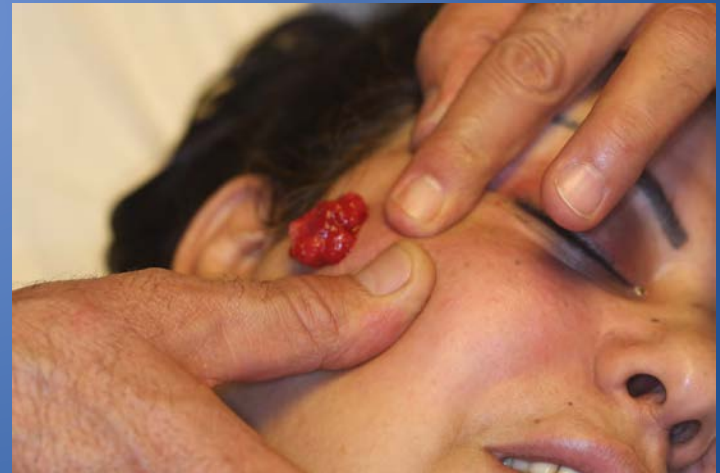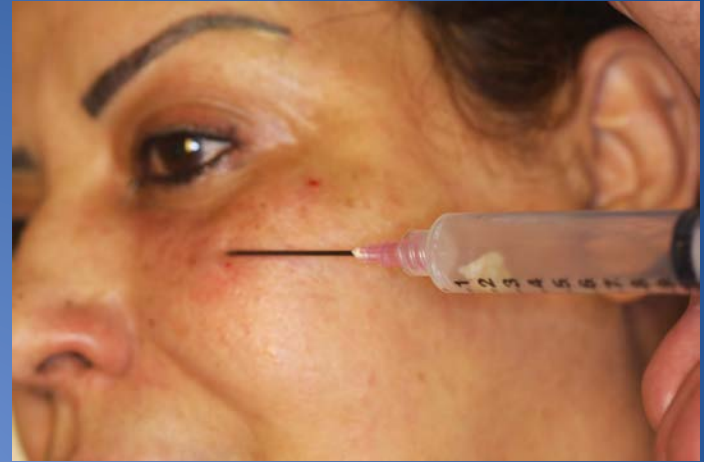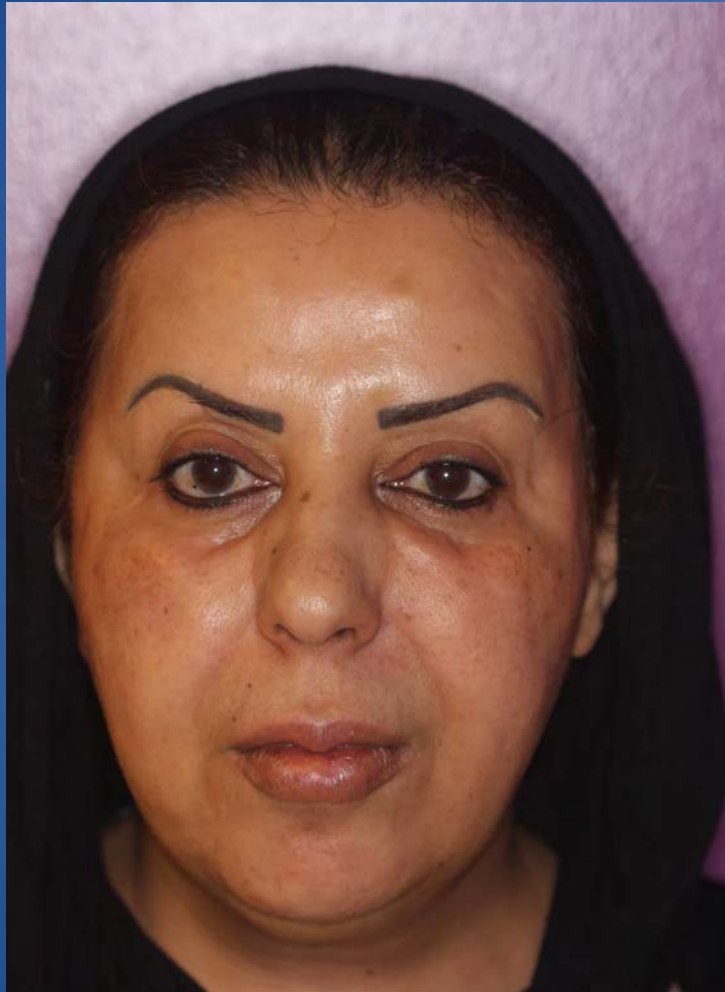




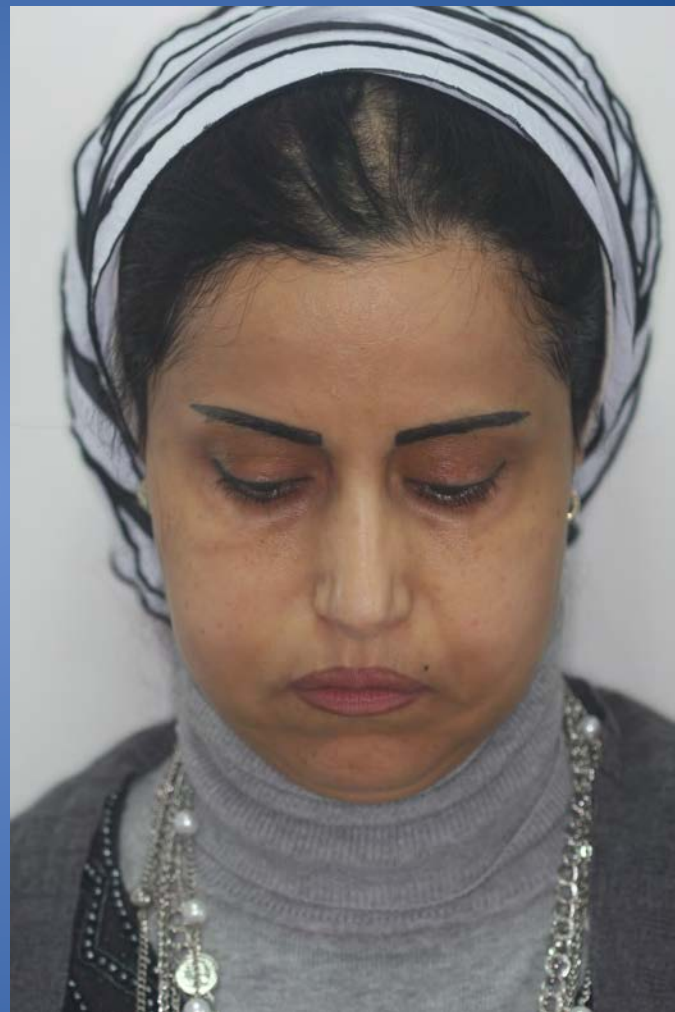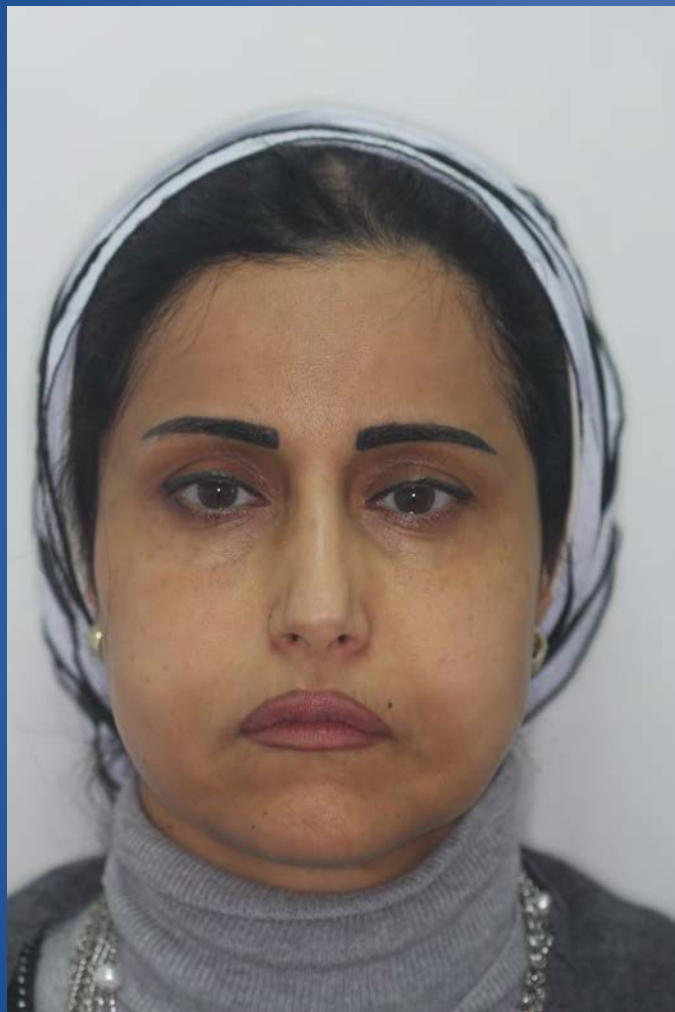Despite modern medicine:

- ✓ Most stem cell therapies / procedures are still primitive
- ✓ Ongoing research
- ✓ Applications are to be proven

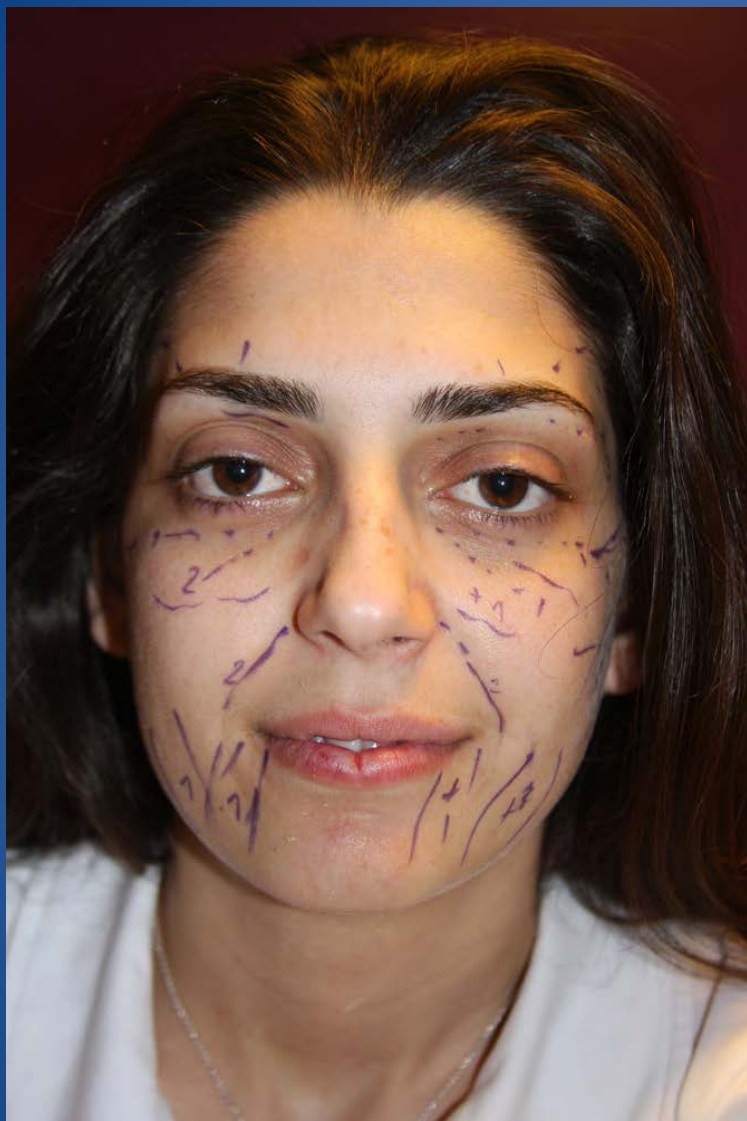




Dr. Ibrahim EL ACHKAR



Dr. Ibrahim EL ACHKAR



Dr. Ibrahim EL ACHKAR

Conclusion

- The use of fat graft with or without ADRCs provides great results in aesthetic, rejuvenation and regenerative procedures .There is an enormous amount of promise with stem cells in plastic and reconstructive surgery, which needs at least 5 years to be scientifically proven

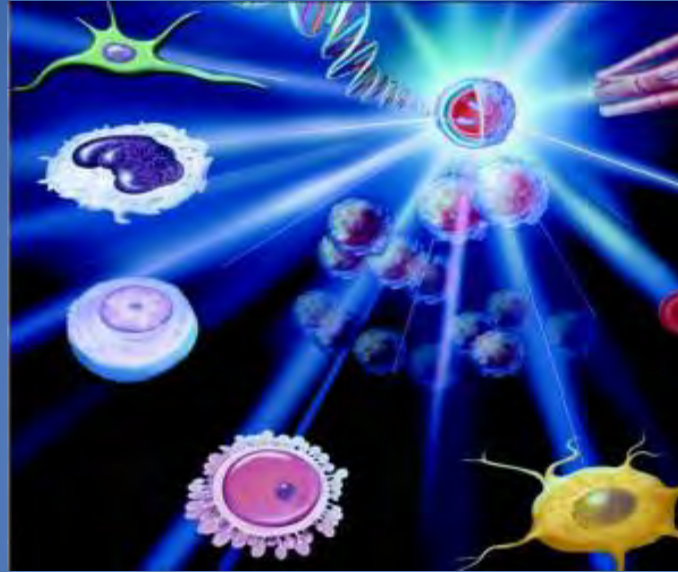
Conclusion



❖ Will stem cell therapeutics augment and enhance the current level of care we can offer to patients?

❖ Will it be cost effective?

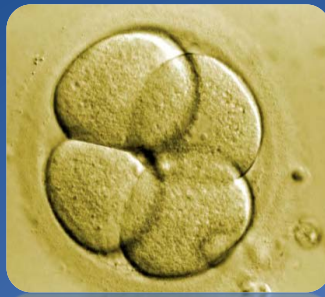Stem Cells



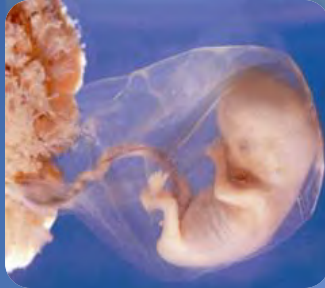**In the body,
They are included in very small numbers and occupy
a place so discreet that their existence
is long gone ignored**

Dr. Ibrahim EL ACHKAR

Pre-conception



Prenatal



Young



Adultes



Plastic Surgery

Stem Cells



1. Origin
2. Preservation
3. Therapy

What's So Special About Stem Cells ?

- **Immature** : Unspecialized cells
- **Differentiation** : Have the potential to give rise to specialized cell types
- **Proliferation & Renewal** : Capable of dividing and renewing themselves for long periods of time
- **Regeneration** : Potential to replace cell tissue that has been damaged or destroyed by severe illnesses, or age.

Two Kinds of Stem Cells

1. Hematopoietic Stem Cells
2. Mesenchymal Stem Cells

Two Categories:

- **Embryonic** stem cells are capable of developing into all the cell types of the body.
- **Adult** stem cells are less versatile and more difficult to identify, isolate, and purify.

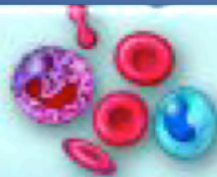
4 types of Stem Cells

Differentiation

- Totipotent
- Pluripotent
- Multipotent
- Unipotent



Pancreatic
(islet cells)



Hematopoietic
(blood cells)




Cardiomyocytes
(heart cells)



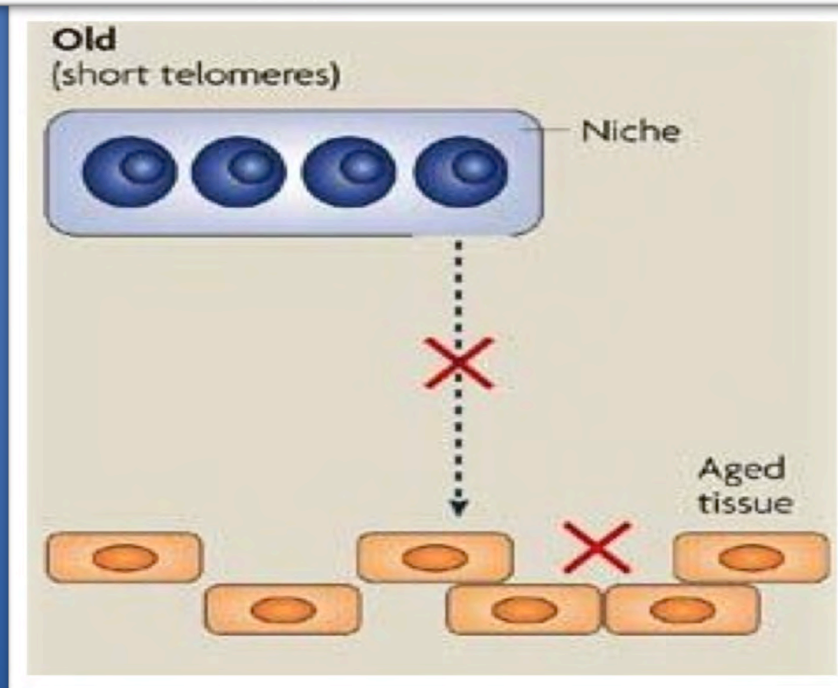
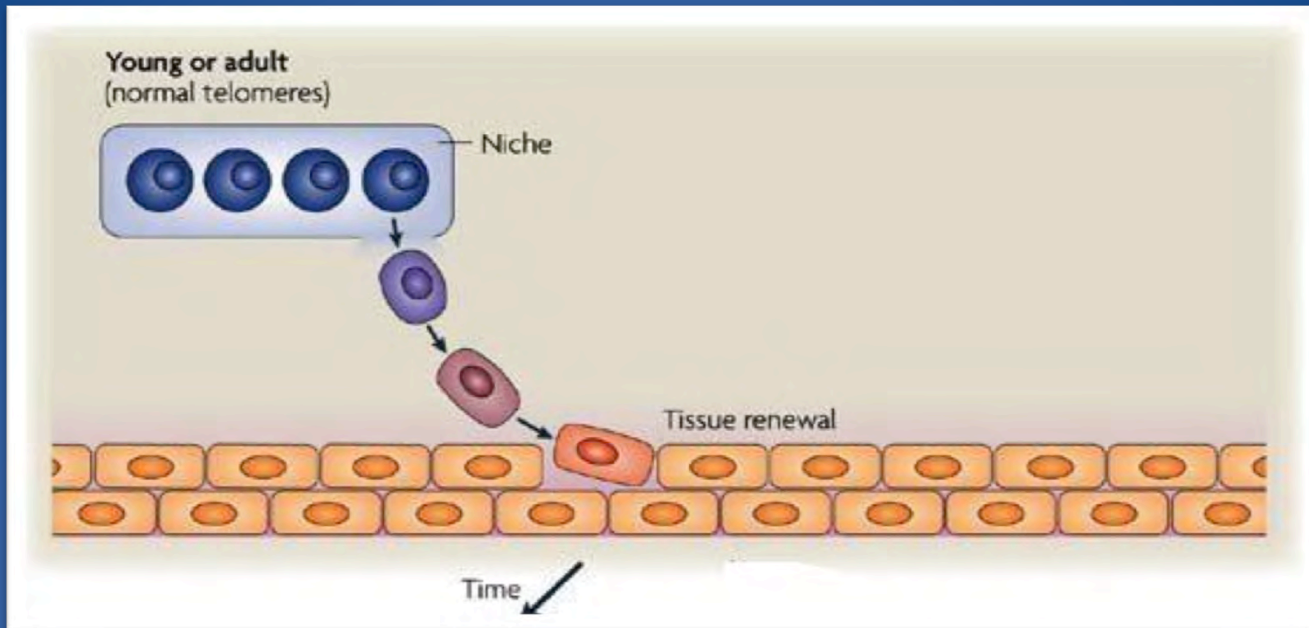
Neurons
(brain cells)



Hepatocytes
(liver cells)

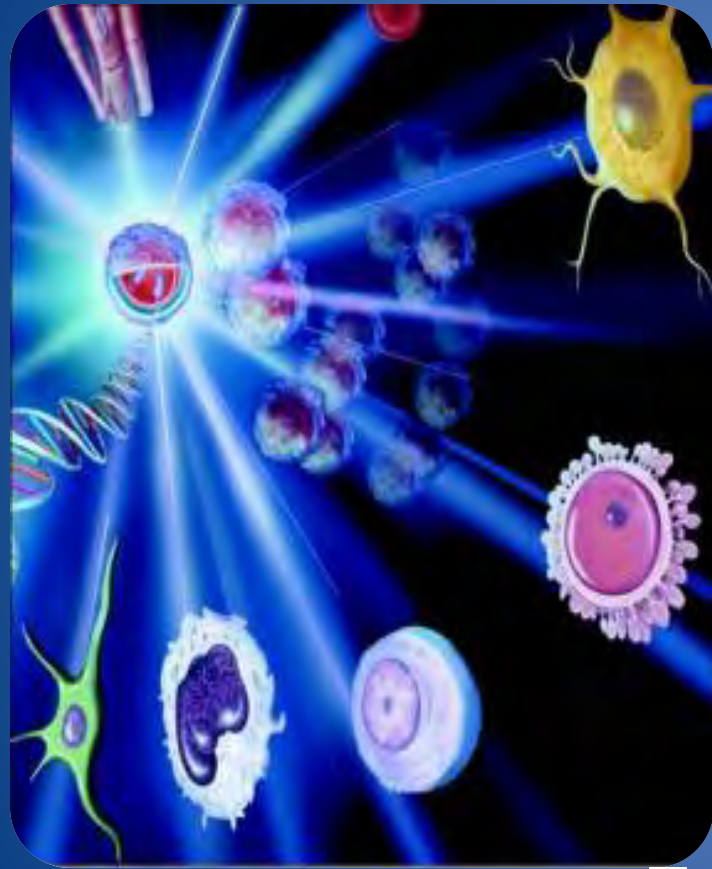


Dr. Ibrahim EL ACHKAR



Dr. Ibrahim EL ACHKAR

Stem Cells



Retournement
d'âge

Dr. İlbrathime E LAÇAKAR

Introduction

Liposculpture (Fat Graft) with Autologous fat graft is one of the safest, most durable and regenerative procedures of the face and body

Introduction

A. Fat Graft

- **Lipofilling or Lipostructure**

B. Adipose Stem Cells (ASC)

- **Stromal vascular fraction (SVF) harboring ASCs /*Adipose-Derived Stem & Regenerative Cells (ADRCs)***



C. Fat Tissue & ASC

- **May increase longevity & quality of fat graft**

Methods and Material

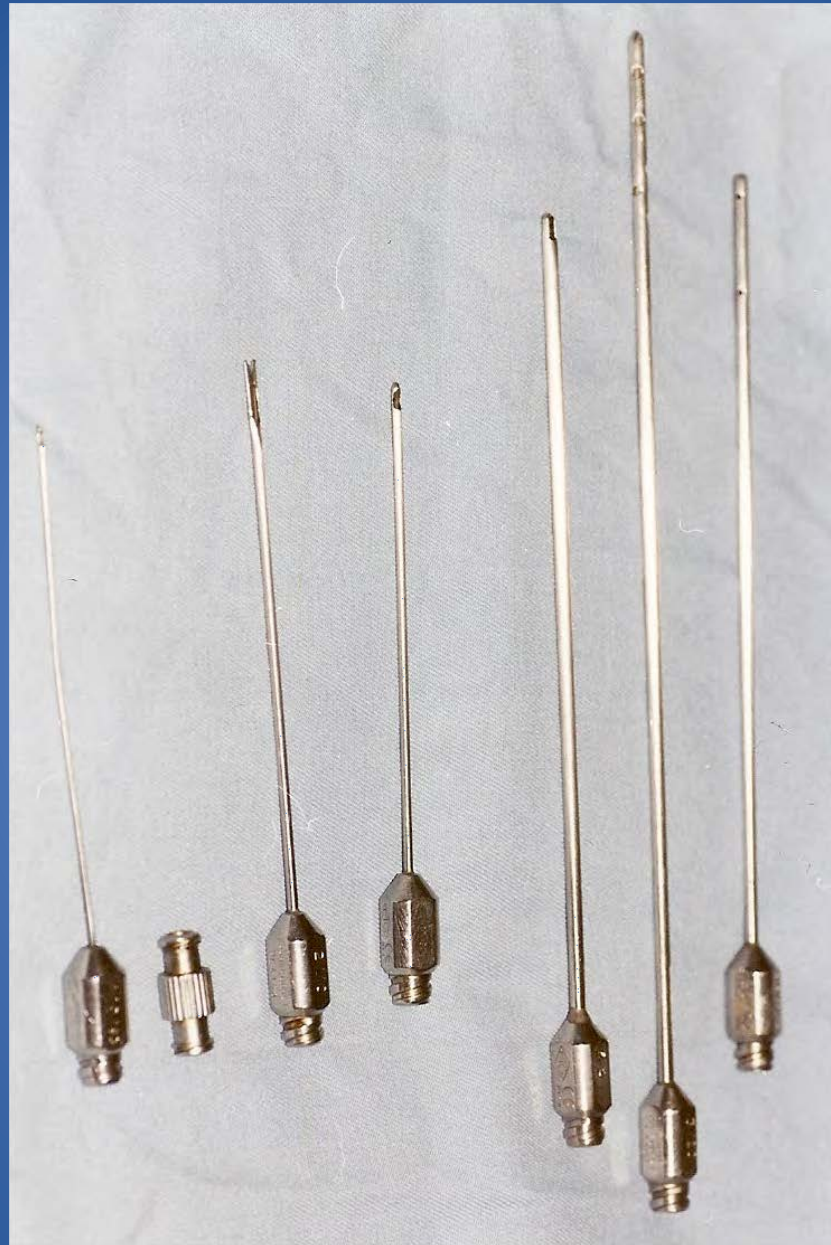- Between January 2000 and 2010:
5,200 patients have been treated with Liposculpture.
- Between 2011 and 2012:
10 patients have been treated with ADRCs “Adipose-Derived Stem & Regenerative Cells”
20 patients have been treated with fat enriched Stem Cells.

A. Fat Graft

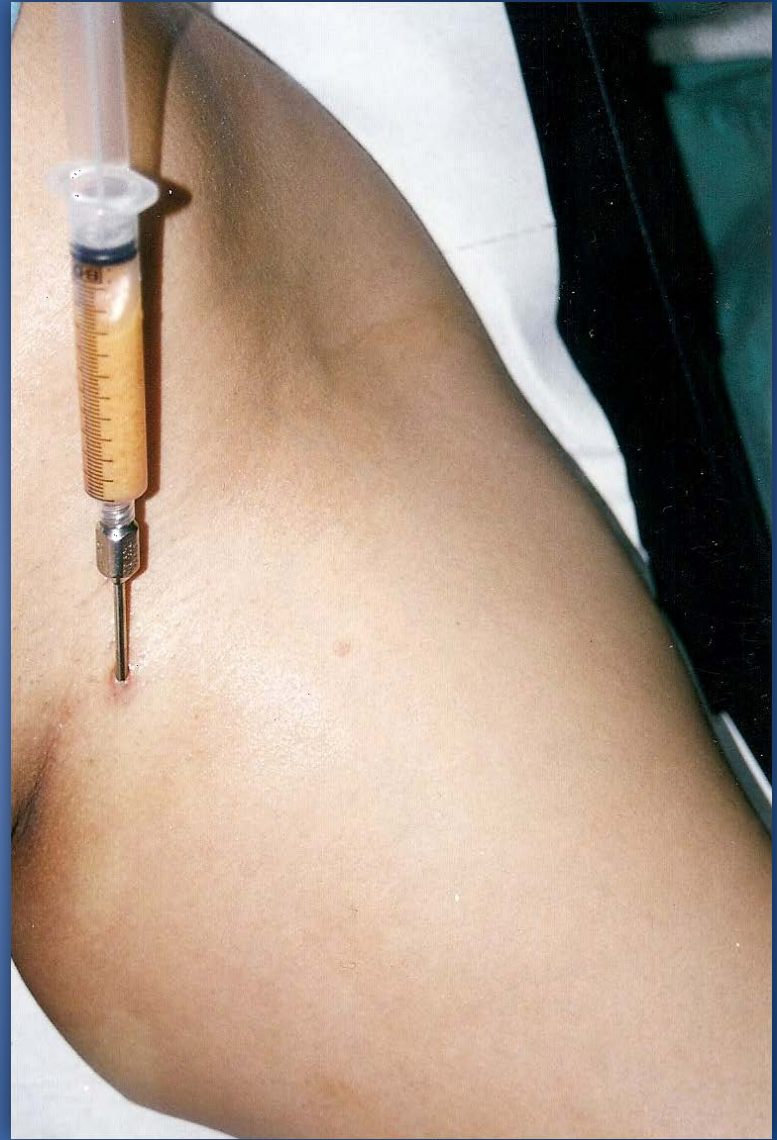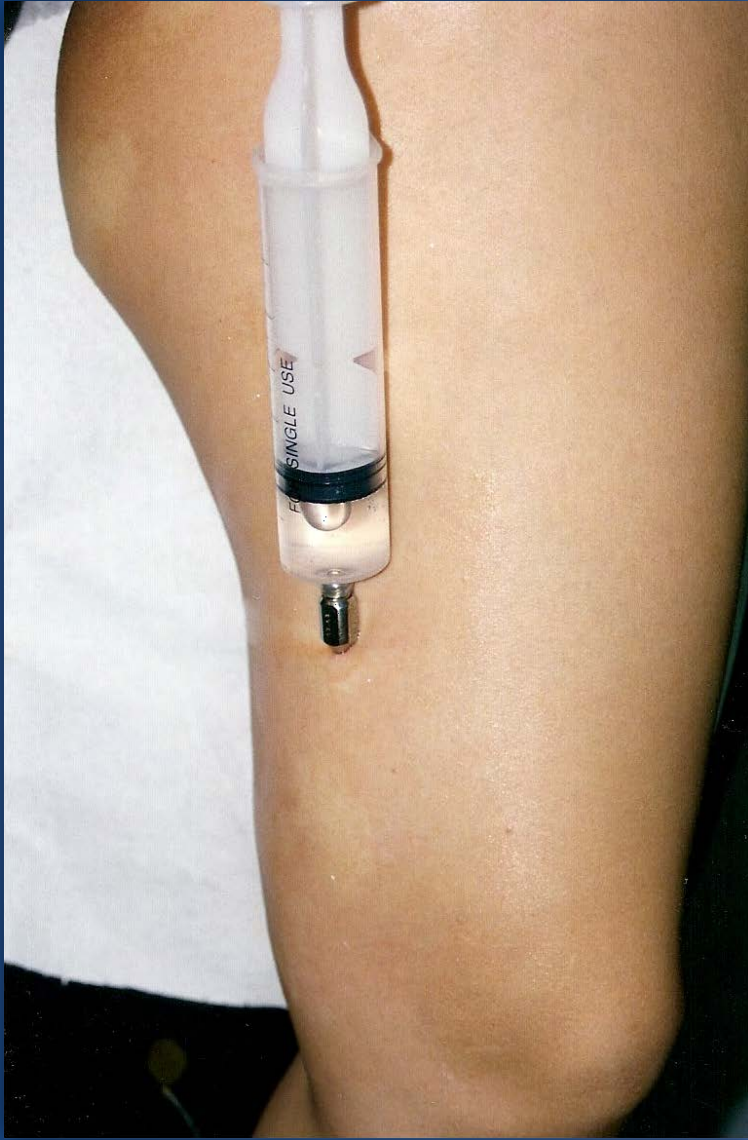


Operative procedure:

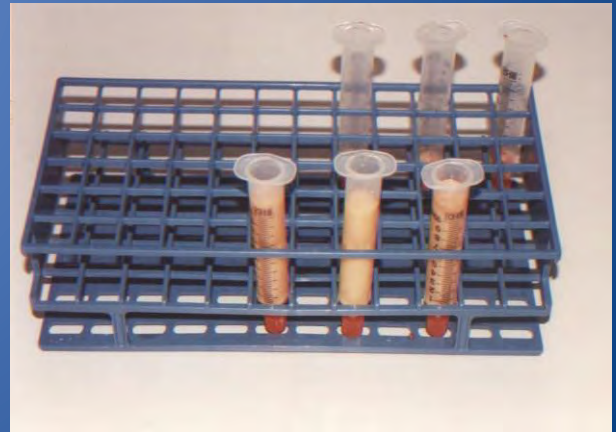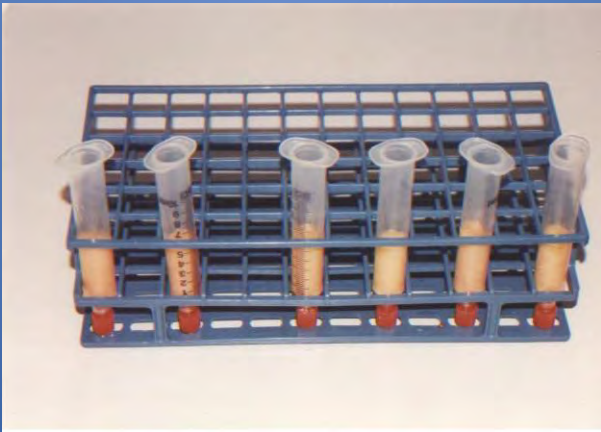
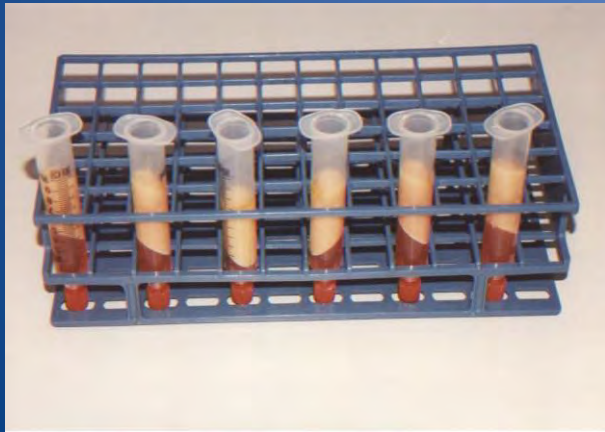

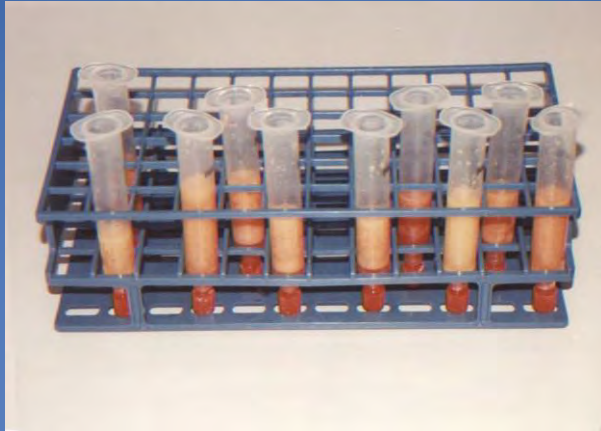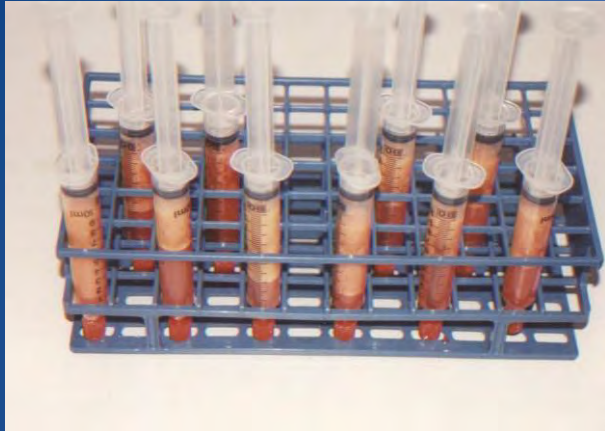- Local anaesthesia of the donor region with physiologic serum and xylo-adrenalin (1%): ratio 1/100
- Manual liposuction of donor zone: 10cc BD syringes
- Centrifugation at 3000t/min; for 3 minutes
- Taking off pure fat with 1cc syringe
- Injection of pure fat via 1cc syringe via 1mm canule within the receptive zones


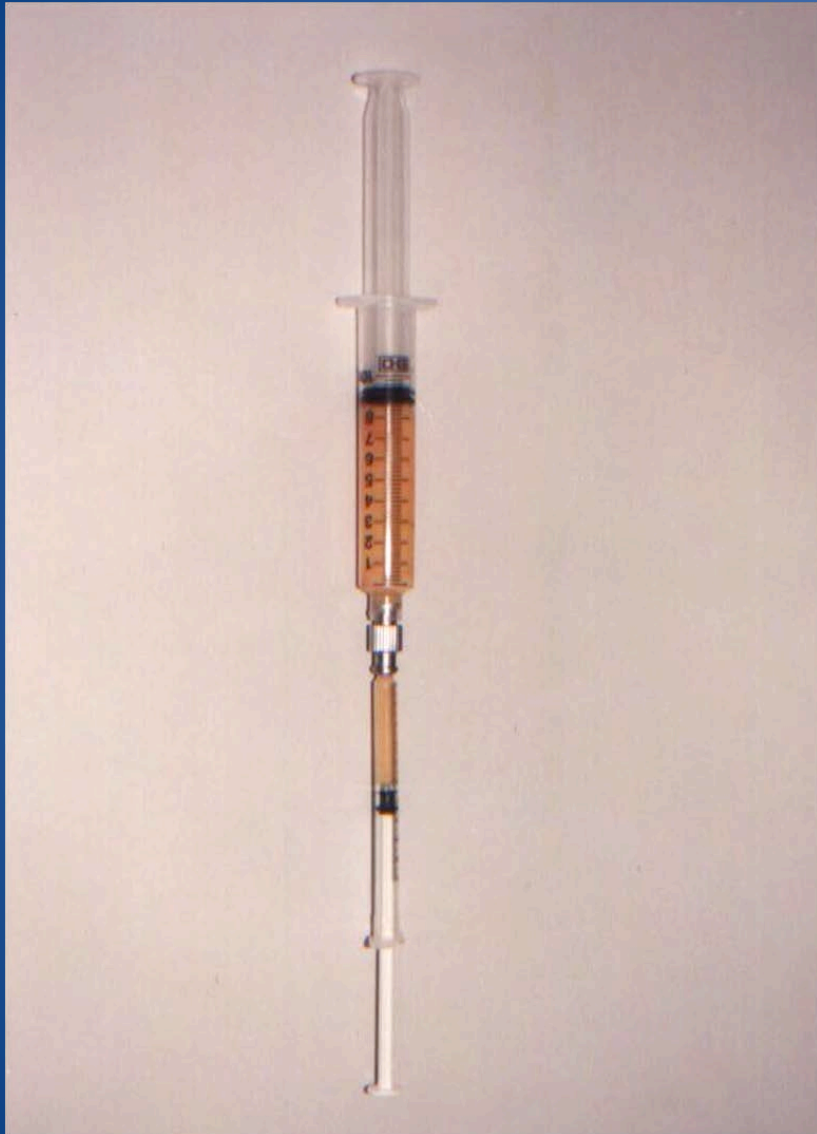


Dr. Ibrahim EL ACHKAR

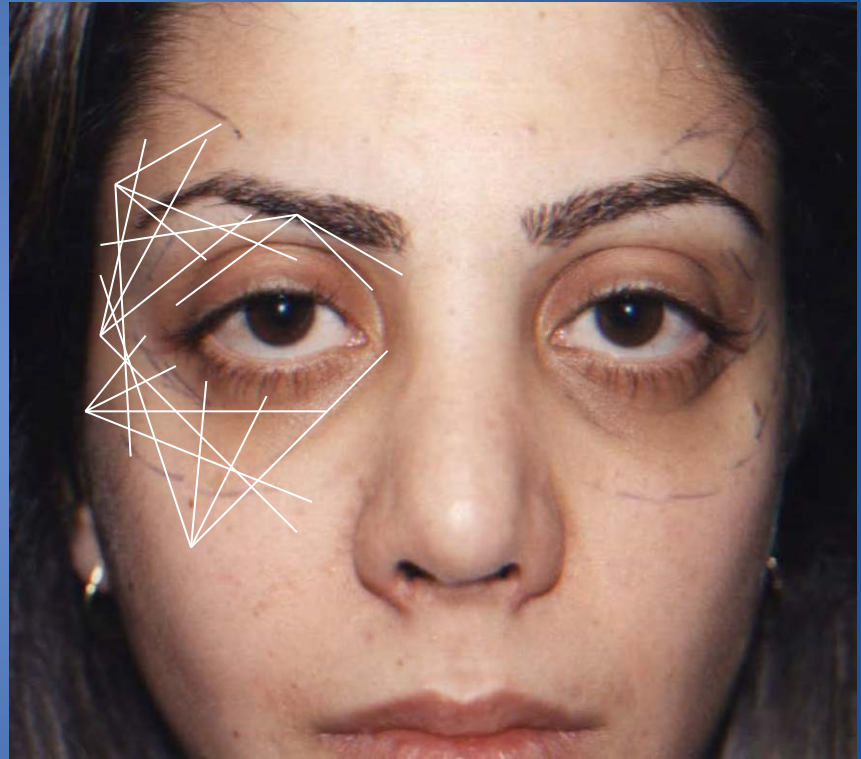
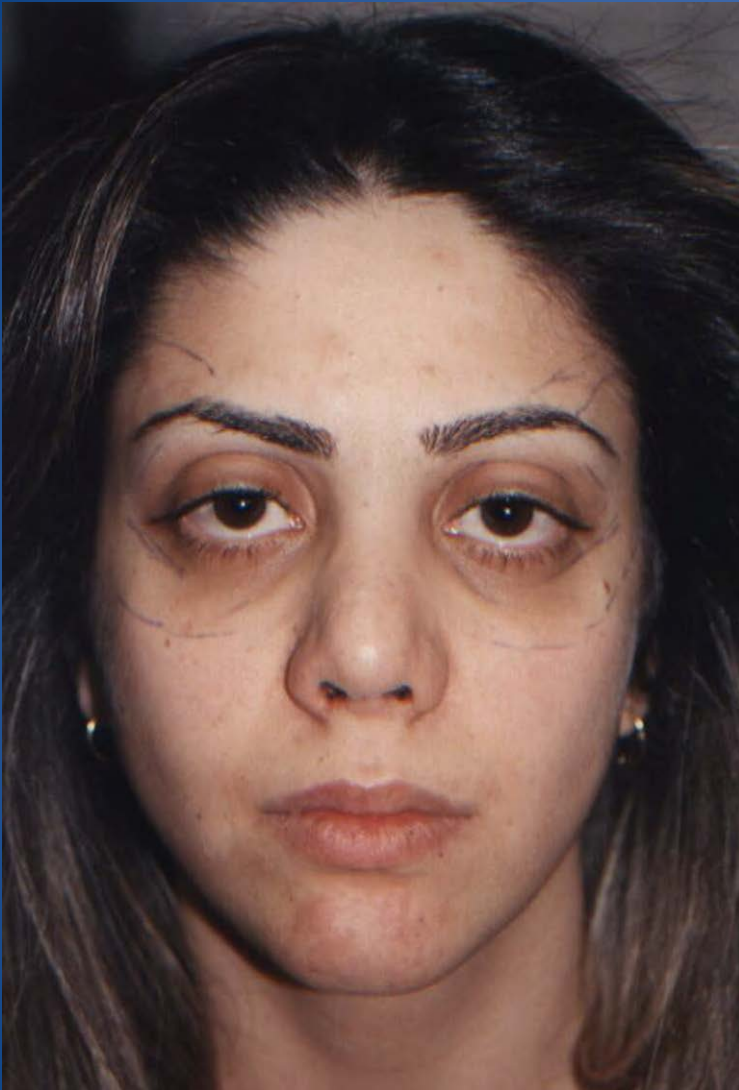
Dr. Ibrahim EL ACHKAR

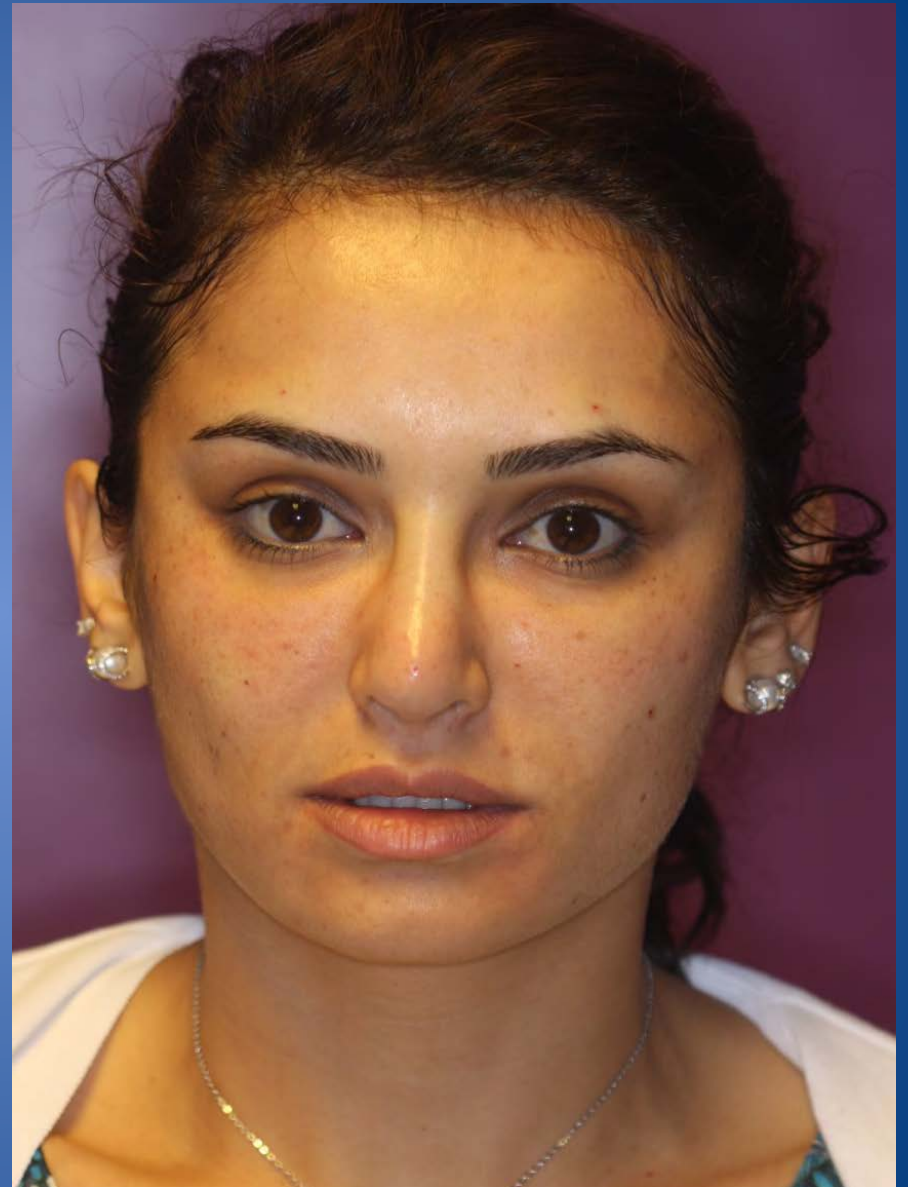




Dr. Ibrahim EL ACHKAR



Dr. Ibrahim EL ACHKAR



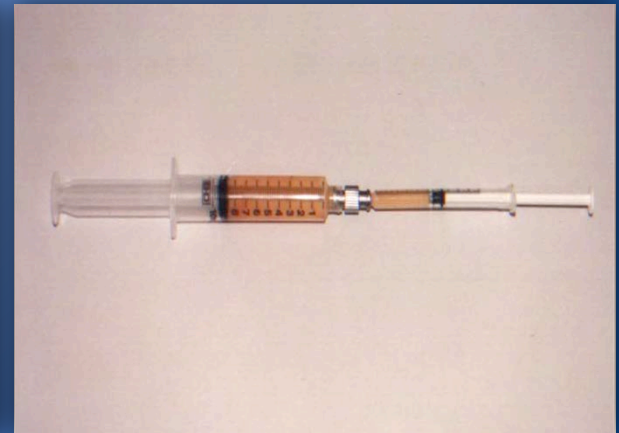
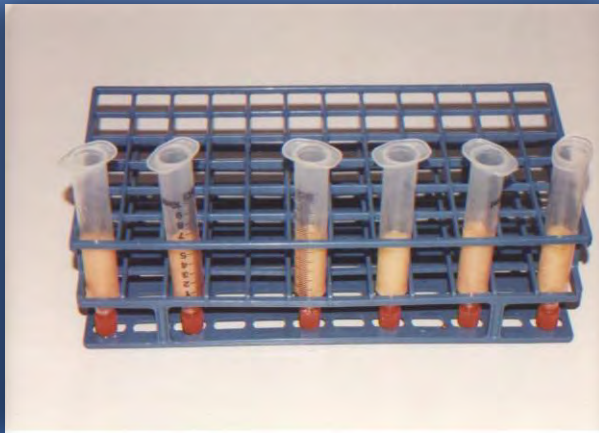
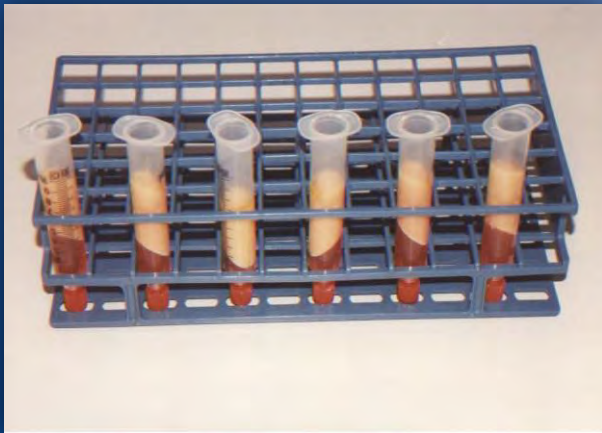
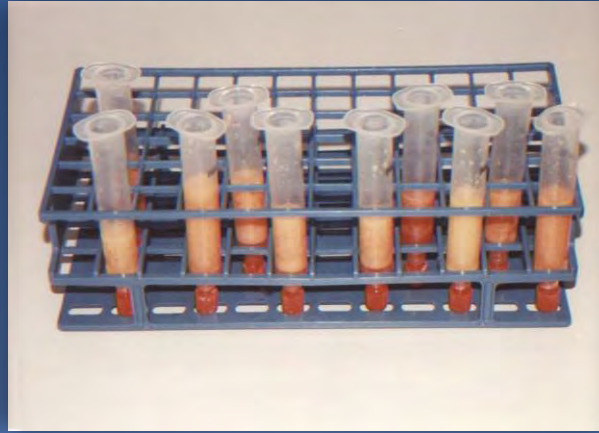
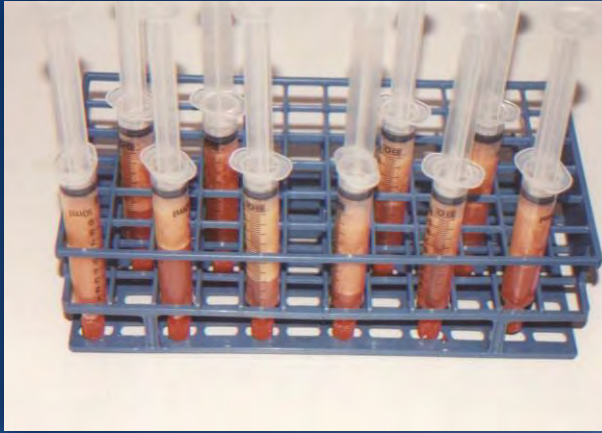Dr. Ibrahim EL ACHKAR



Dr. Ibrahim EL ACHKAR

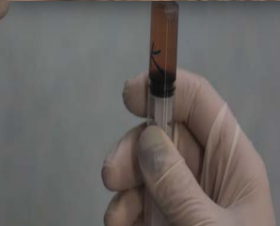
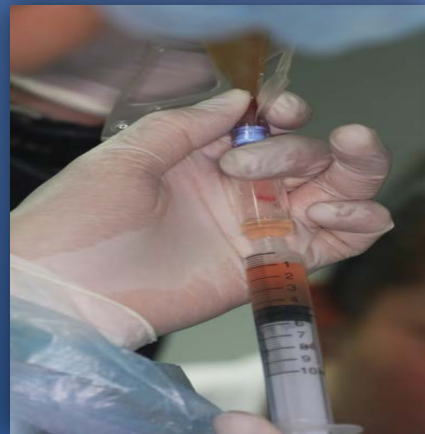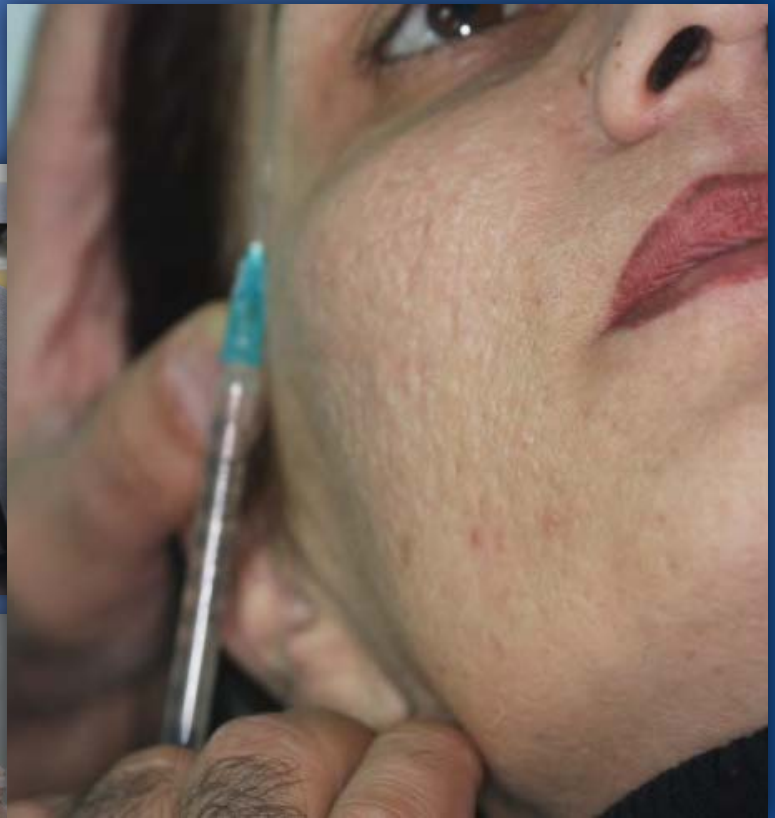

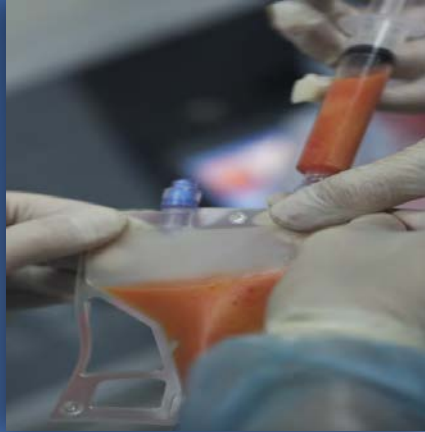
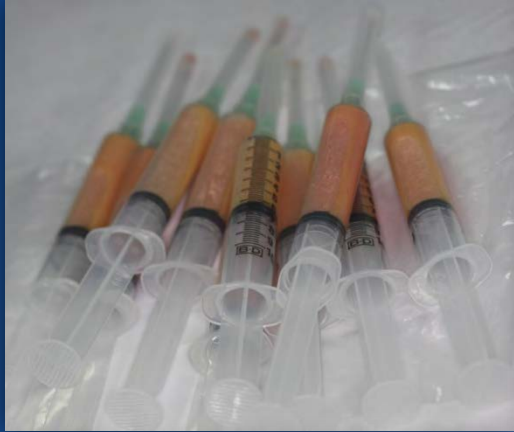
Dr. Ibrahim EL ACHKAR



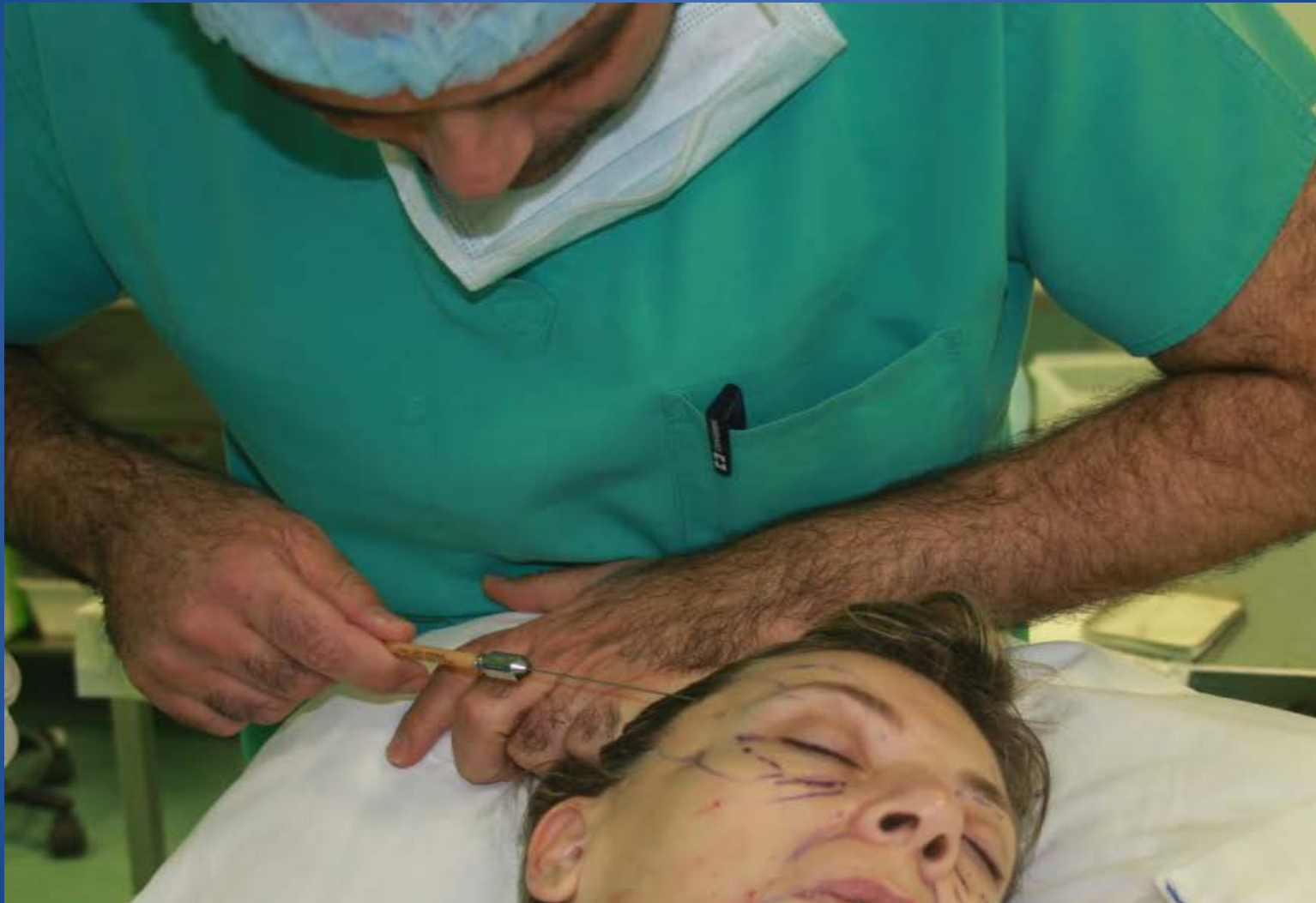Dr. Ibrahim EL ACHKAR

b. SVF injection



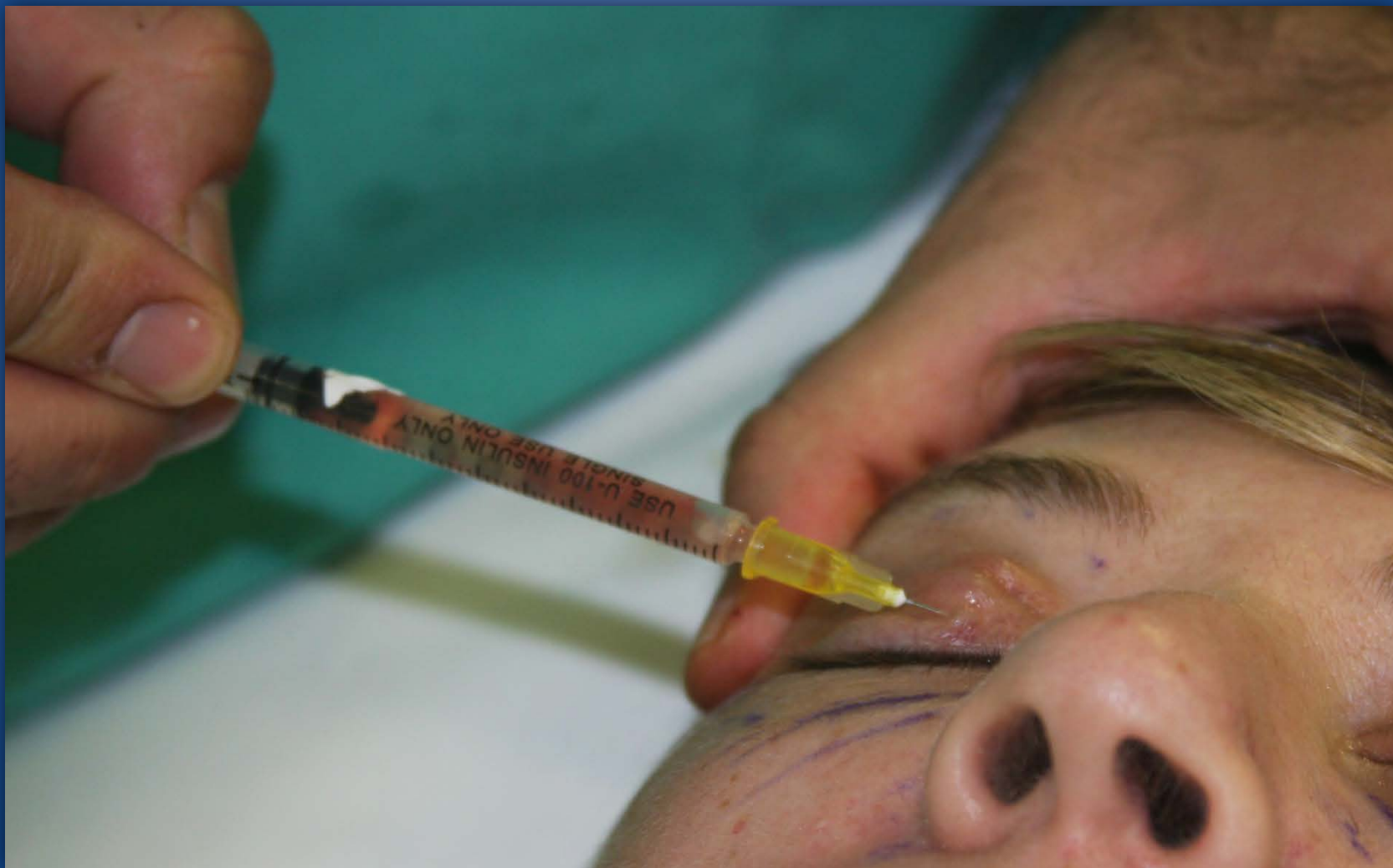Dr. Ibrahim EL ACHKAR

C. FAT + SVF



Dr. Ibrahim EL ACHKAR

C. FAT + SVF



Dr. Ibrahim EL ACHKAR

Clinical application

Face:

I. Oritopalpebral zone

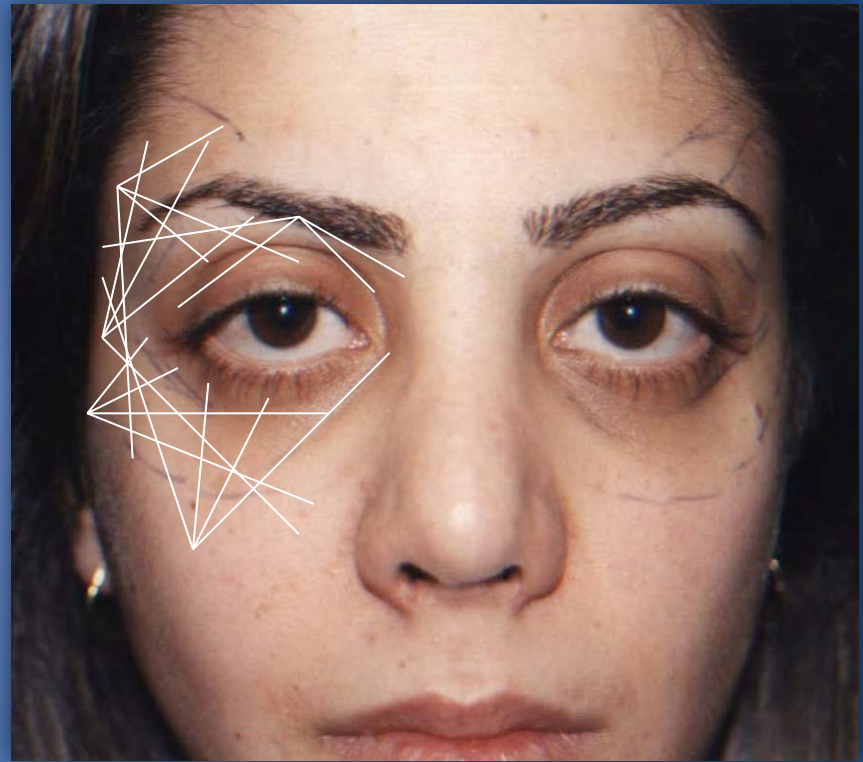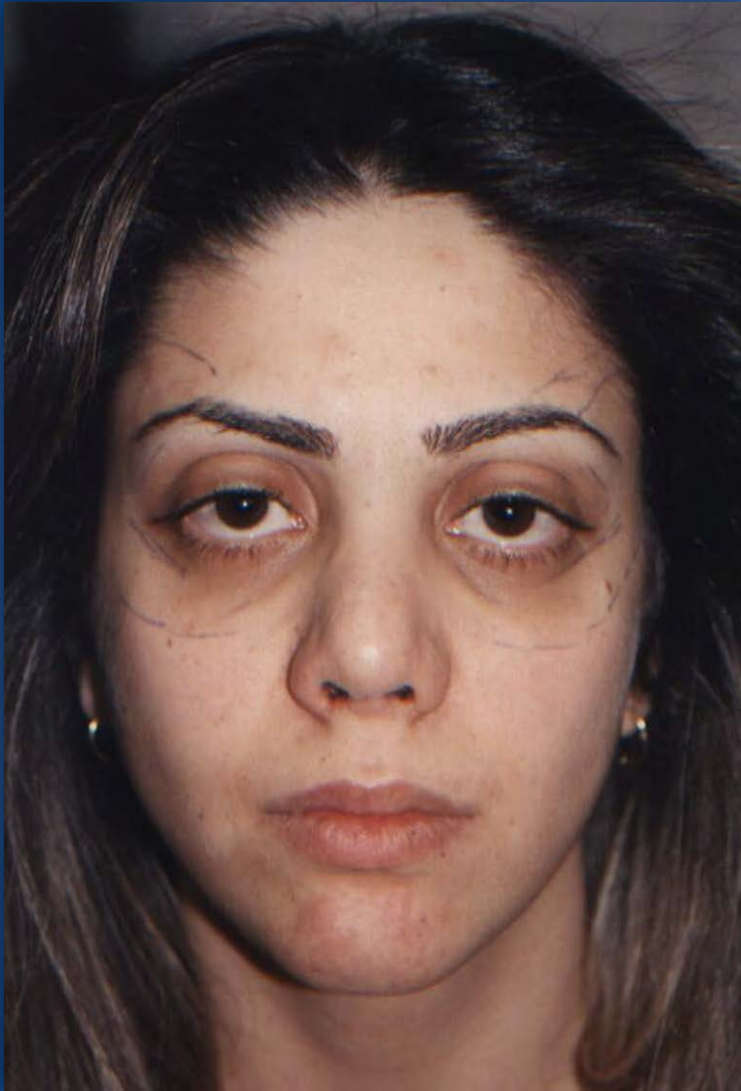- Temporal
- Eyebrows
- Eyelids
- Lachrymal grooves

II. Mid face

- Cheeks
- Nose
- Noso labial folds

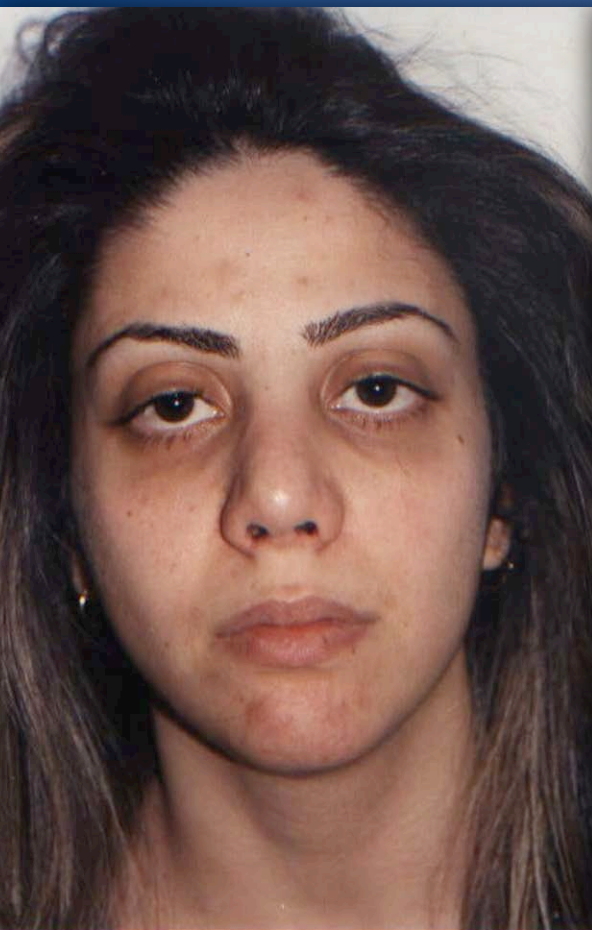
III. Lower face

- Lips
- Labial comissure
- chin

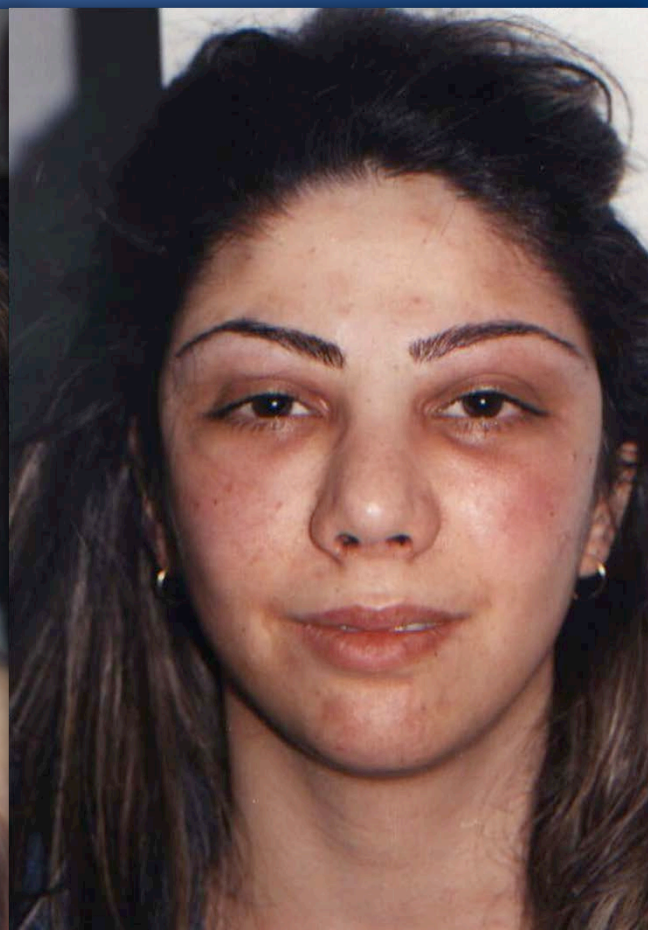
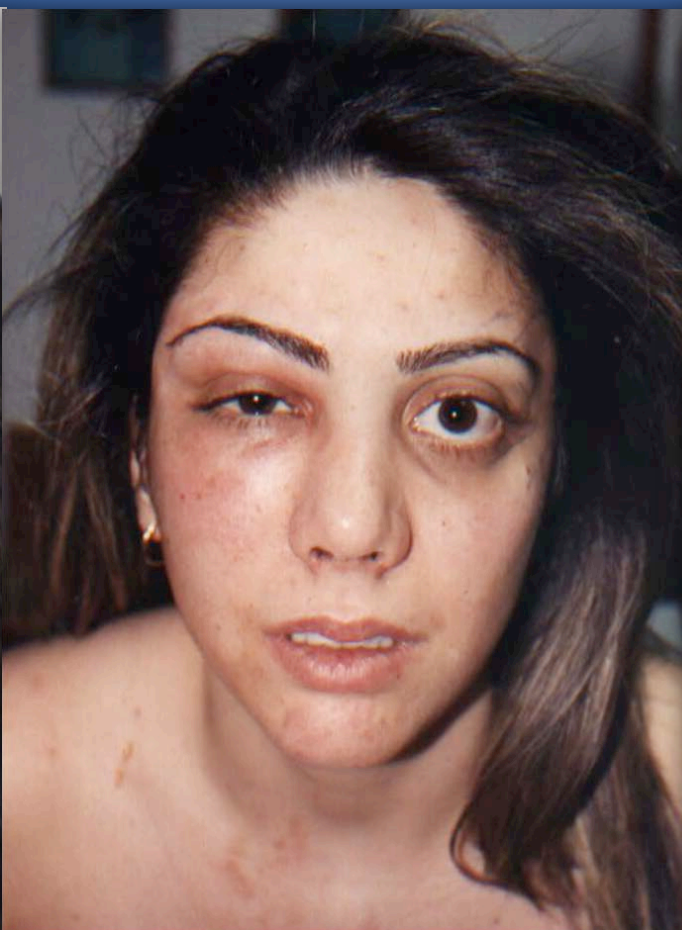
Dr. Ibrahim EL ACHKAR

Before



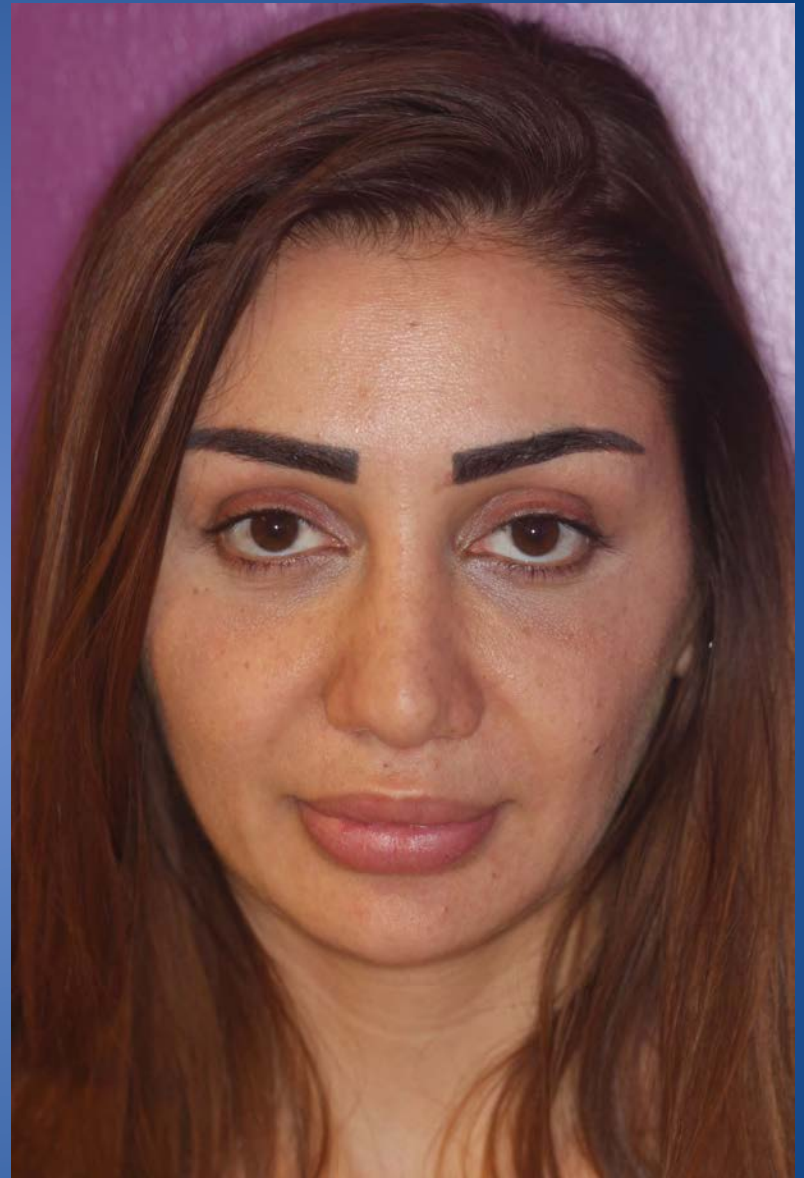
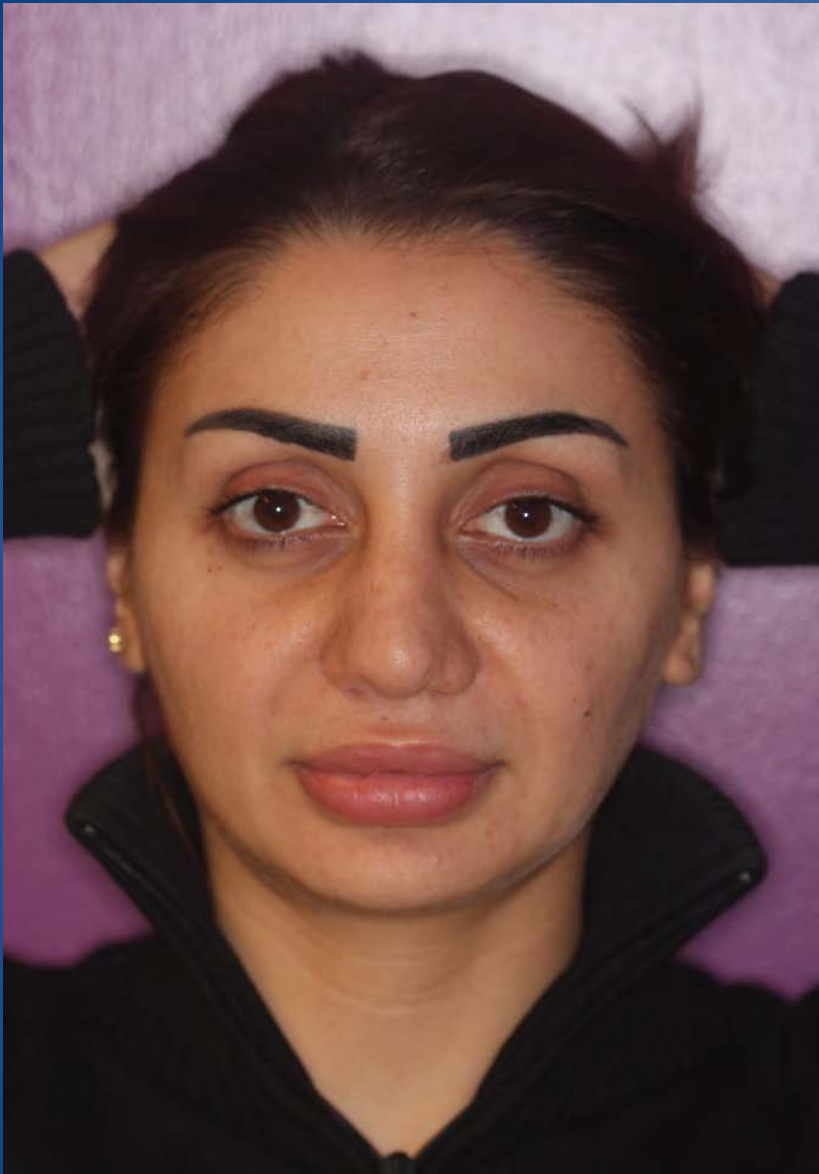After



Dr. Ibrahim EL ACHKAR



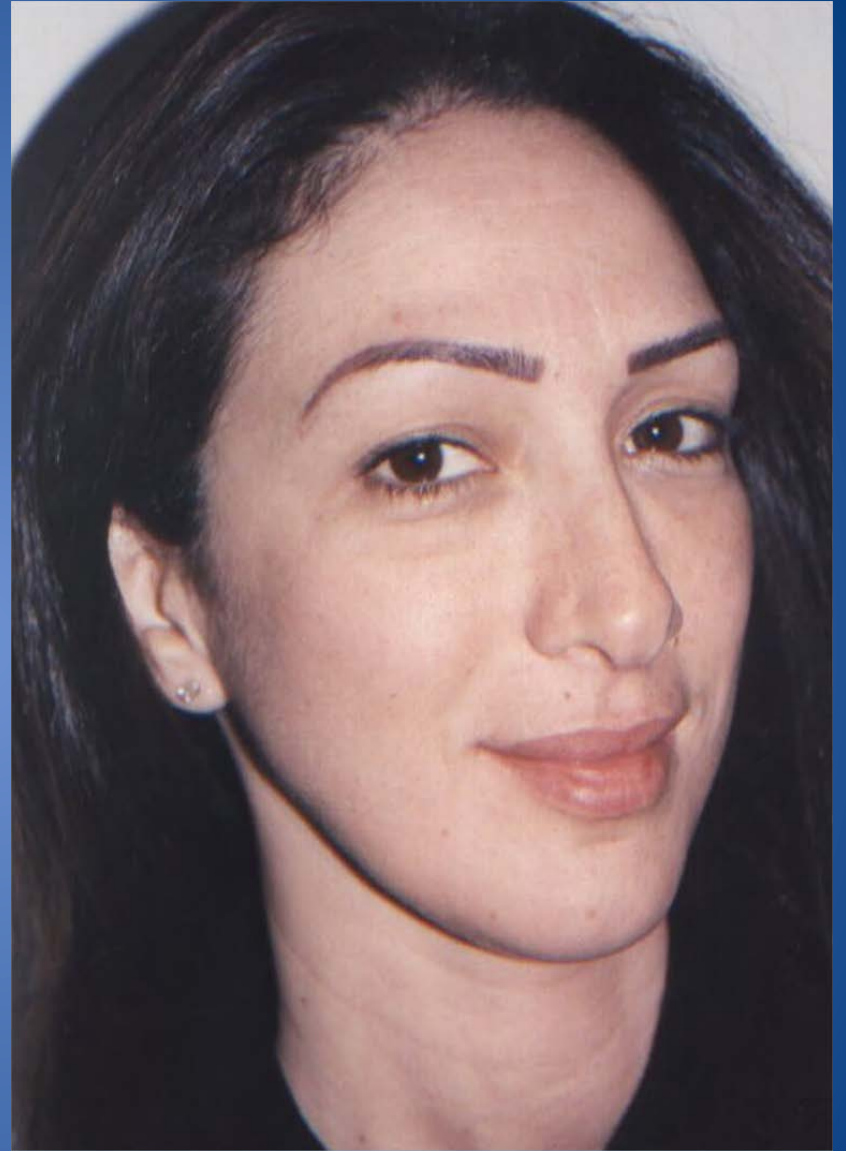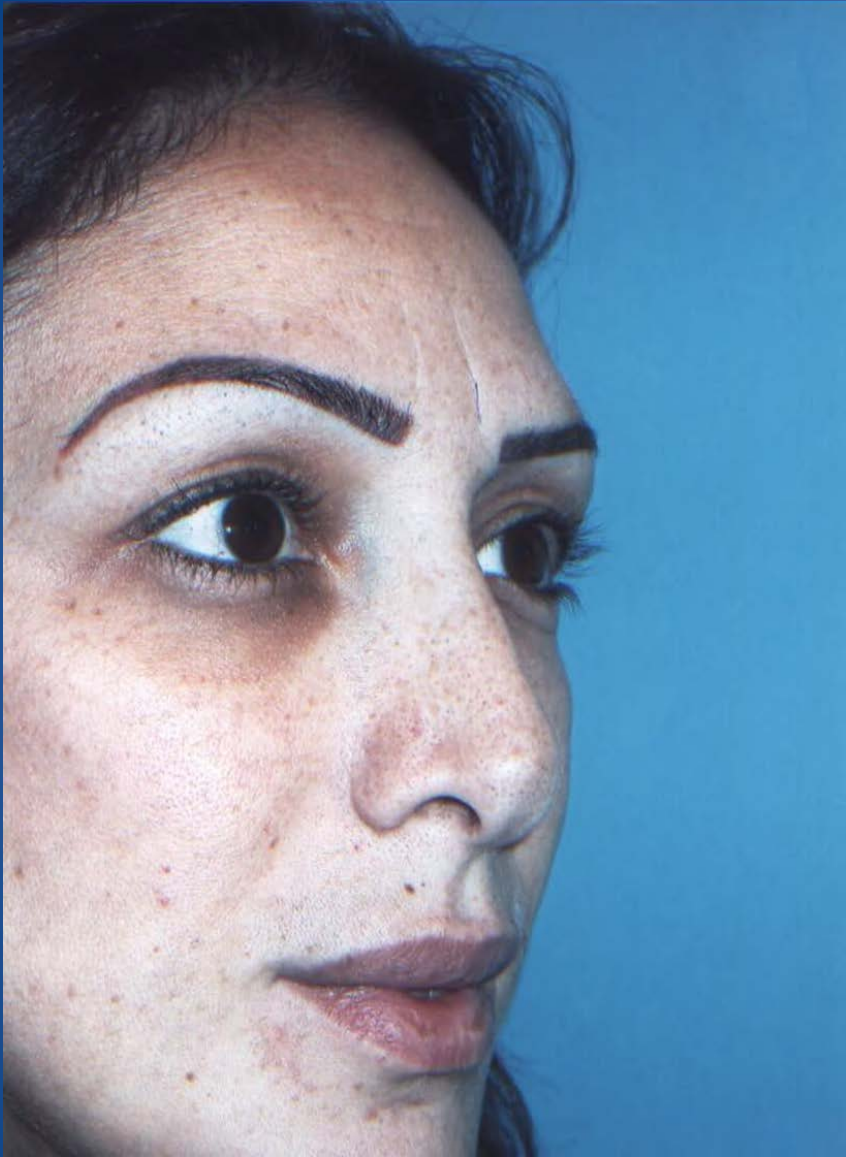Dr. Ibrahim EL ACHKAR



Dr. Ibrahim EL ACHKAR

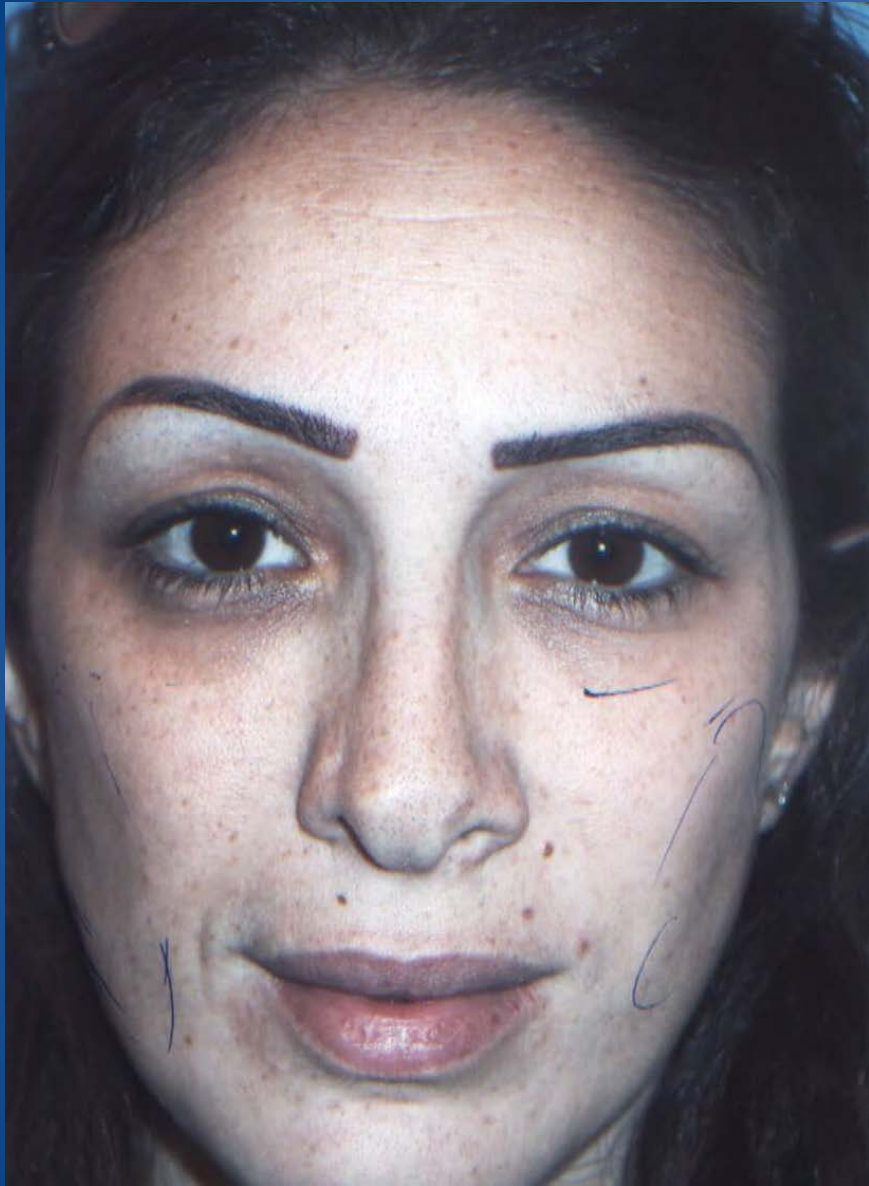Before

After



Dr. Ibrahim EL ACHKAR

Before

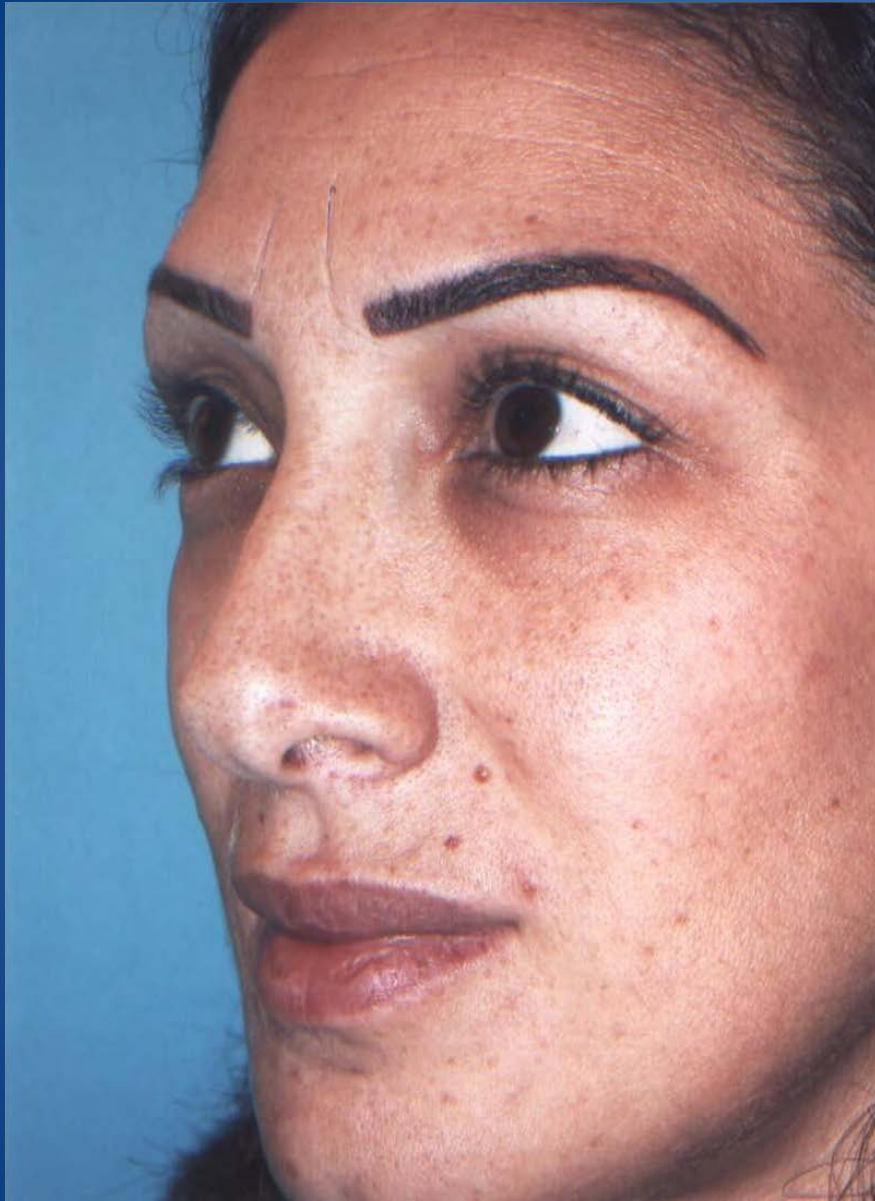

After

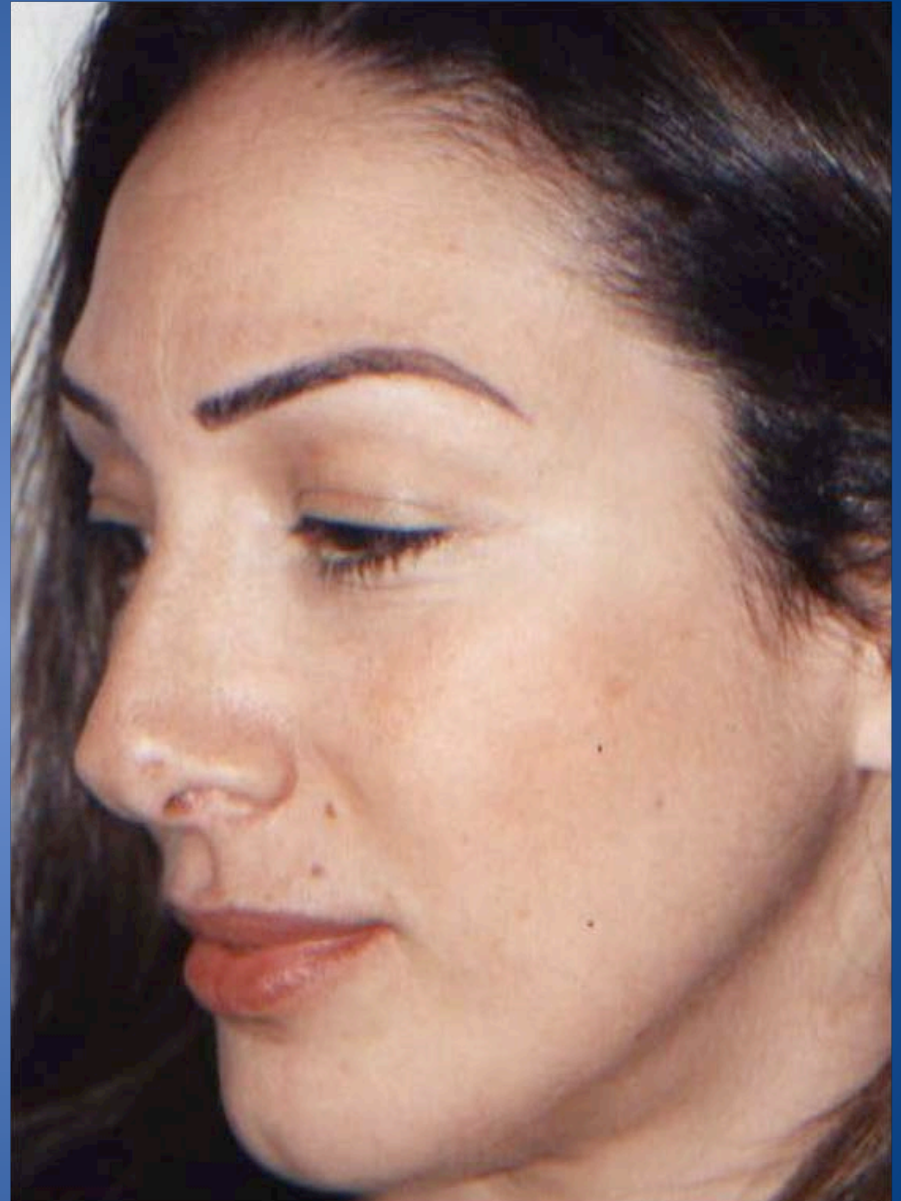

Dr. Ibrahim EL ACHKAR

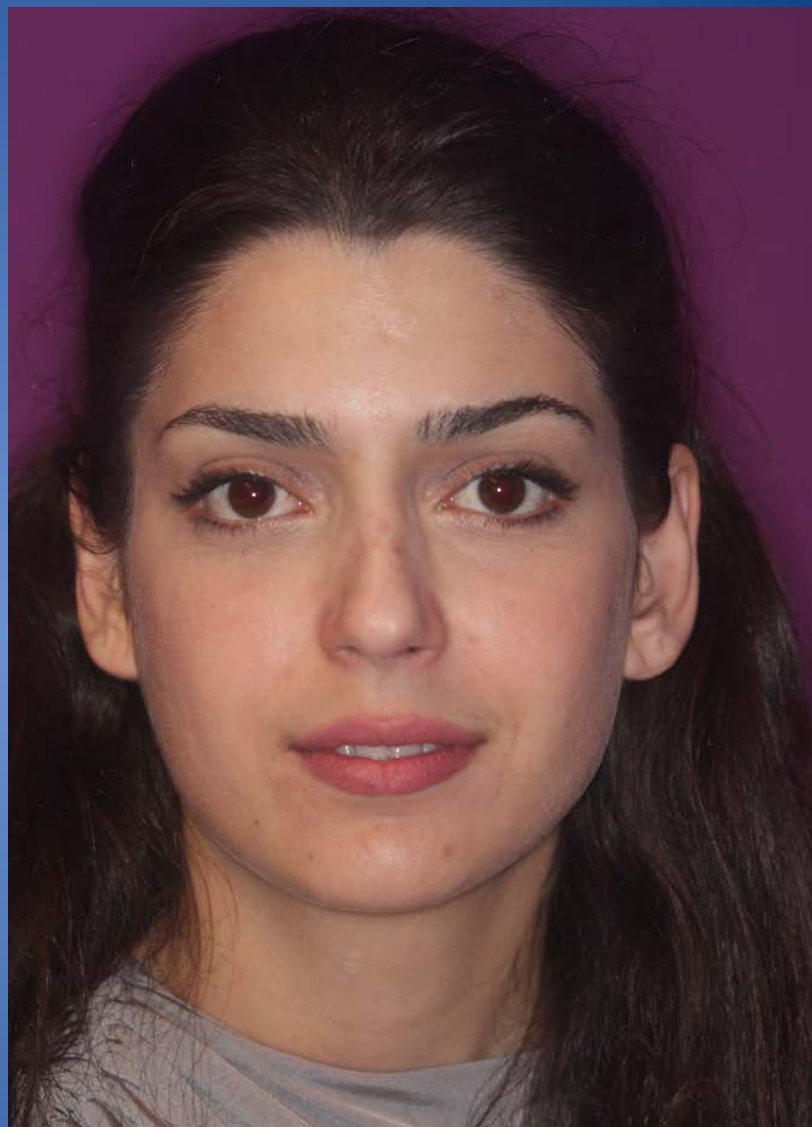Before



After

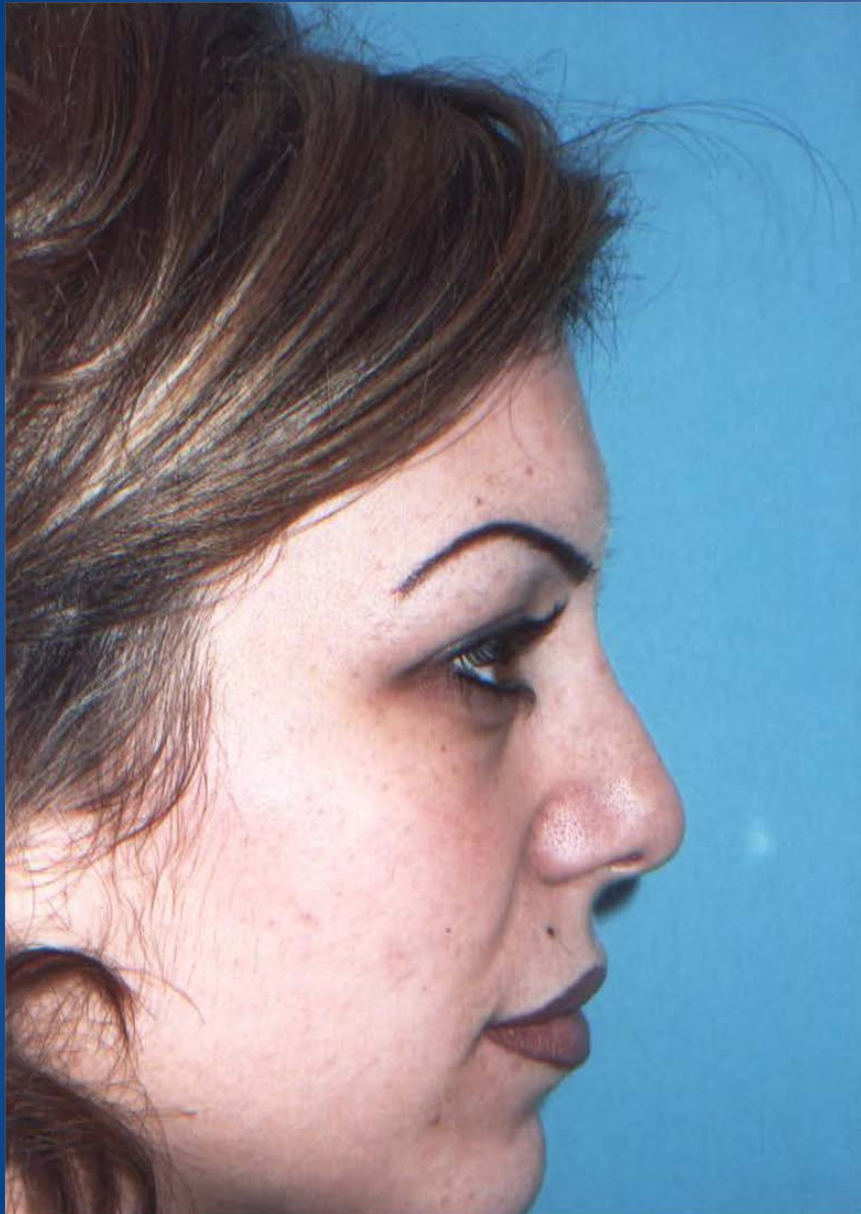

Dr. Ibrahim EL ACHKAR




Dr. Ibrahim EL ACHKAR

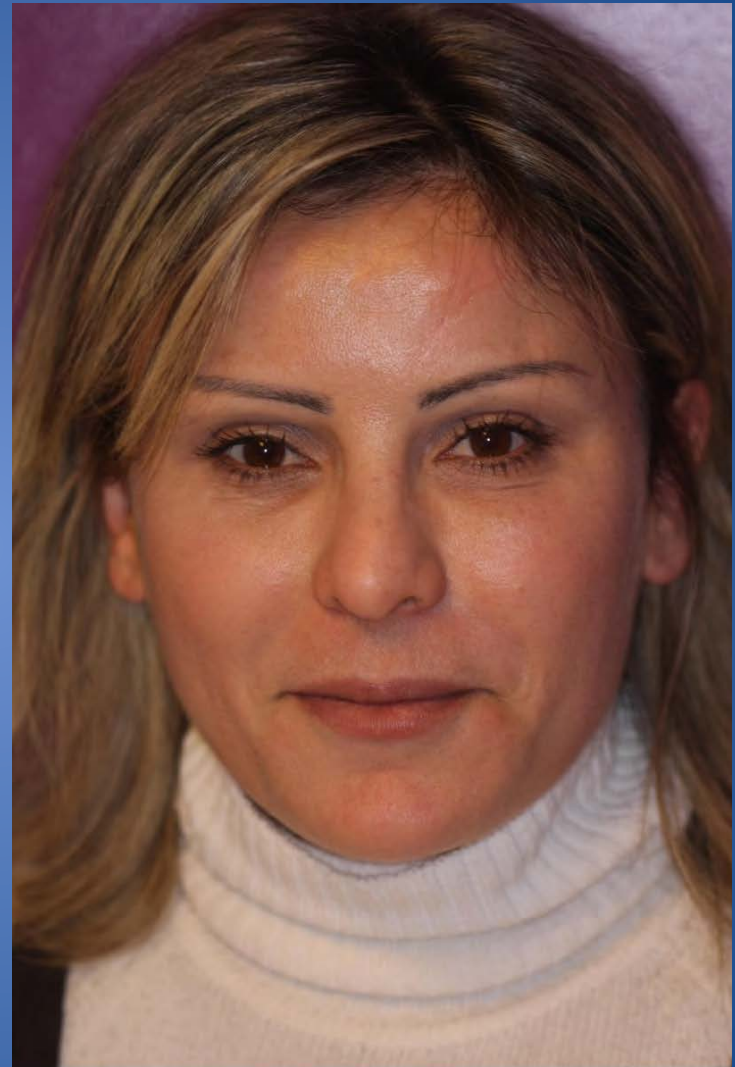
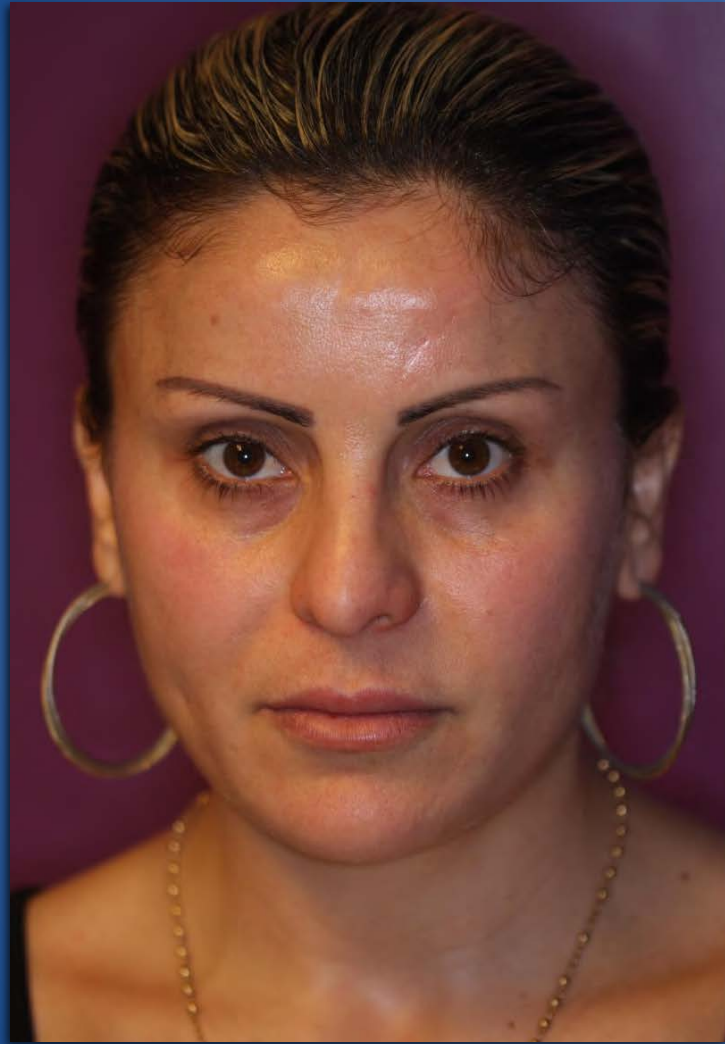
Before



After



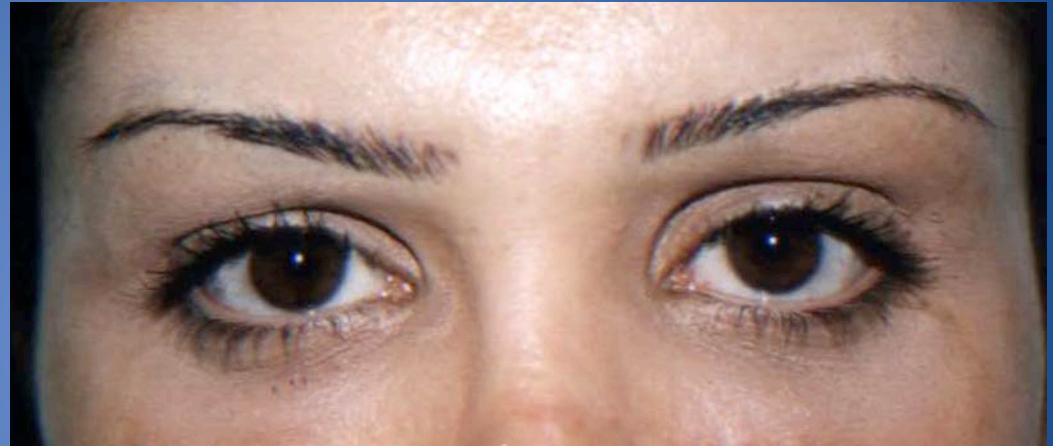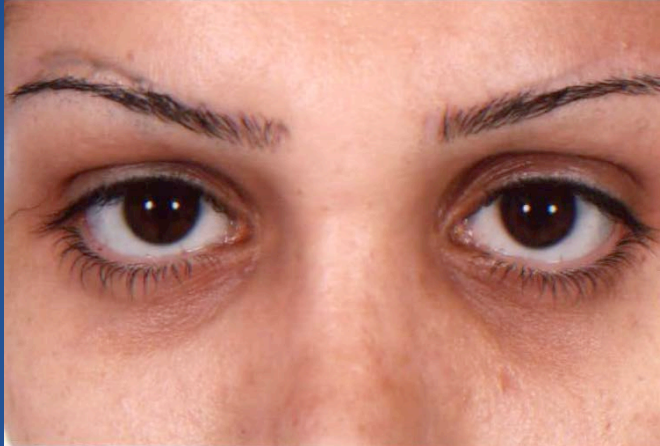Dr. Ibrahim EL ACHKAR



Dr. Ibrahim EL ACHKAR

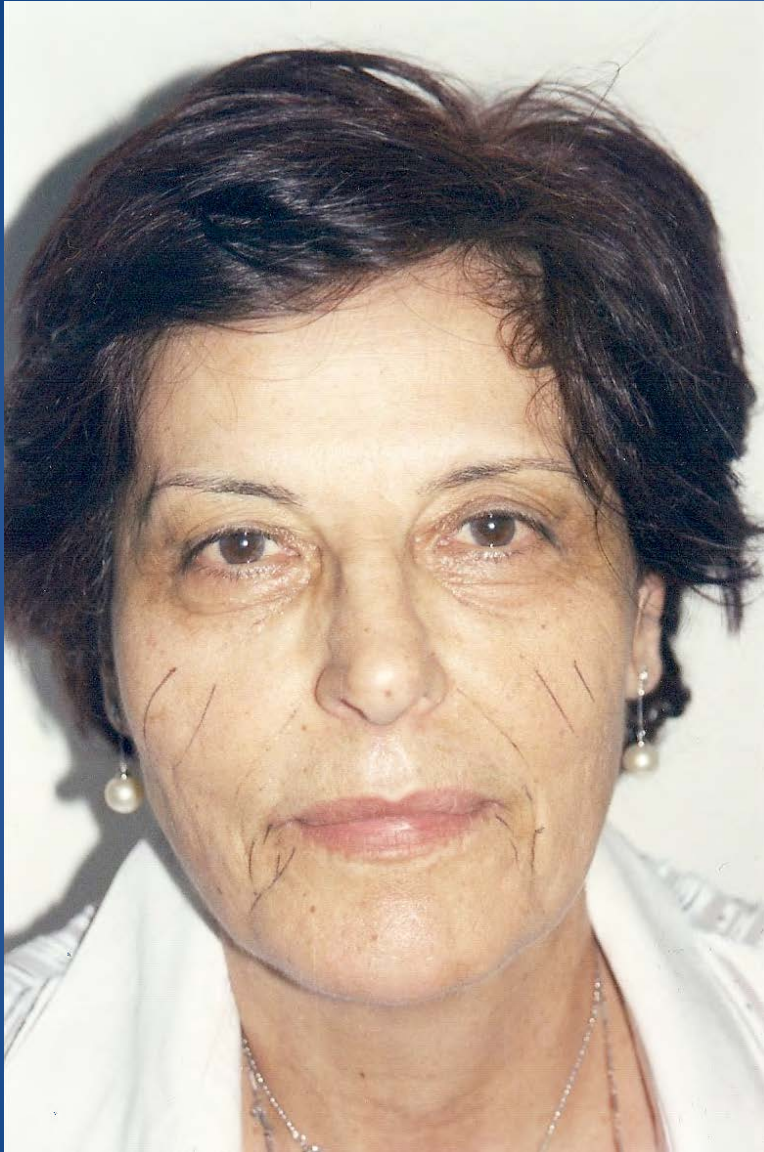
Before

After



Dr. Ibrahim EL ACHKAR

Before

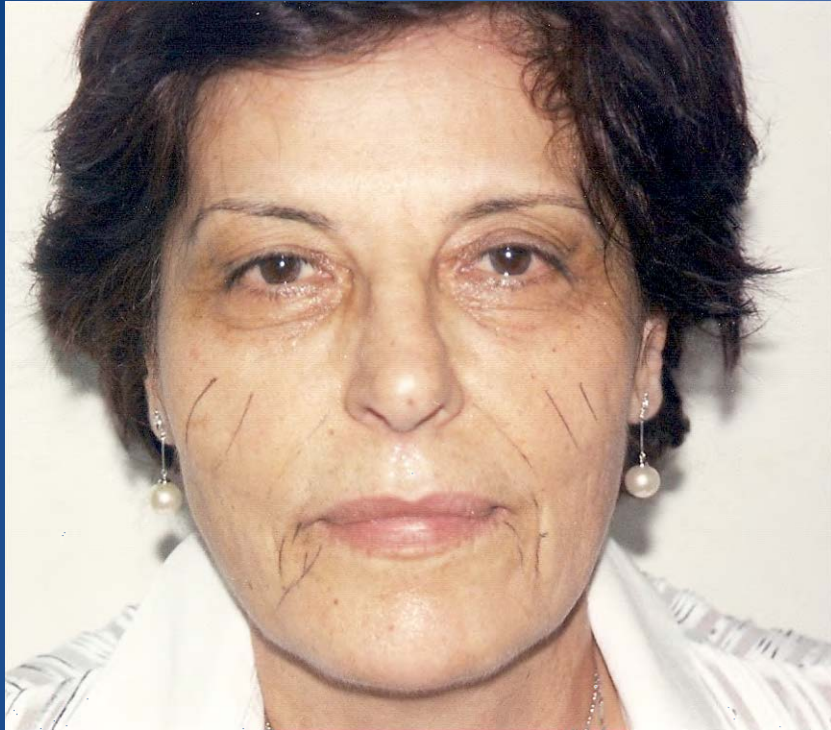

After

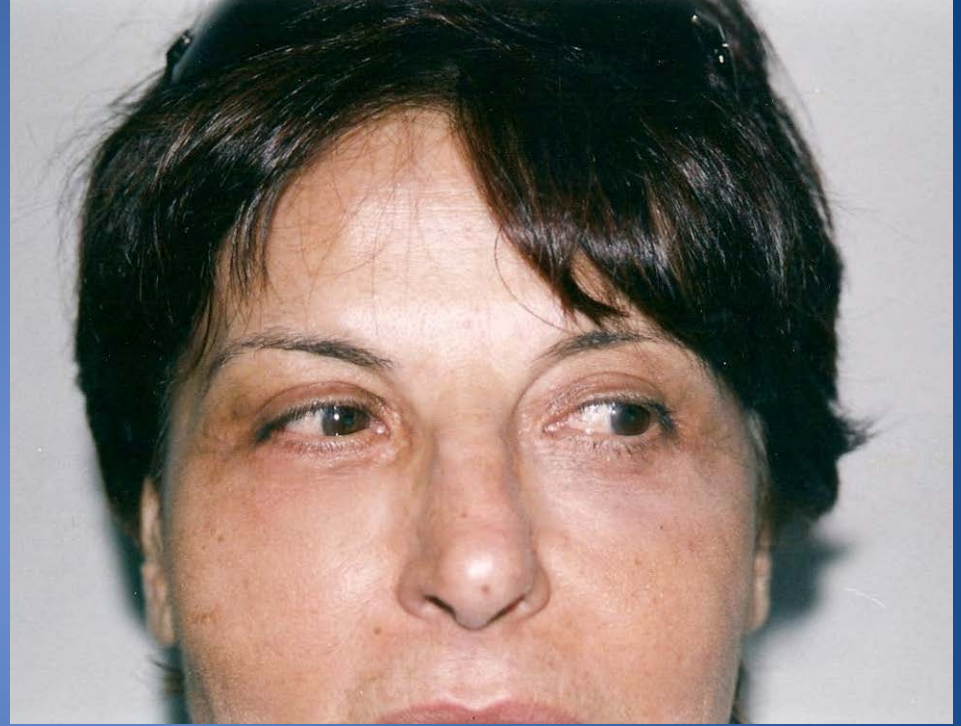

Dr. Ibrahim EL ACHKAR

Before



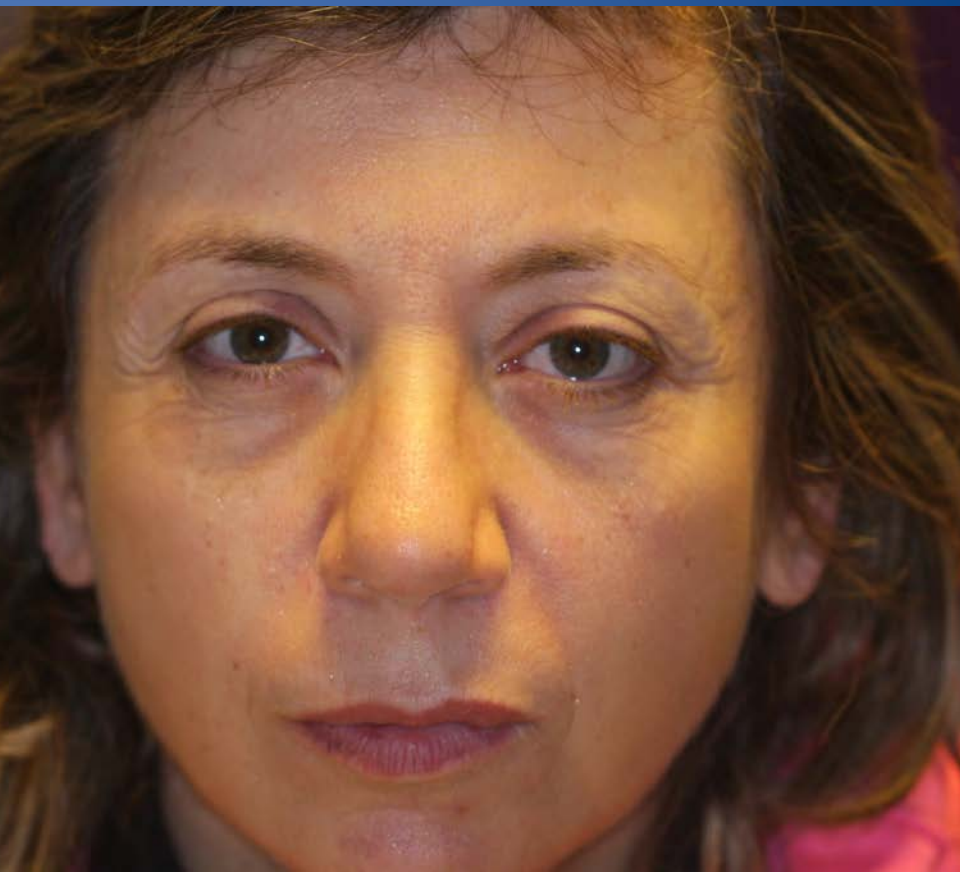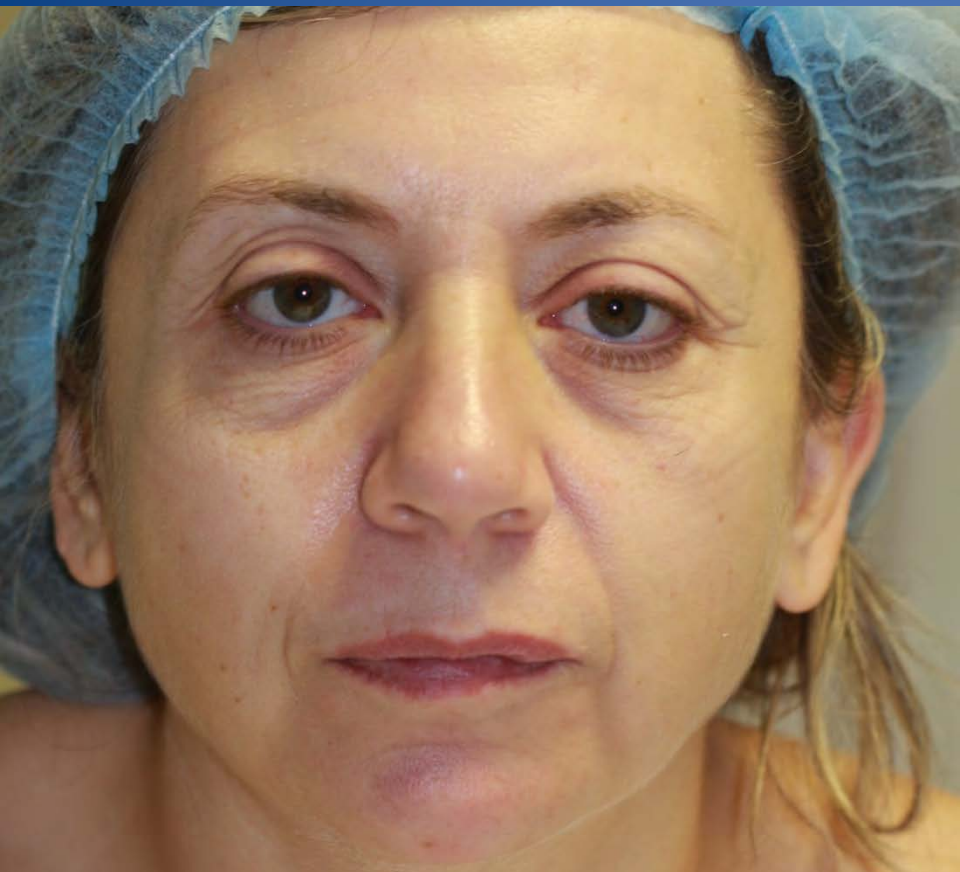
After



Dr. Ibrahim EL ACHKAR

Before

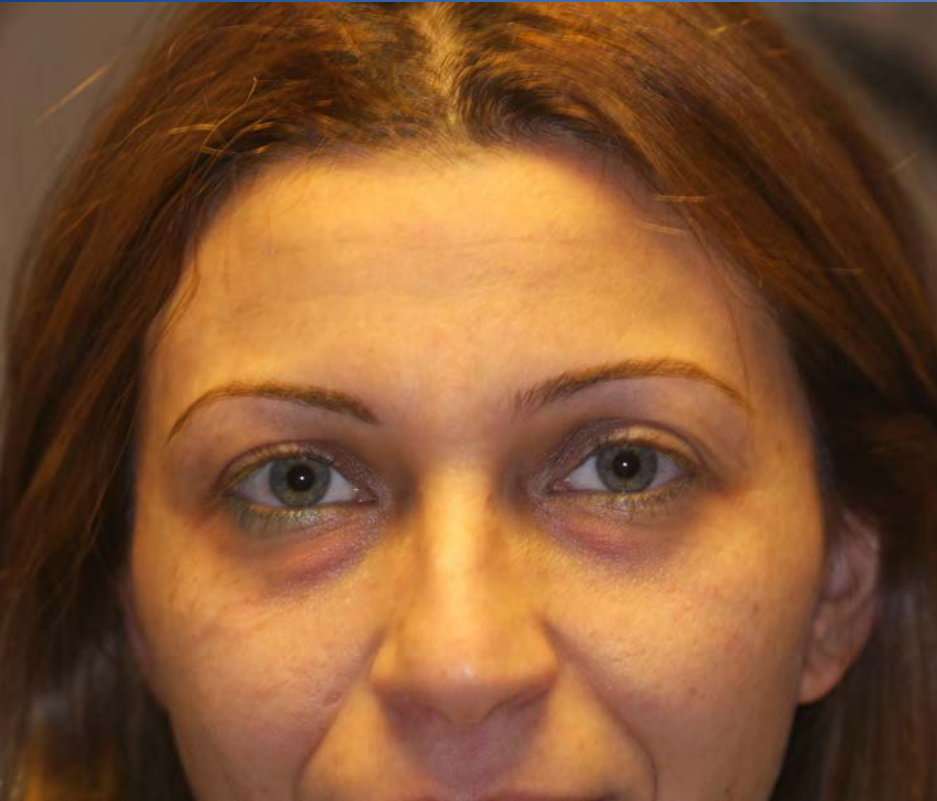
After



Dr. Ibrahim EL ACHKAR

Before

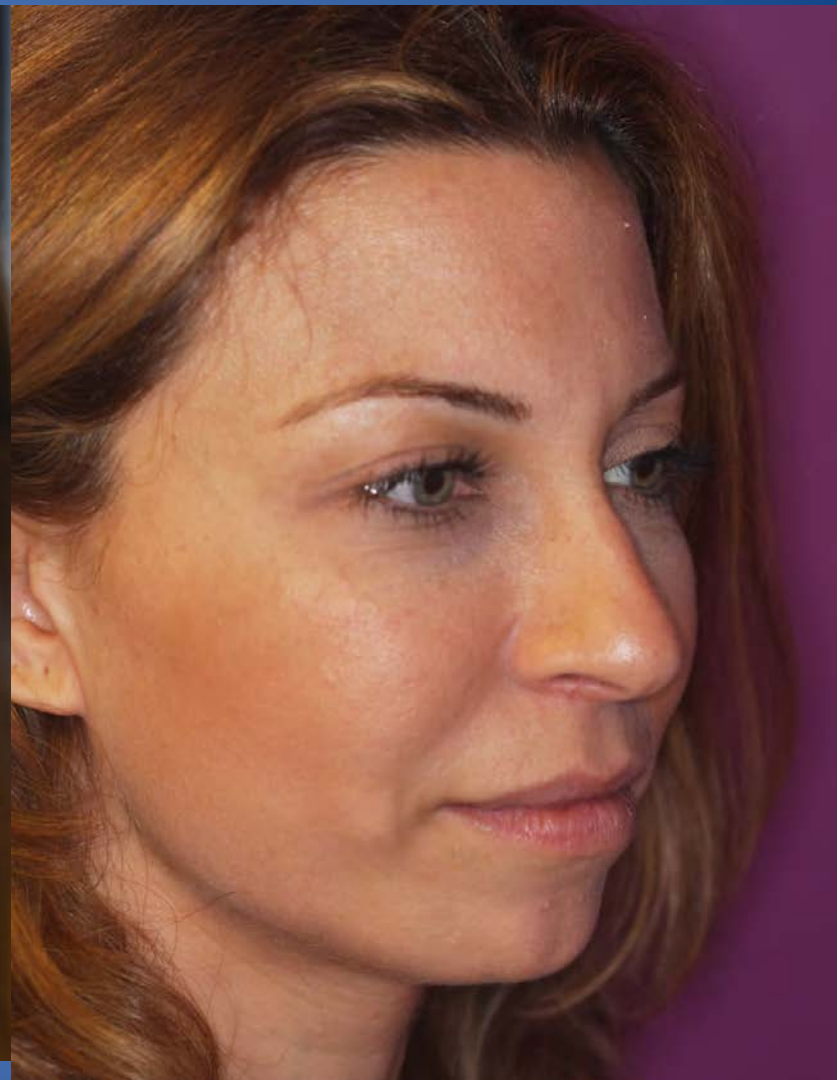
After



Dr. Ibrahim EL ACHKAR

Before


After



Dr. Ibrahim EL ACHKAR

Before

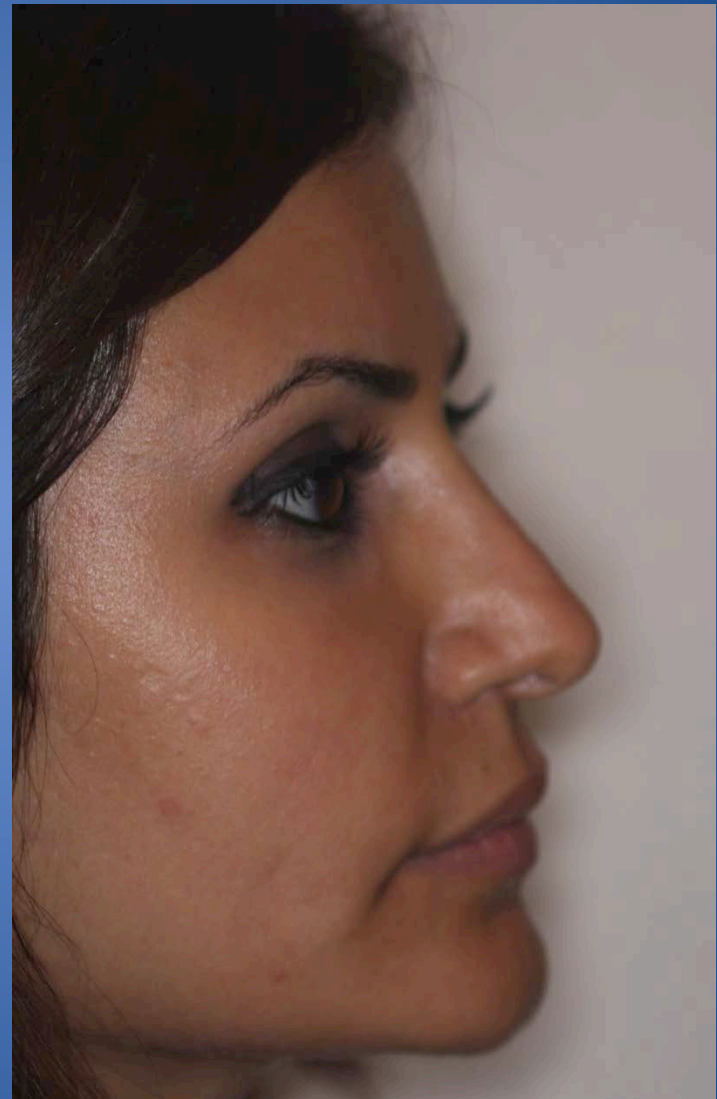
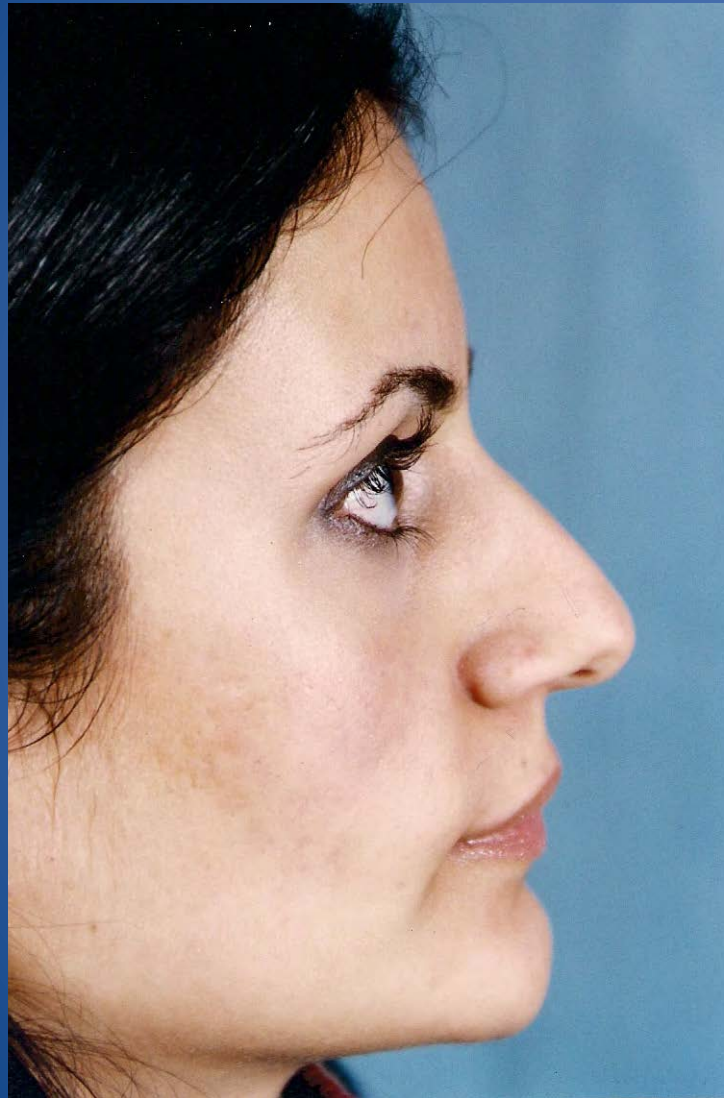
After



Dr. Ibrahim EL ACHKAR

Mid face:


- ✓ Cheeks
- ✓ Nose
- ✓ Noso labial folds



Dr. Ibrahim EL ACHKAR

Before

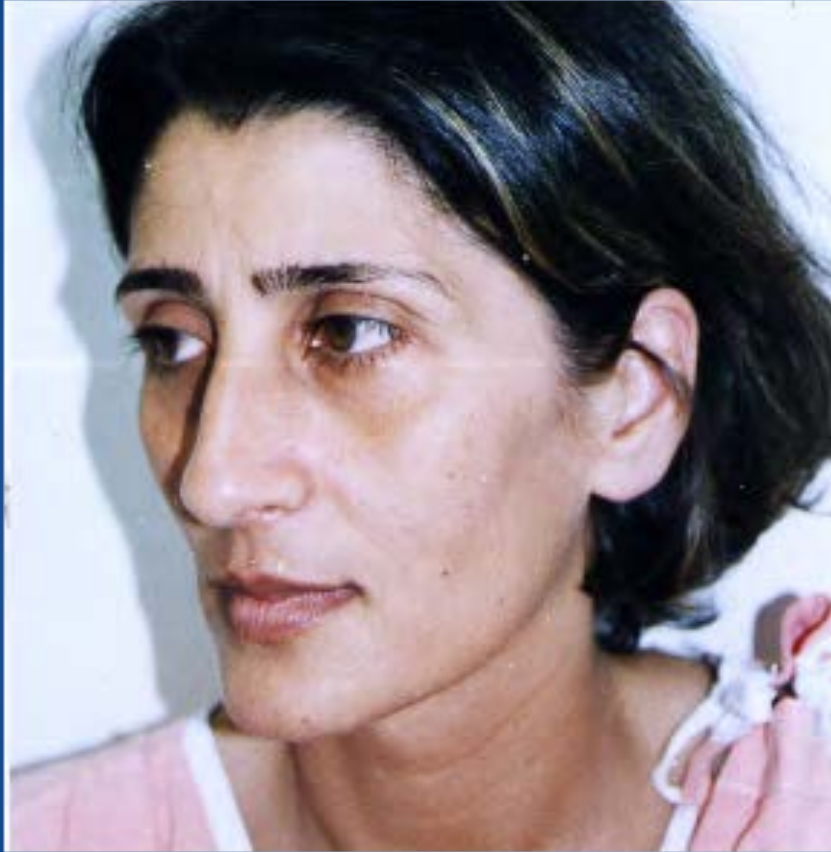After



Dr. Ibrahim EL ACHKAR

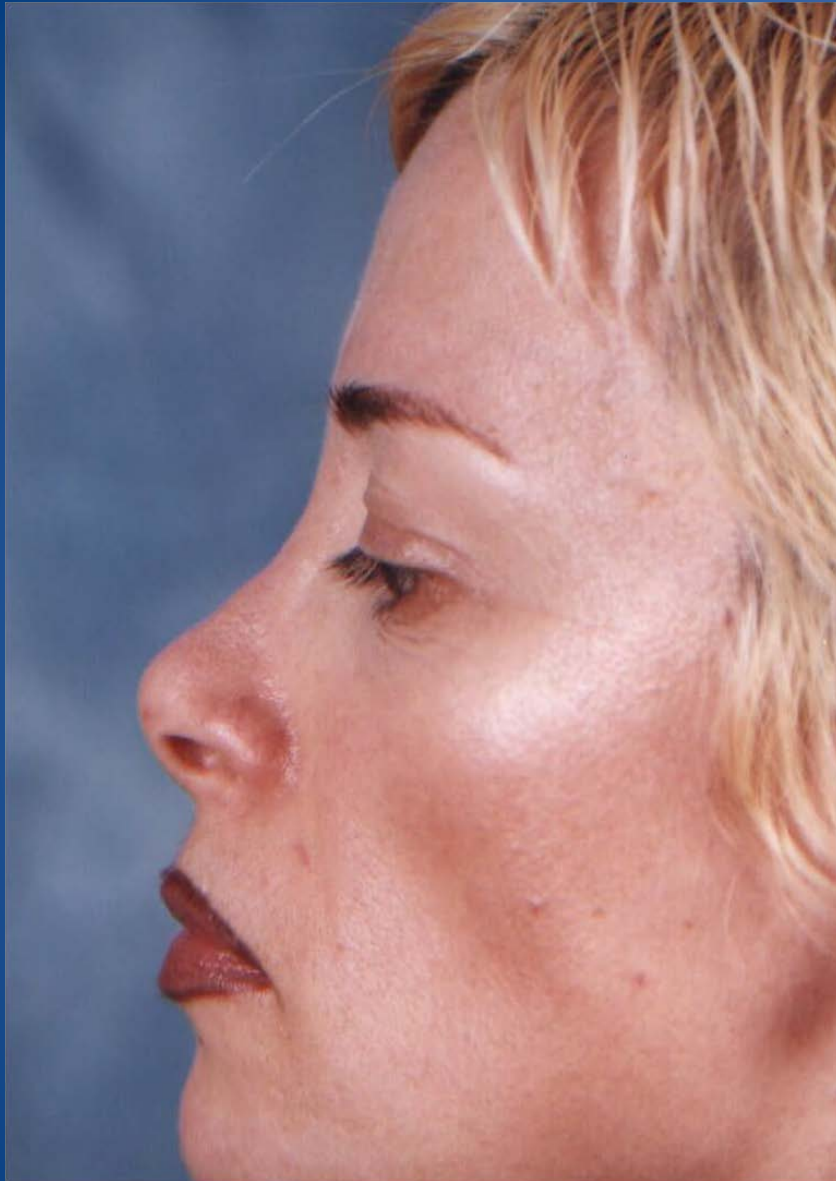Before

After

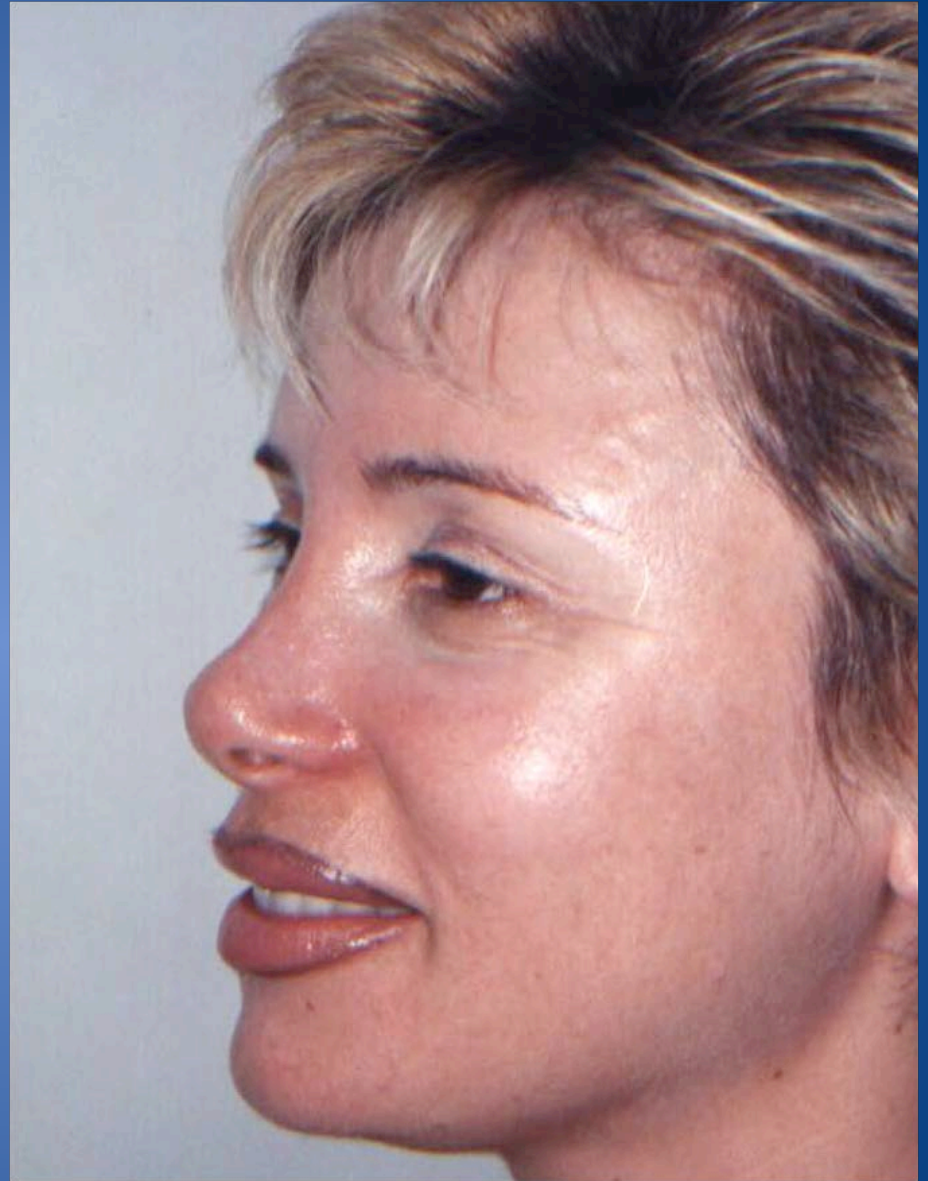

Dr. Ibrahim EL ACHKAR

Before

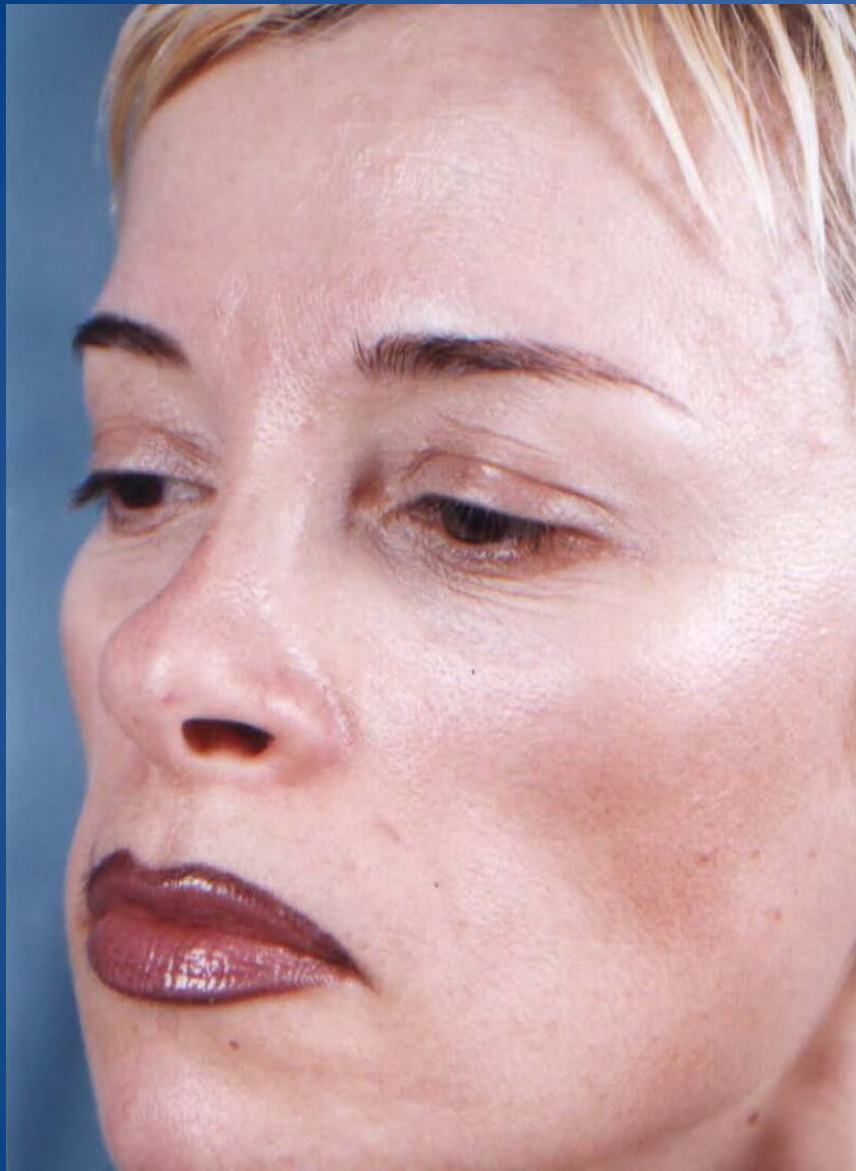

After



Dr. Ibrahim EL ACHKAR

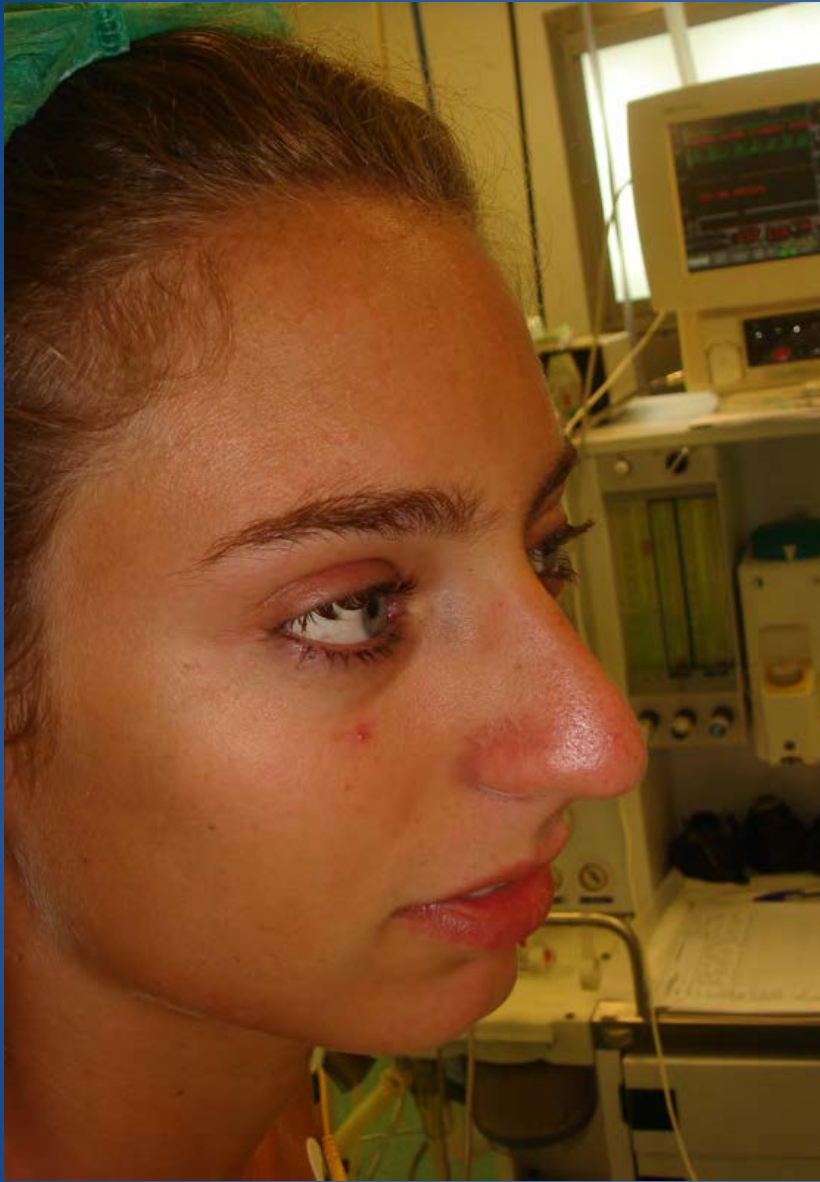
Before



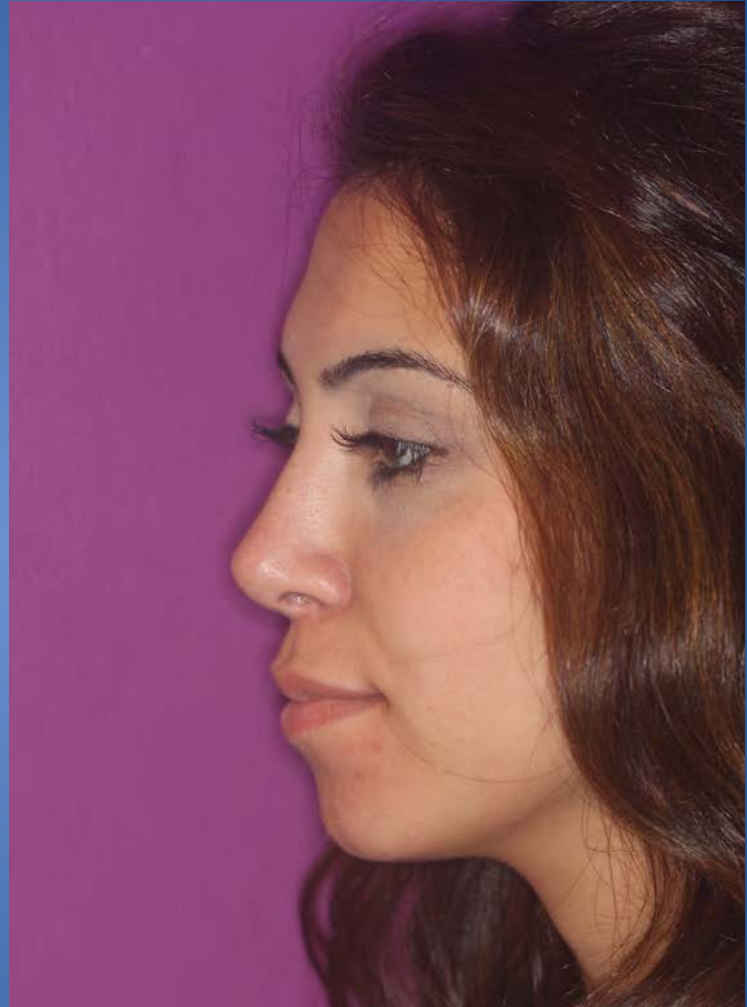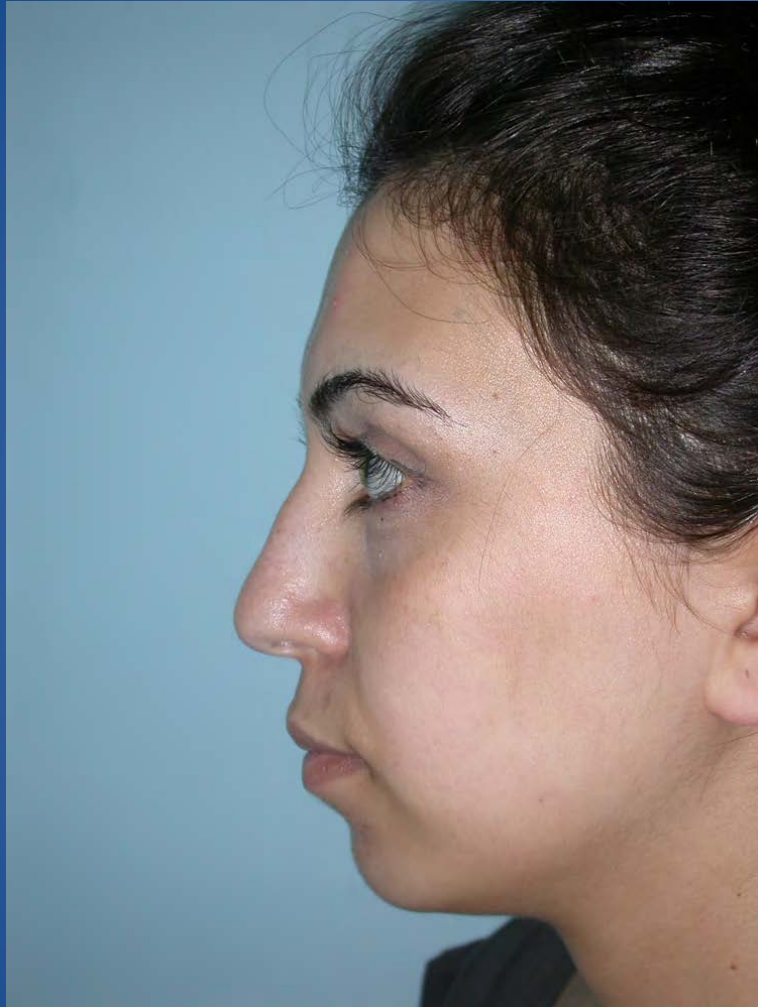After



Dr. Ibrahim EL ACHKAR




Dr. Ibrahim EL ACHKAR




Dr. Ibrahim EL ACHKAR





Dr. Ibrahim EL ACHKAR



Dr. Ibrahim EL ACHKAR



Dr. Ibrahim EL ACHKAR



Dr. Ibrahim EL ACHKAR