

**Breast Cancer 2015**

**Breast reconstruction**

**with own tissue after mastectomy**

A new microvascular technique with muscle sparing TRAM flap



**Authors: Helena K. Puonti MD, Satu K. Jääskeläinen MD, Ph D, Seppo O. Soinila MD Ph D, Helena Hallikainen MD, Taina A Partanen MD Ph D**

# Helena Puonti

- plastic surgeon in 1998
- micro surgeon since 1991
- head of the plastic surgery in Savonlinna Central Hospital, Finland
- head surgeon of the private own womens Clinic Helena, Savonlinna, Finland

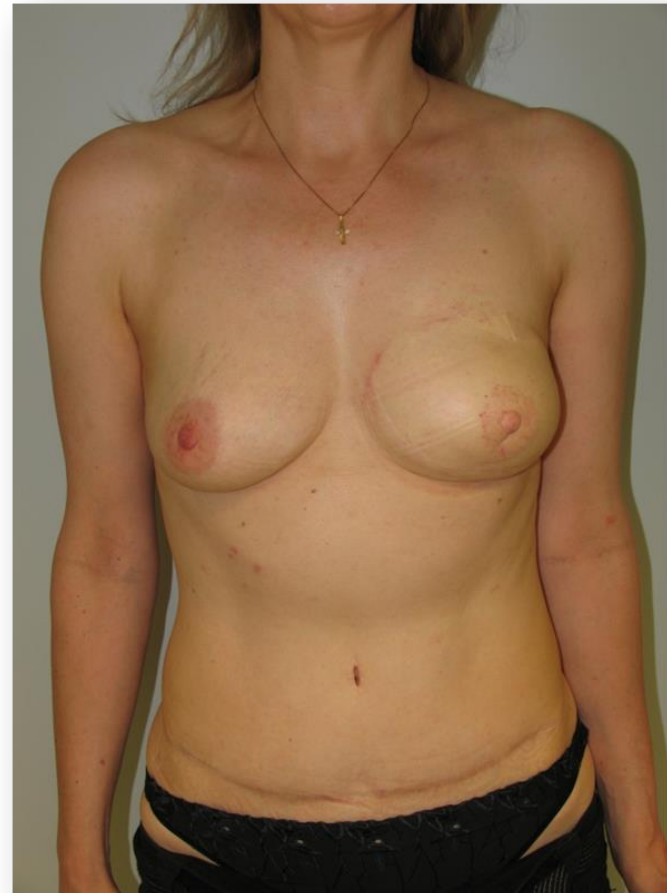
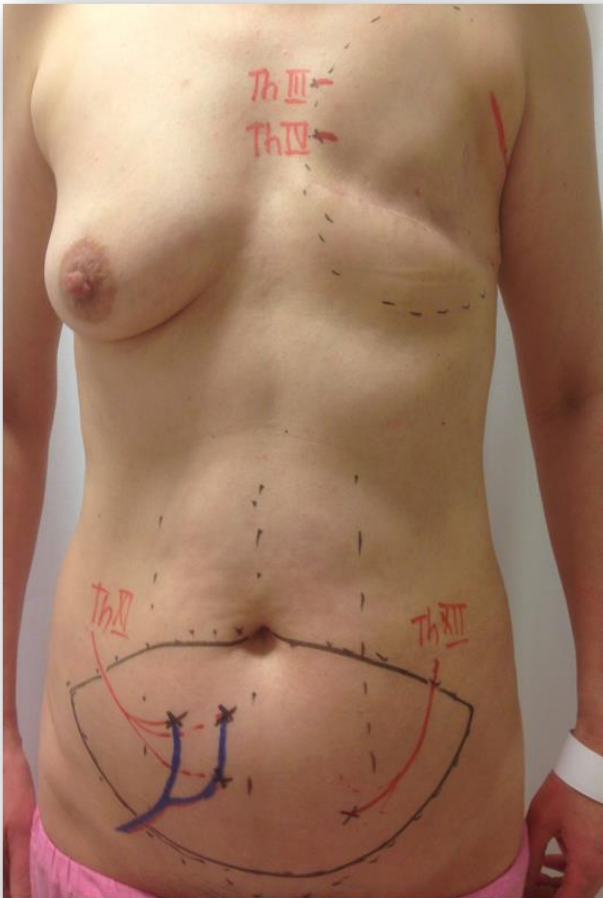


WOMEN'S  
HEALTH CLINIC  
**HELENA**

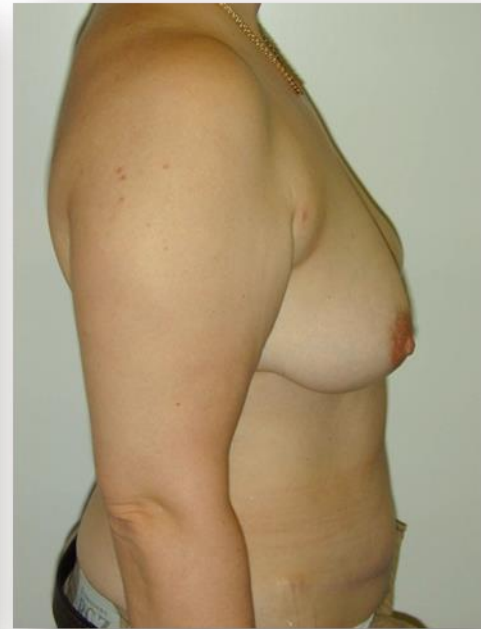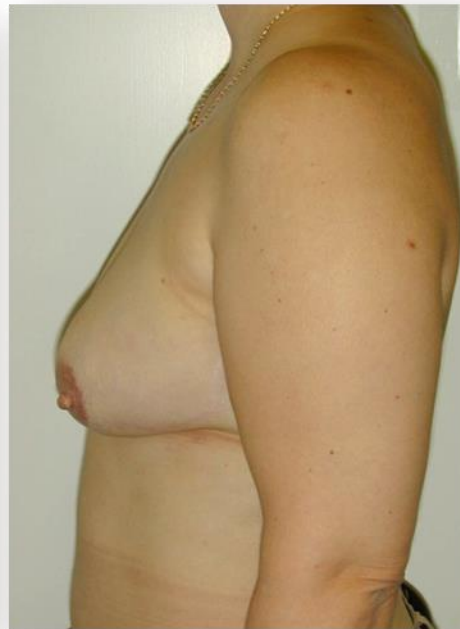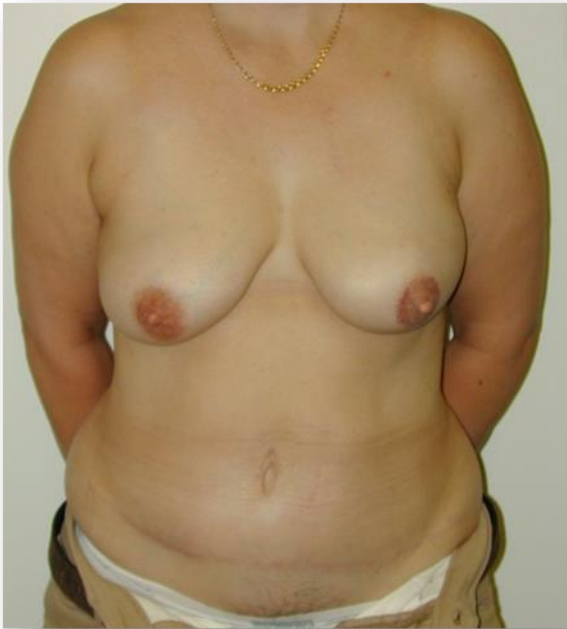[www.clinichelena.com](http://www.clinichelena.com)



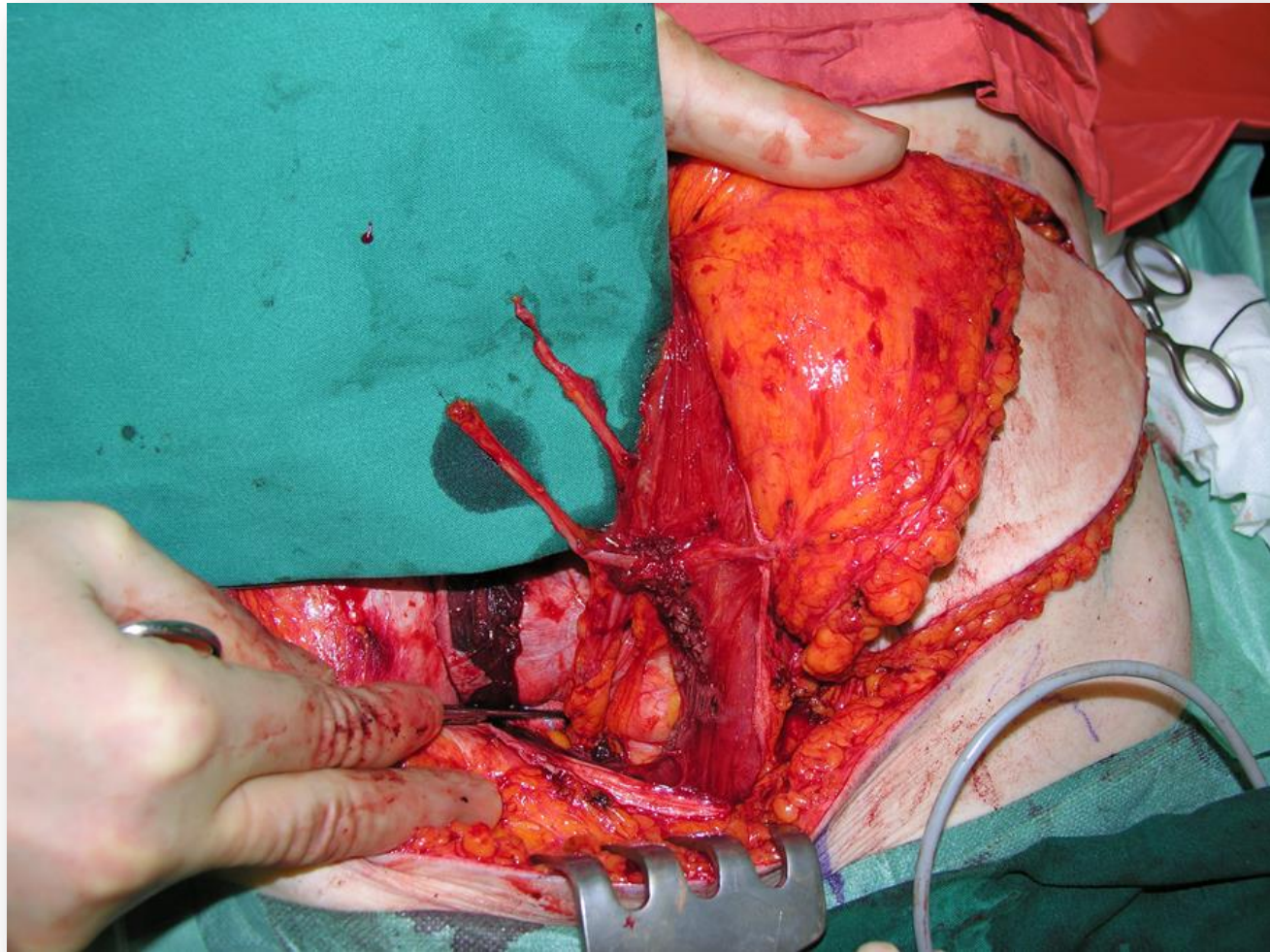
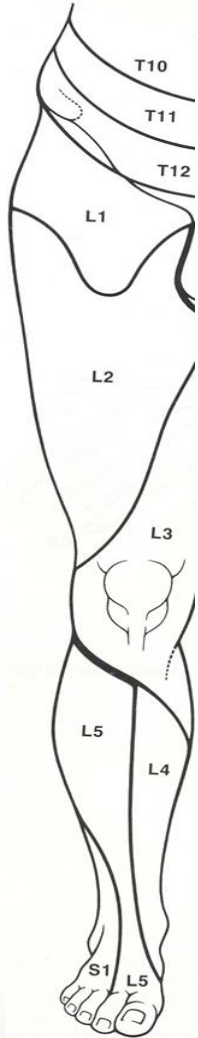
# Breast reconstruction with delayed muscle sparing microneurovascular TRAM flap after skin sparing mastectomy

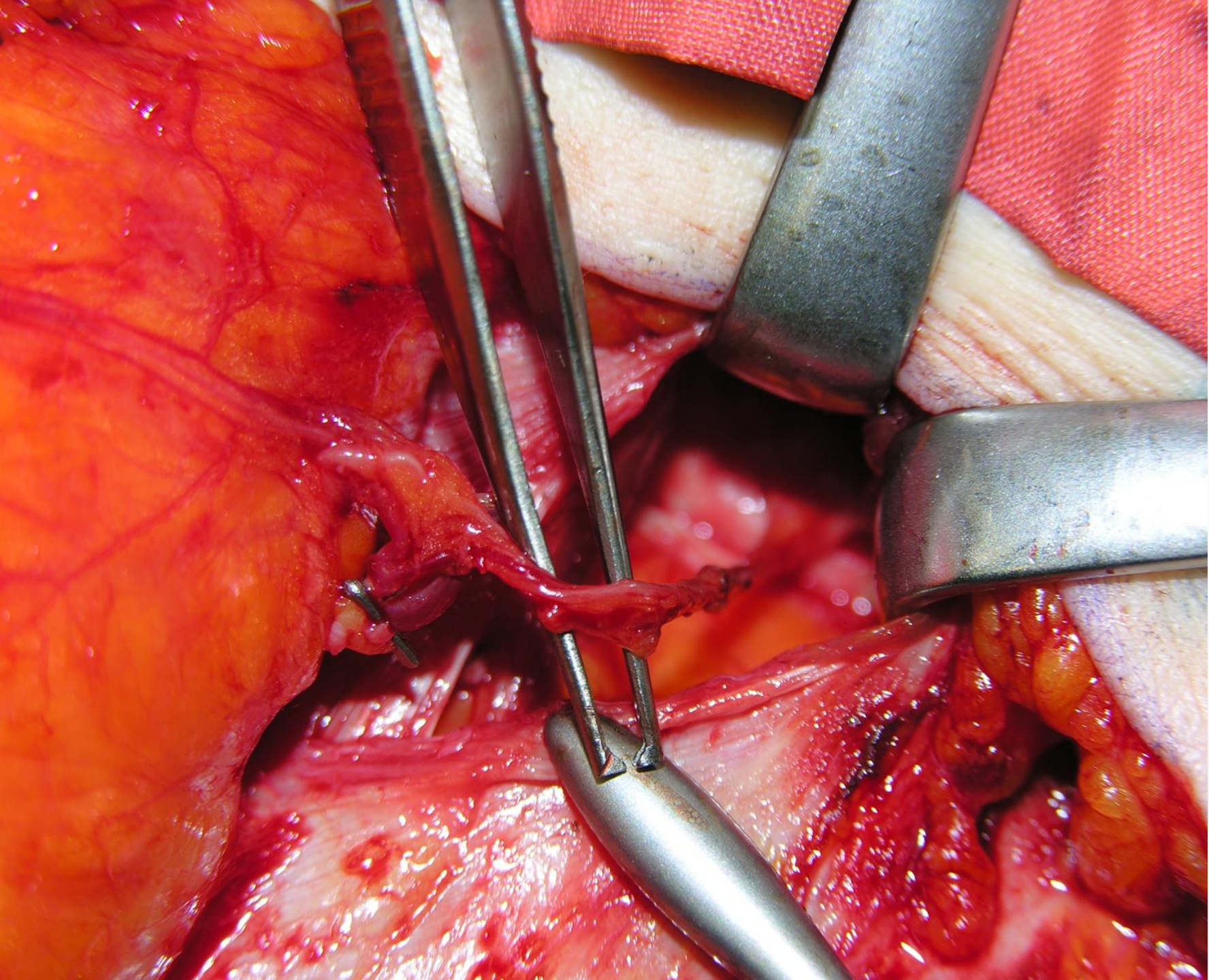


# Breast reconstruction with immediate muscle sparing microvascular TRAM flap after skin sparing mastectomy

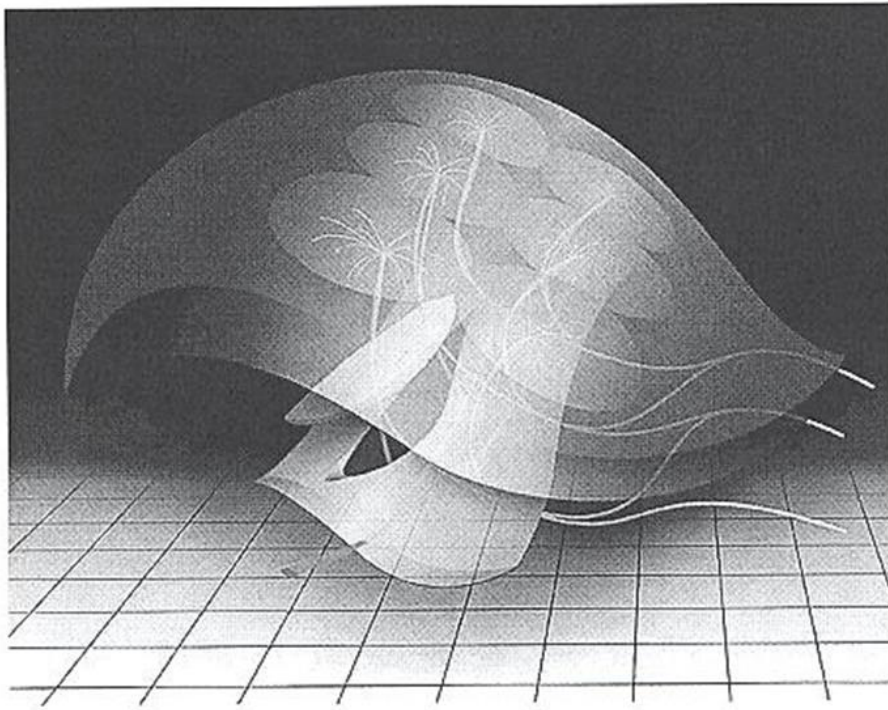


# Neuro-TRAM, donor nerves



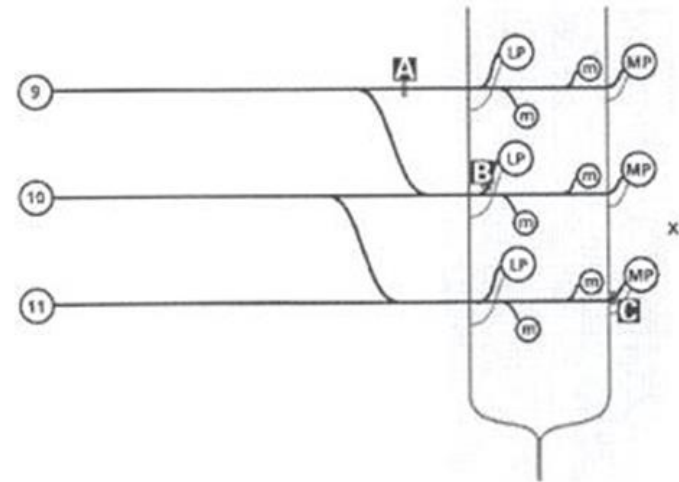


# Neural network in a TRAM-flap



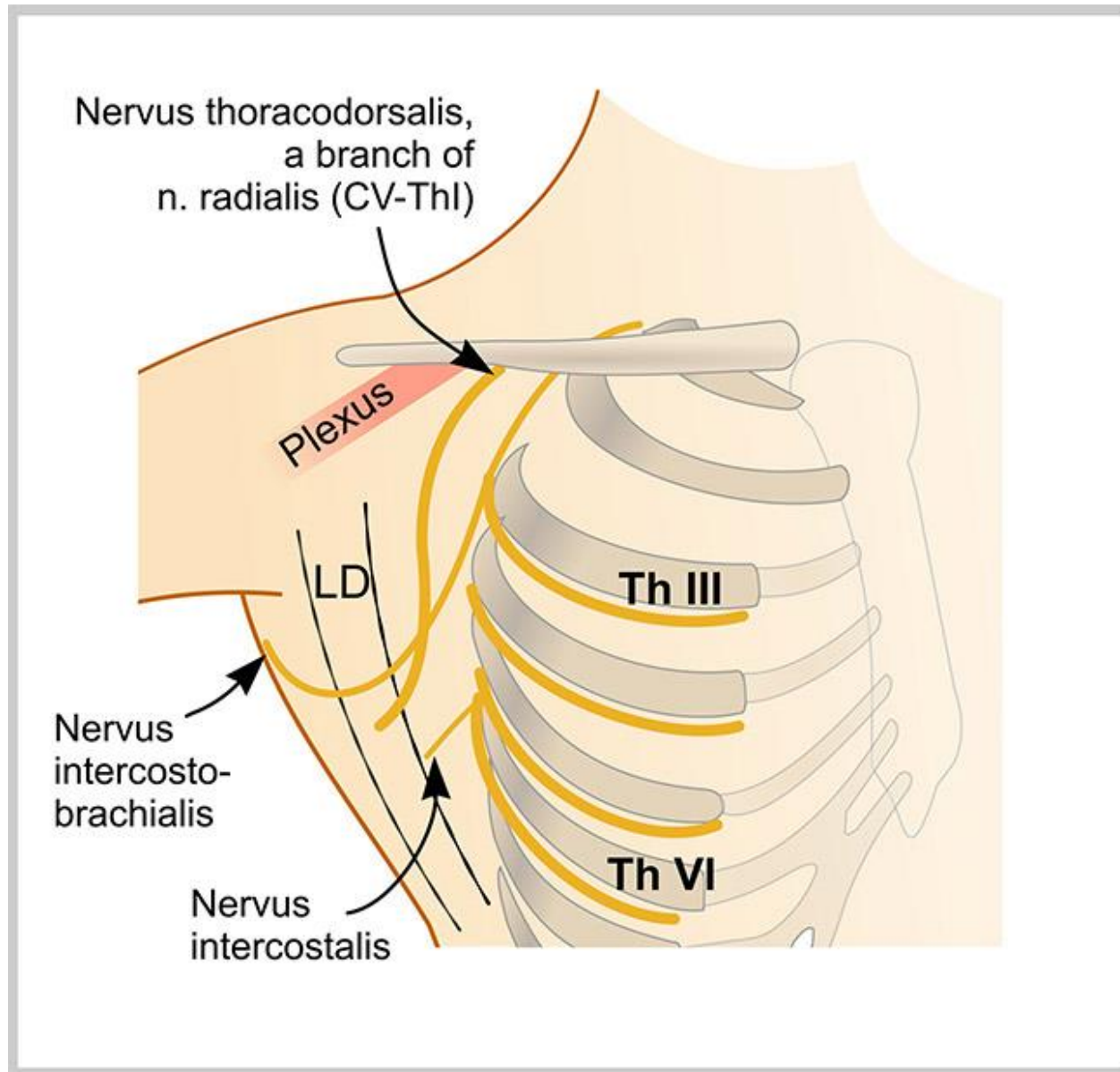
L.H. Yap. Br J of Ps, 2002, 43

**Figure 14**—Conceptual diagram of the anatomy of the sensate TRAM/DIEP flap. There are several different potential neurosomes that can be harvested for reconstruction, depending on the tailoring and 'fit' of the flap reconstruction. The deep inferior epigastric vascular axis is shown in red and segmental thoracic nerves are shown in yellow, while neurosomes are represented as virtual ellipses on the flap.



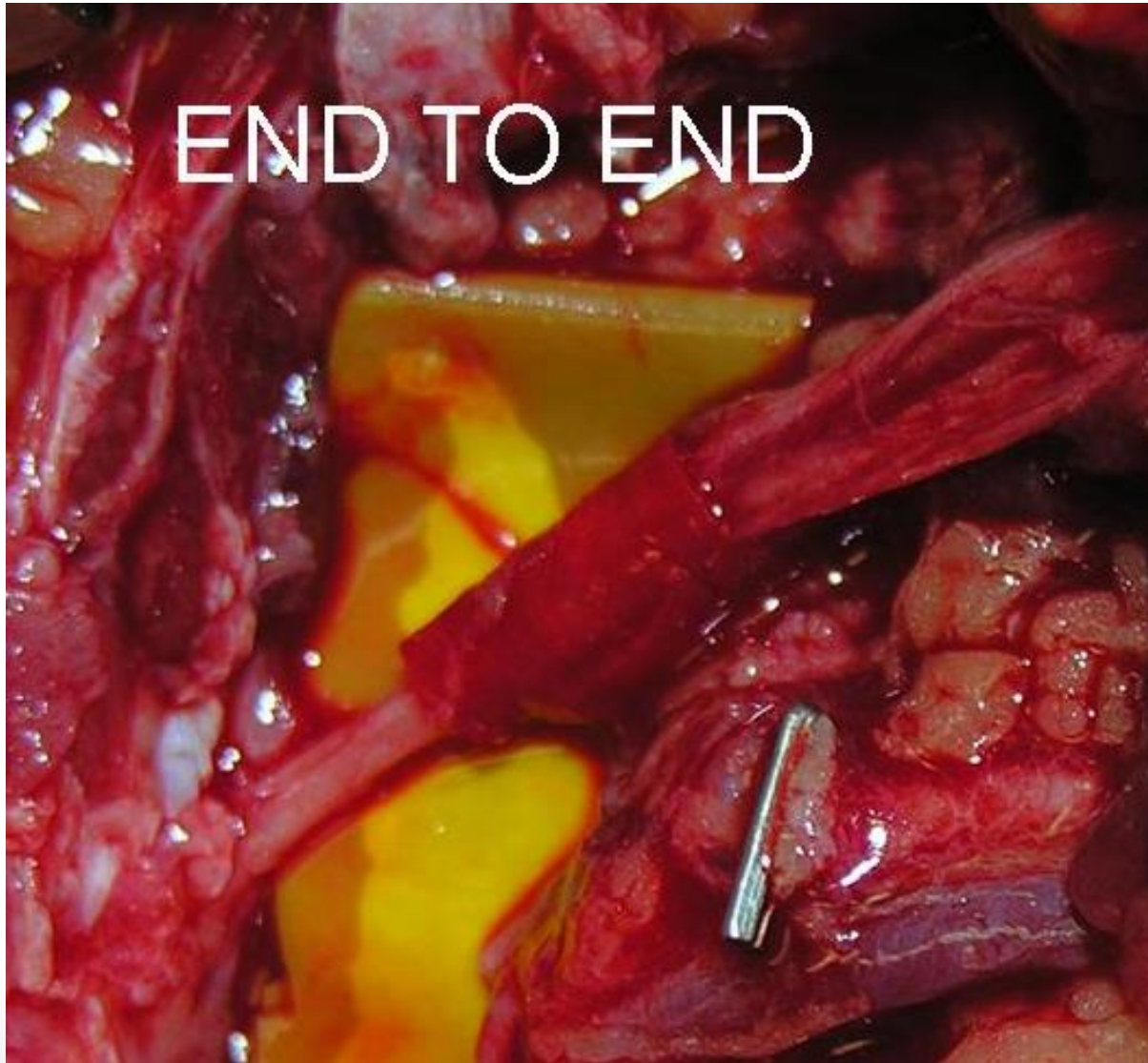**Figure 13**—Conceptual diagram of the distribution of a segmental intercostal nerve. LP: lateral perforator; MP: medial perforator; m: muscular branch. A: usual point of nerve harvest lateral to the rectus sheath; B: point of harvest for sensate flap based on lateral neurovascular bundle; C: point of harvest for sensate flap based on medial neurovascular bundle.

# Neuro-TRAM, axillary recipient nerves

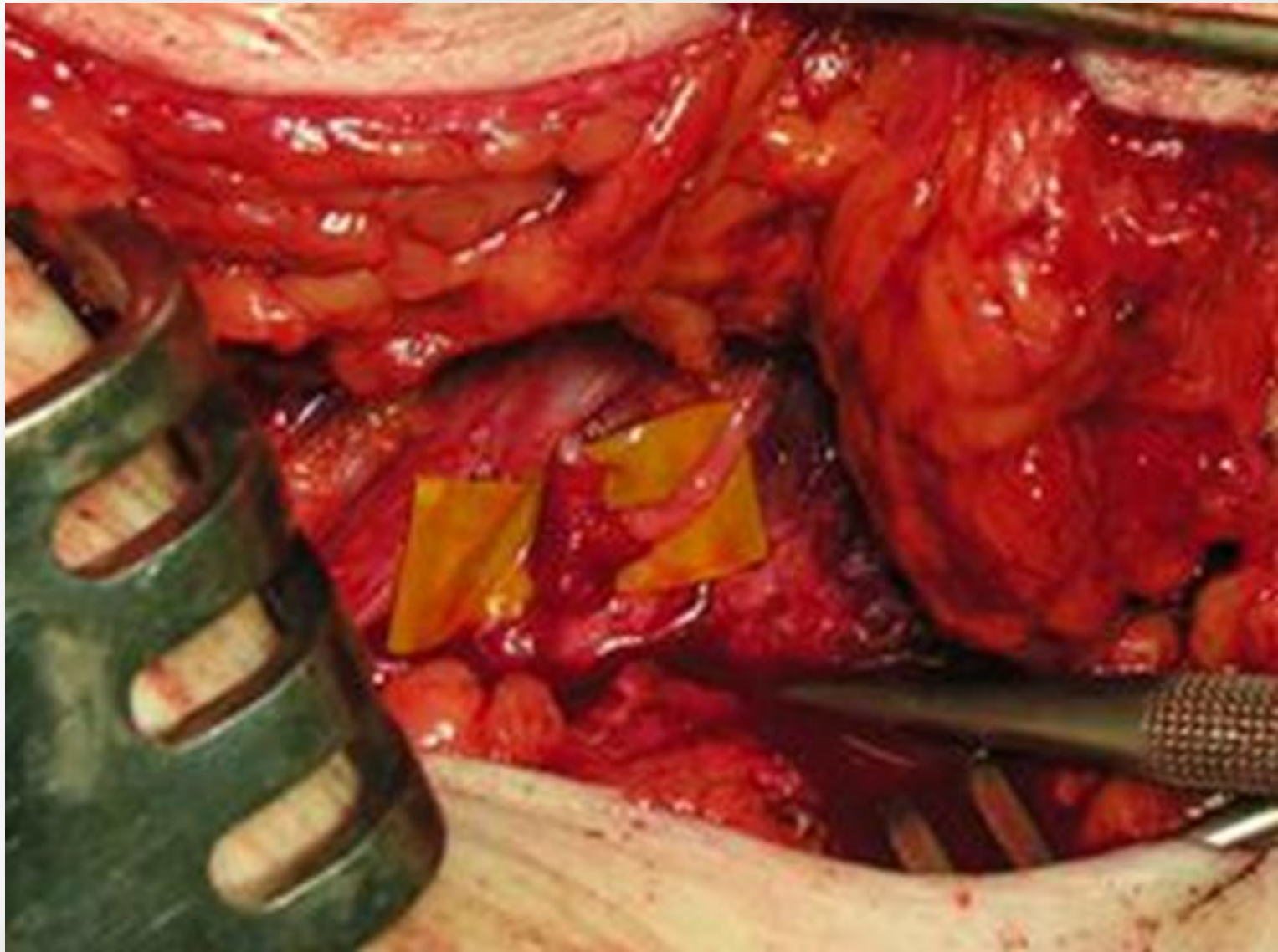


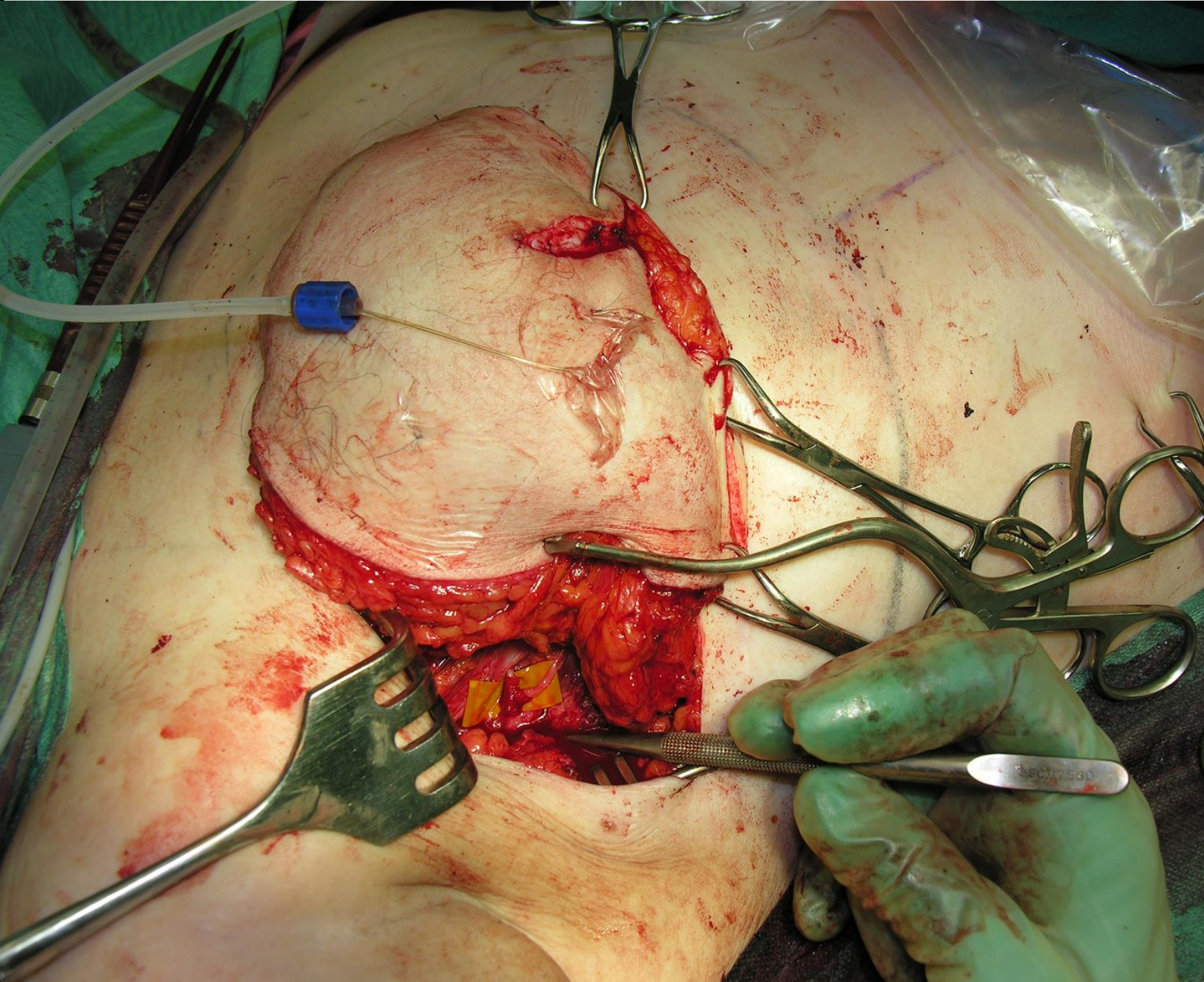


# End to end



# End to side

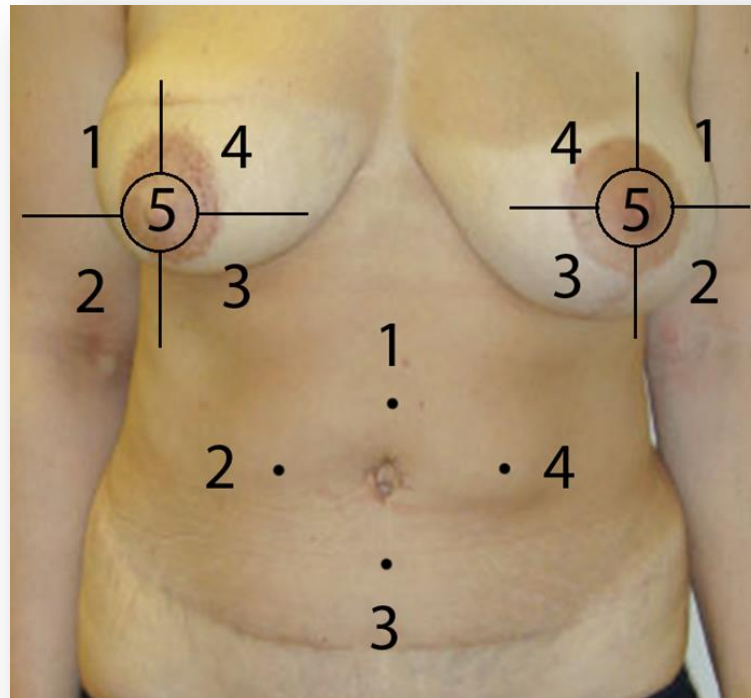
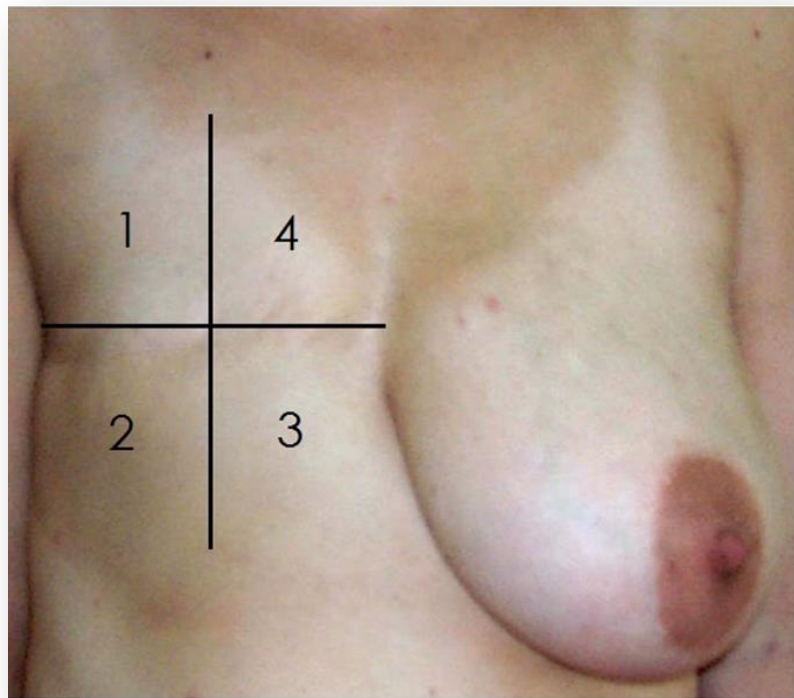




# Sensory testing

- Clinical sensory tests; two points discrimination, vibration, sharp-blunt discrimination, 0y, 1y, 2y
- Quantitative sensory tests (QST); warm detection, heat pain detection, cool detection, tactile detection, 0y, 1y, 2y
- Skin biopsy, 0y, 1y, 2y
- Somatosensory evoke potential (SEP), 1y, 2y
- Patient questionnaire, 1y, 2y

# The used zones for sensory testing before (0y), 1y and 2y after breast reconstruction



# Results

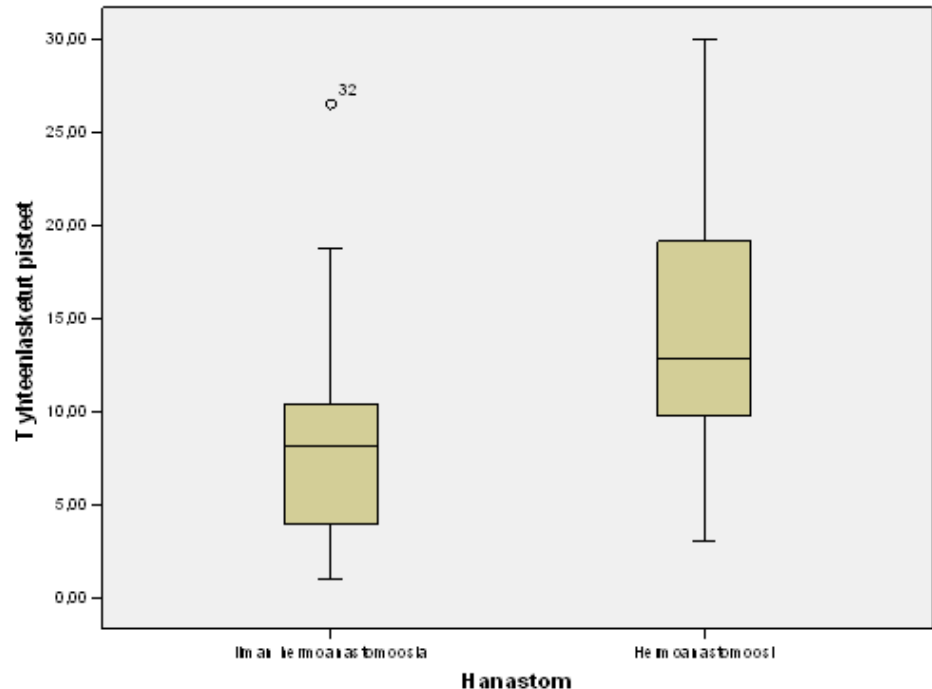
- The Total Sensory scores was the sum of individual scores of different tests
- The highest and lowest recorded value of normal sensing breast defined the limit of scores

# A new approach to microneurovascular TRAM-flap breast reconstruction - a pilot study

by Helena K Puonti, Satu K Jääskeläinen, Helena K Hallikainen, Taina A Partanen

**Result:** Sensibility recover in neuro-TRAM breast was about half of the sensibility of a normal breast and significantly better than in conventional TRAM-breast reconstruction

Journal of plastic reconstructive aesthetic surgery JPRAS (2011)  
Volume: 64, Issue: 3, Pages: 346-352

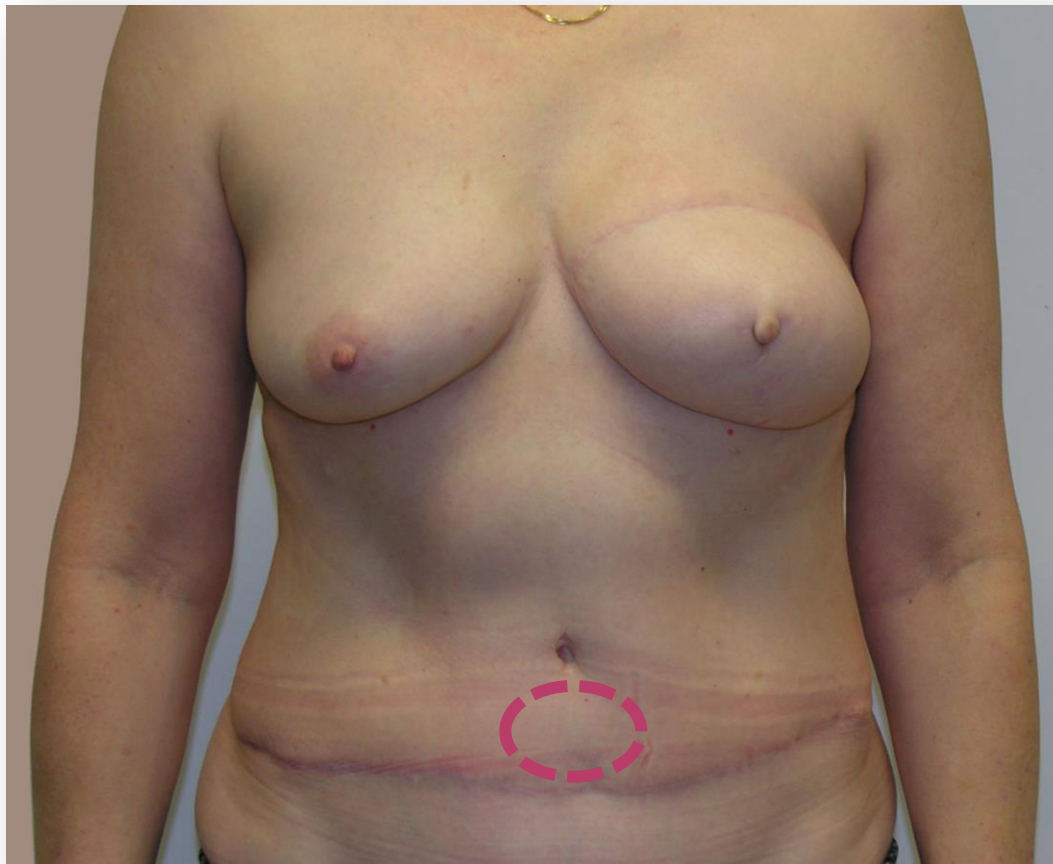


Median/quartile, Mann-Whitney test  
p 0.006

Plast Reconstr Surg. 2012 Sep;130(3):392e-7e

## **Microneurovascular TRAM flap does not compromise abdominal sensibility more than a conventional one**

Helena K. Puonti\*, M.D., Satu K. Jääskeläinen\*\*, M.D., Ph.D., Helena K. Hallikainen\*, M.D., Taina A. Partanen\*\*\*, M.D., Ph.D.





# Demographic data of patients , and the compare of total sensibility scores (TSC) between neurorraphy and no neurorraphy groups

	Bilateral or unilateral neurorraphy	No neurorraphy	Total	Healthy breasts
<b>N</b>	76	20	96	28
<b>Age (SD), range</b>	49.2 (7.5), 19-61	51.5 (6.1), 39-60	49.7 (7.2), 19-61	50.1 (1.0), 40-61
<b>Axillary evacuation</b>	48 (63 %)	17 (85 %)	65 (68 %)	-
<b>Radiation</b>	67 (88 %)	10 (50 %)	77 (80 %)	-
<b>Chemotherapy</b>	44 (58 %)	6 (30 %)	50 (50 %)	-
<b>Immediate TRAM</b>	15 (20%)	6 (30 %)	21 (22 %)	-
<b>Delayed TRAM</b>	61 (80 %)	14 (70 %)	75 (78 %)	-
<b>Operation time (min), range</b>	452, 305-655	428, 327-598	447, 305-655	-
<b>Flap ischemia time (min), range</b>	54, 22-115	49, 20-68	52, 20-115	-
<b>Size of the flap breast (g), range</b>	613, 215-1170	617 (353-1115)	614, 215-1170	-
<b>Follow-up time (months), range</b>	27 , 23-43	54, 27-81	33, 23-81	-
<b>TSC , median/quartiles</b>	<b>14.5, 10.3-18.0*</b>	<b>8.1, 3.5-10.7</b>	<b>13.4, 9.0-17.9</b>	<b>29.8, 27.5-32.8</b>

\*p=0,000, significant comparing with no-neurorraphy group



WOMEN'S  
HEALTH CLINIC  
HELENA

[www.clinichelena.com](http://www.clinichelena.com)

Contact information:

+358 40 8266 242

e-mail: [info@clinichelena.com](mailto:info@clinichelena.com)

Thank You!

