Evaluation of Breast Specimens after Neoadjuvant Chemotherapy

A.A. Sahin M.D.

Professor of Pathology and Translation Molecular Pathology

Section Chief of Breast Pathology and Director of Education

THE UNIVERSITY OF TEXAS
MD Anderson Cancer Center
Making Cancer History®

Indications of Neoadjuvant Chemotherapy

- Management of locally advanced invasive breast ca including inflammatory breast ca
- 'Down-staging' of large inoperable cancers to permit surgical resection
- Routine management of women with high risk disease who would require adjuvant chemotherapy based on biological tumour characteristics and clinical-radiological findings

Pre Treatment Evaluation - Breast

- Pre treatment breast CNB must be adequate for unequivocal diagnosis of invasive carcinoma and assessment of key prognostic/predictive factors
  - Histological type and grade
  - ER/ PR /HER2 status
  - Other biomarkers- Ki67, multigene assays
- If multiple lesions biopsy of at least 2 foci is advised to confirm multifocality and look for heterogeneity

Pre Treatment Evaluation - Axilla

- Routine axillary U/S with histological assessment of abnormal nodes by CNB or FNA
- Pre-treatment SLNB not advised unless positive result will influence decision to give chemotherapy
- Nodal response is an important prognostic factor independent of response in the breast

Specimen Handling

- One of the most critical steps in accurately evaluate response to NAC is the macroscopic (gross) assessment of the specimen
- A multidisciplinary approach with close clinical/ radiological correlation to map the precise location of the tumor bed is preferable to exhaustive blind sampling

Specimen Handling

- To achieve this it is essential that the surgical request form contains adequately detailed clinical information
- Access to radiological images, particularly MRI scans, at the time of specimen dissection is also useful

Neoadjuvant Chemotherapy

- 38 yrs female presented with a 2.5 cm palpable breast mass. Physical exam revealed prominent ALN
- She had a core bx of her breast mass and FNA of ALN
- Her breast bx showed a high-grade IDC and ALN FNA was positive for metastatic carcinoma

AJCC Clinical Stage: T2N2M0
Classification: Stage III

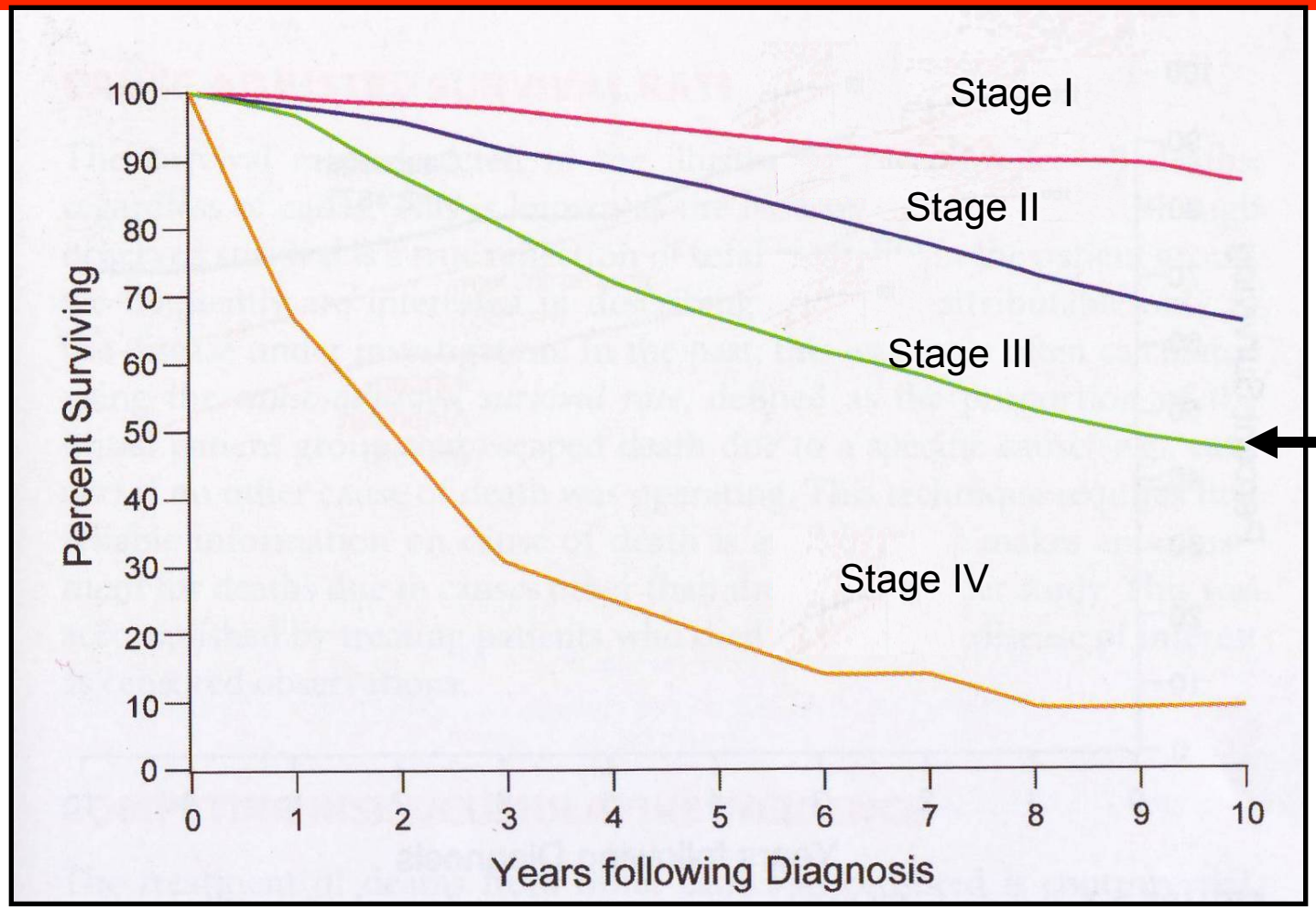

Her expected survival is 40%

Neoadjuvant Chemotherapy

- The patient was treated with neoadjuvant chemotherapy including four cycles of cytoxan adriamycin and taxol
- Clinically the mass became softer and smaller
- Lymph nodes were no longer palpable

Neoadjuvant Chemotherapy

- MRI showed complete resolution of the mass
- Patient underwent an excision of the mass and complete axillary node dissection

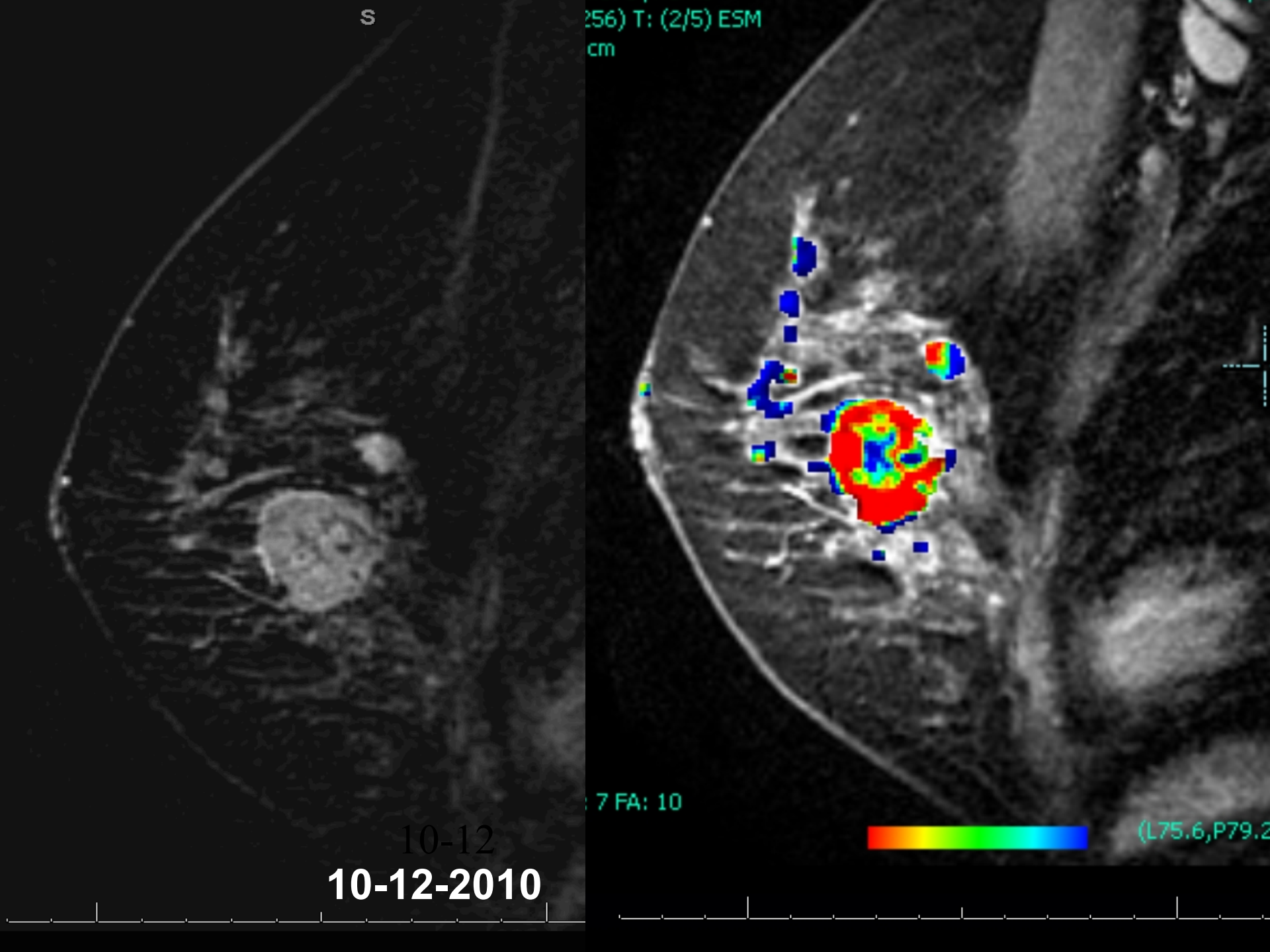
S
256) T: (2/5) ESM
cm
7 FA: 10
(L75.6,P79.2
10-12
10-12-2010

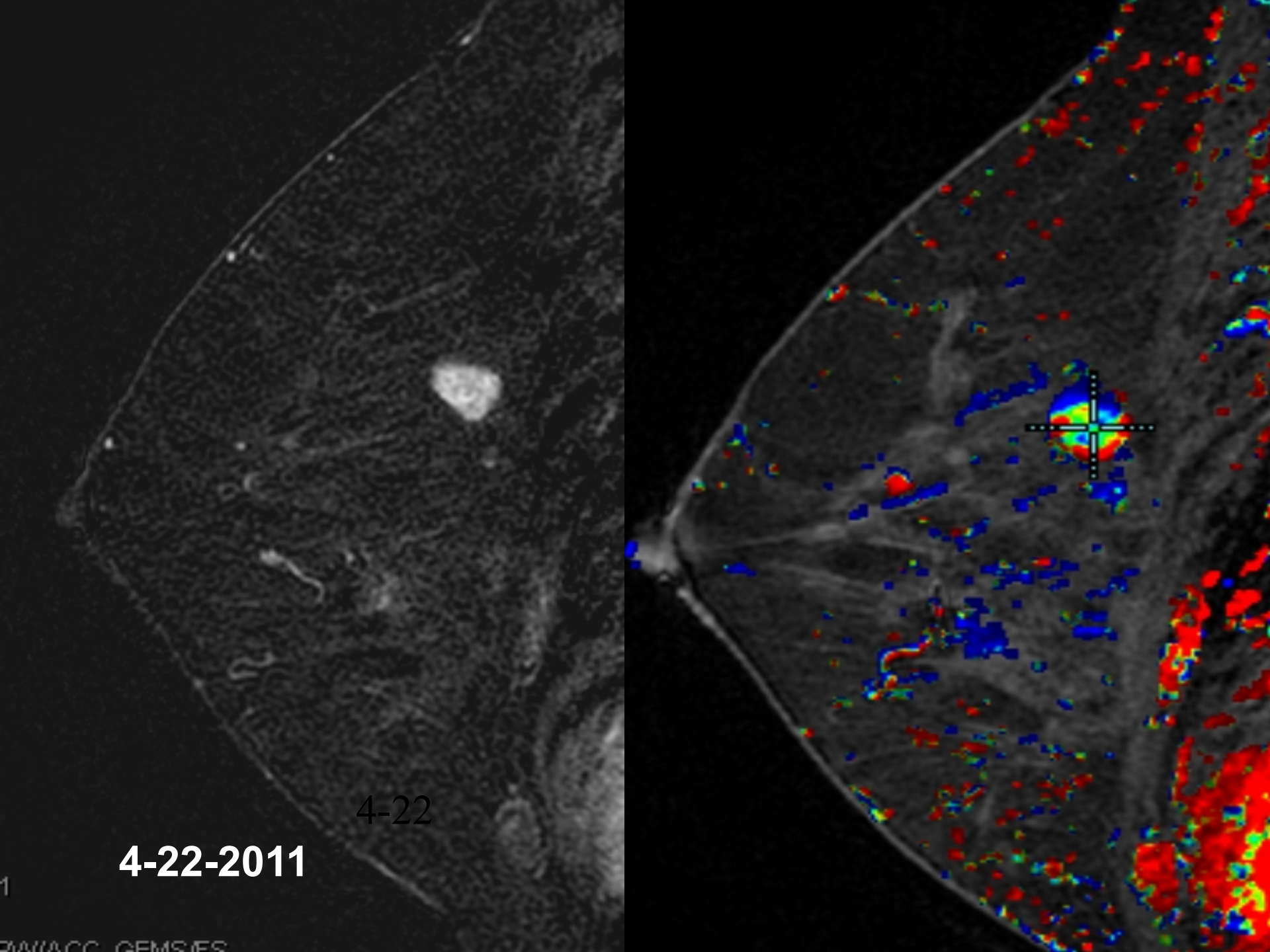
4-22
4-22-2011

Sex: F
S#: 108.00
IIP: IIP-92_SCU
PID#:a30137660c
Key
ww/wl 911/516
BREAST:W 0304
G1.4G#0.60+0.30,MCP1.5EF0.6,C*1.0*1.0

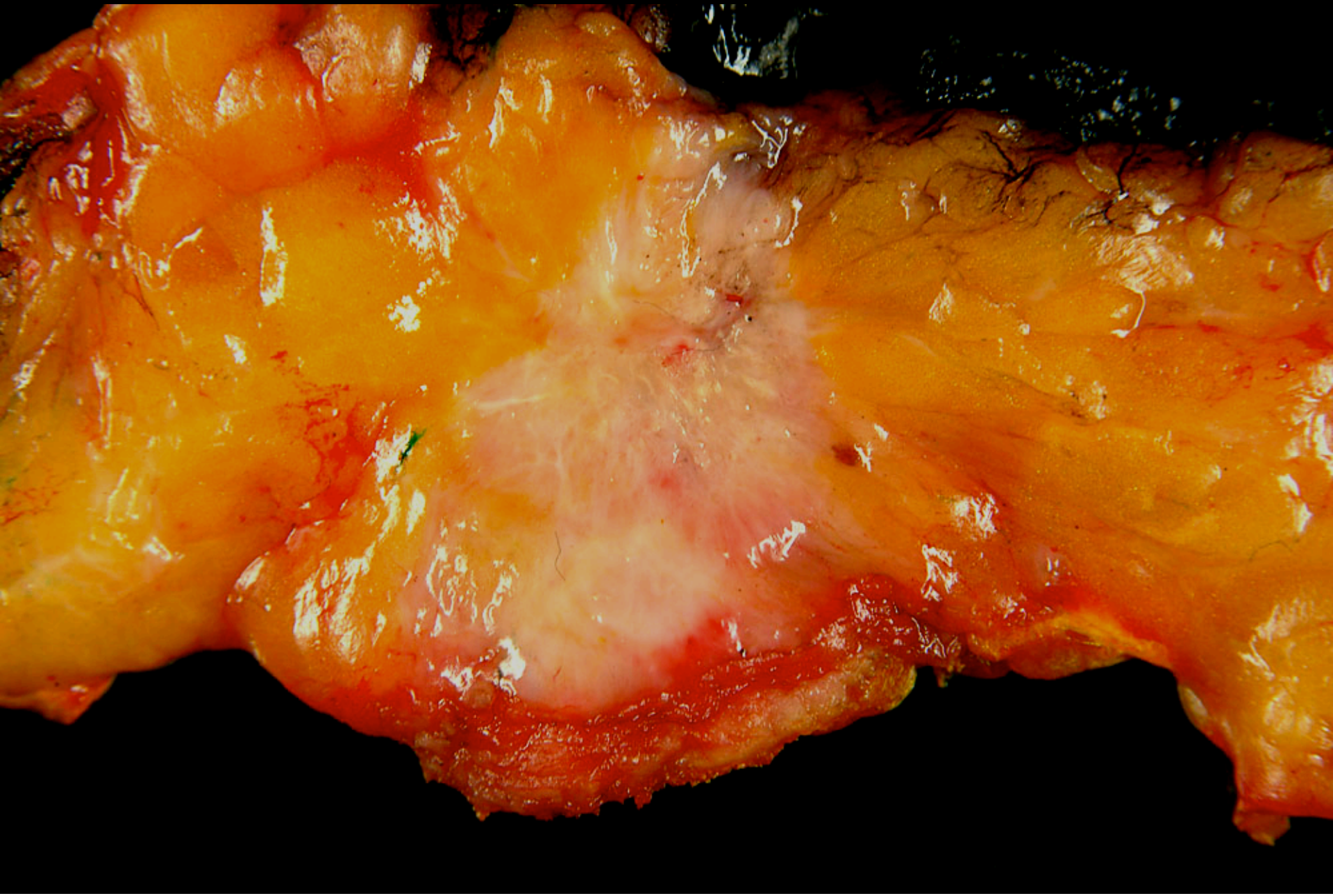

Neoadjuvant Chemotherapy

- The tumor bed consisted of an area of histiocytes and lymphocytes. No residual carcinoma was identified
- Sixteen lymph nodes were excised
- All were negative for metastatic carcinoma

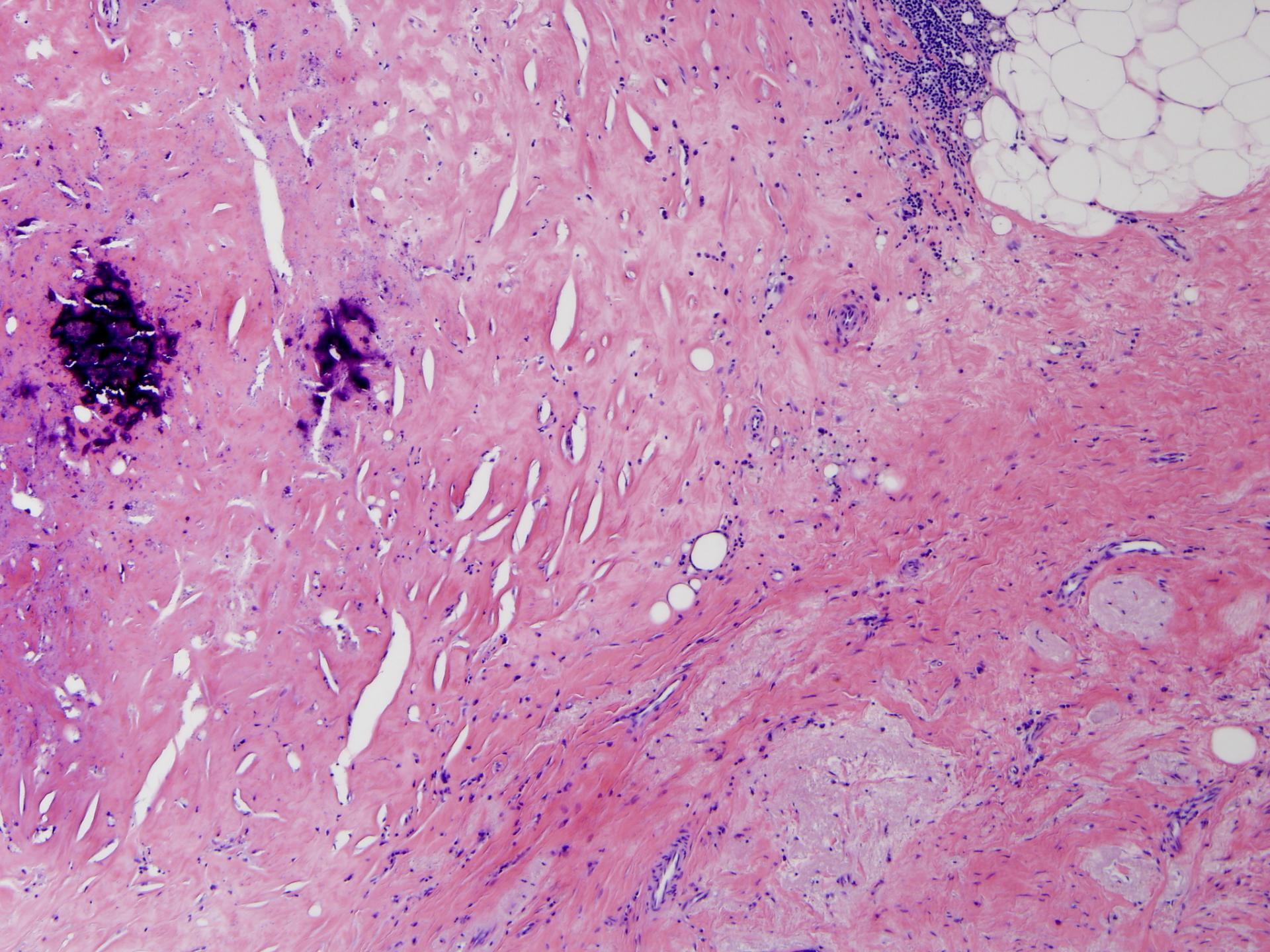

Neoadjuvant Chemotherpay

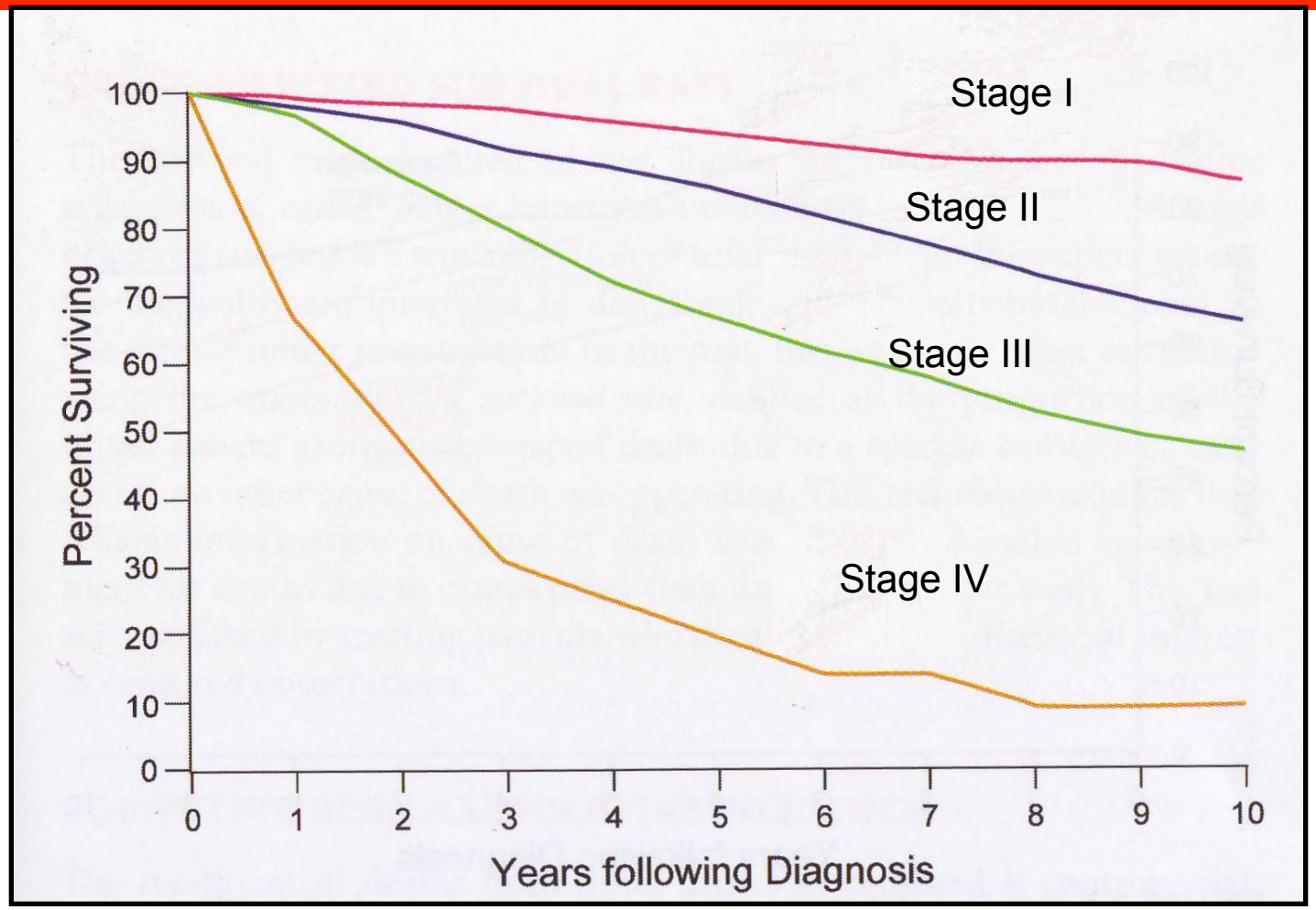

Her expected survival is over 90%

Neoadjuvant Chemotherapy

- Standard therapy for locally advanced breast carcinoma
- Increasingly used for early stage operable disease
- A wide range of pathologic changes can occur after neoadjuvant chemotherapy

Methods to Determine Response to NAC

- Clinical examination
- Imaging methods (mammographs, US, MRI)
- Histopathologic evaluation

Neoadjuvant Chemotherapy

Clinical Response

- 60-80% patients with locally advanced breast carcinoma show measurable clinical response
- Imprecise

Methods to Determine Response to NAC

- Clinical/imaging methods
  - False negative 40-60%
  - False positive 20-30%

Histopathologic evaluation is gold standard

Neoadjuvant Chemotherapy

Pathological Response

- PCR is defined as complete absence of invasive carcinoma in the breast and no residual metastatic ca in lymph nodes
- PCR occurs 5-30% of patients with locally advanced breast carcinoma after NAC

Neoadjuvant Chemotherapy

Pathological Response

- Less than complete response (partial response) is difficult to classify

- There are different classification systems

Patterns of Tumor Response

Concentric shrinking

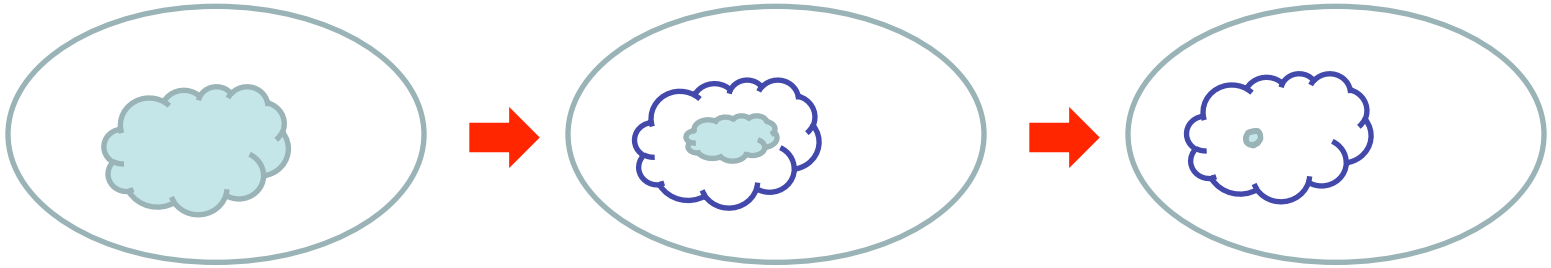

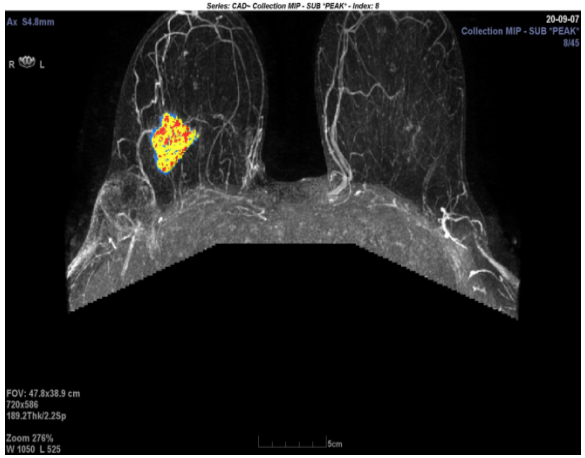

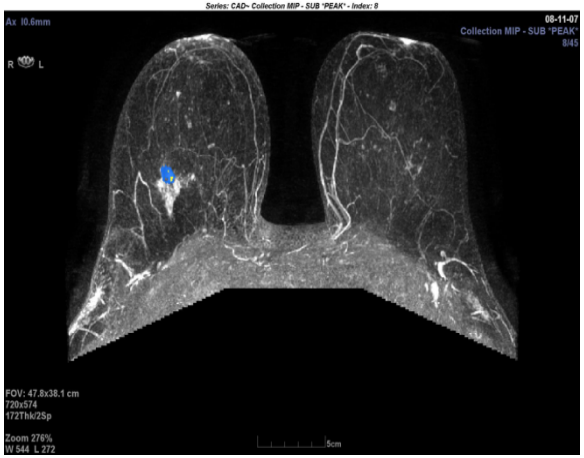

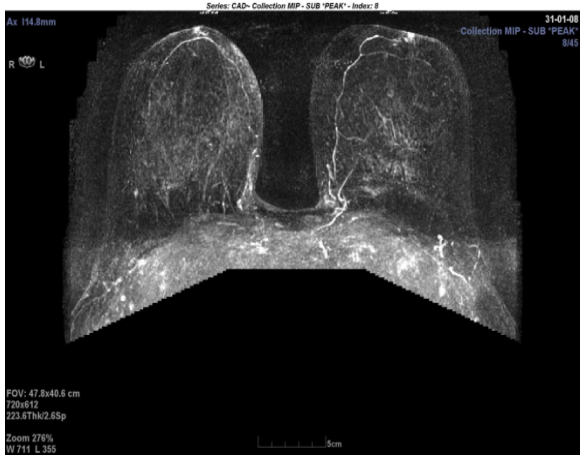

Patterns of Tumor Response

Scatter pattern

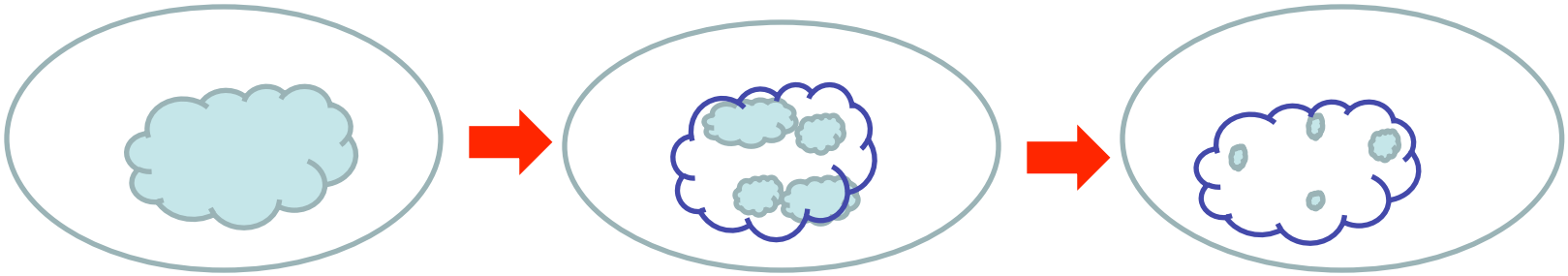

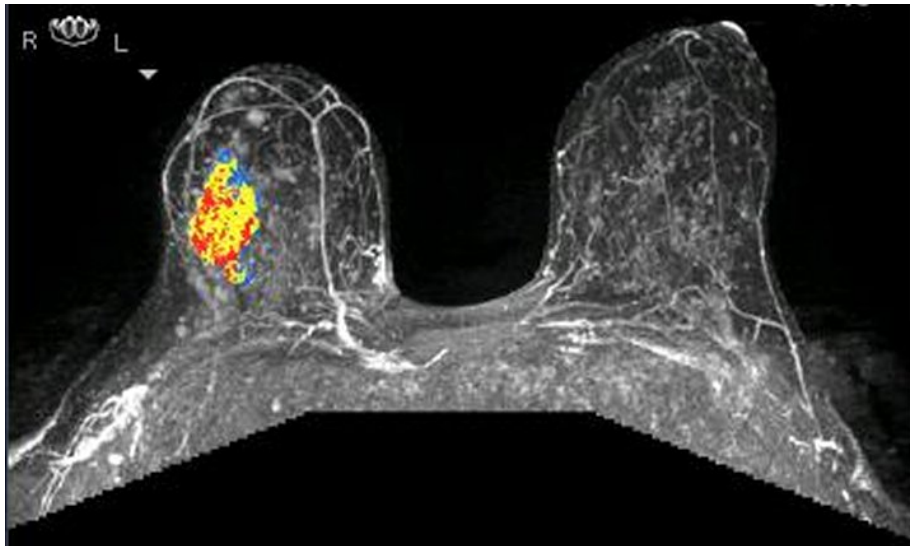

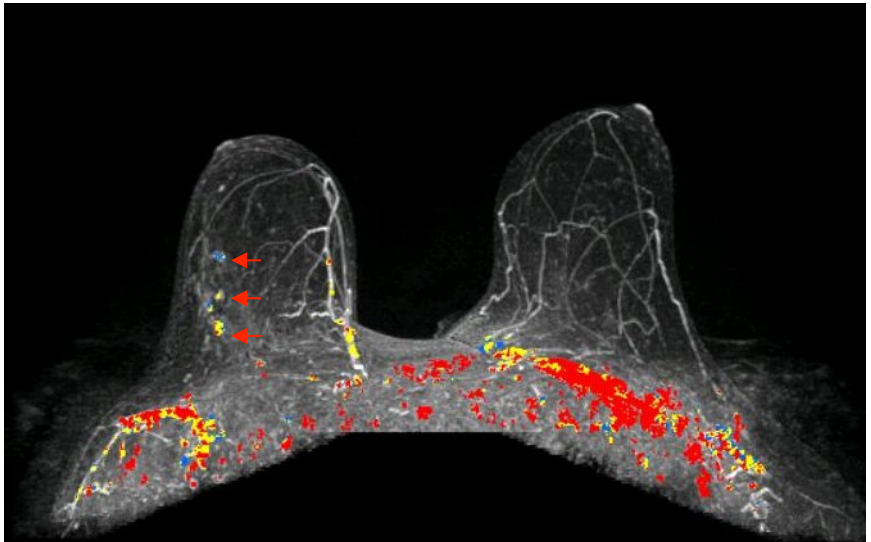

Measuring Tumor Size post NAC

- Tumor size more difficult to assess after NAC
- If there is a single lesion present on pre-treatment imaging, then treat residual disease as a single tumor, especially if tumor cells are present within a reactive stromal background consistent with a solitary tumor bed

Measuring Tumor Size post NAC

- 7th edition AJCC – largest contiguous area of tumour cells (B)
- The combination of size and residual tumor cellularity is the best indicator of response

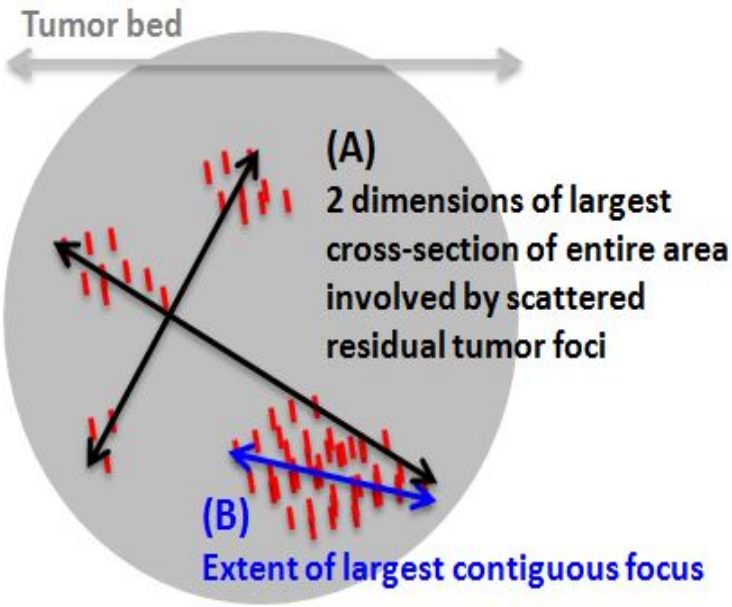

Significance of nodal response

Nodal status post NAC a strong predictor of outcome

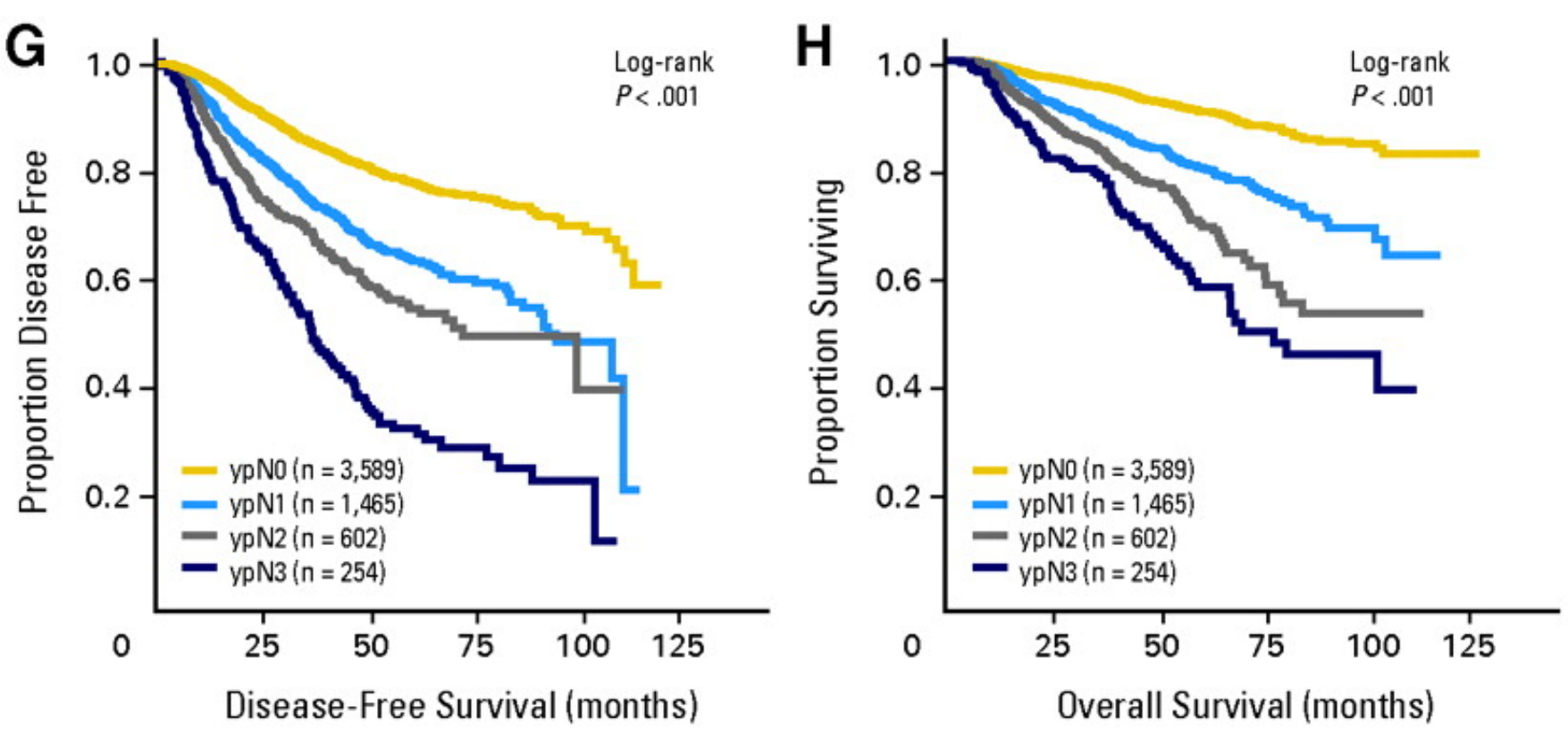

von Minckwitz G et al. JCO 2012;30:1796-1804

Lymph node changes

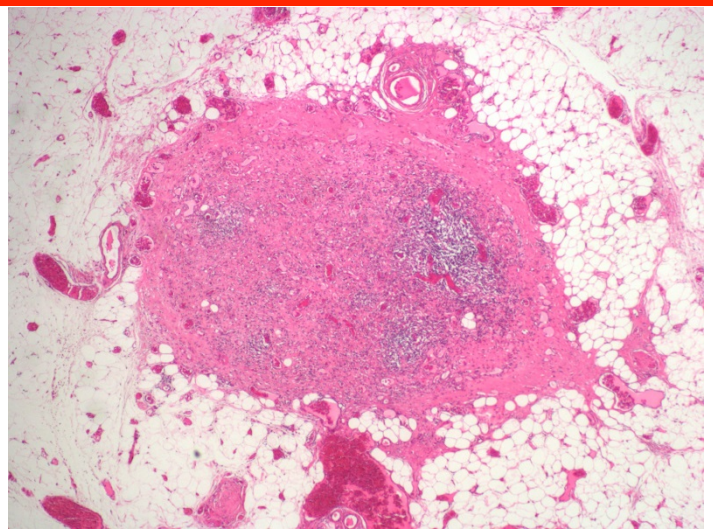

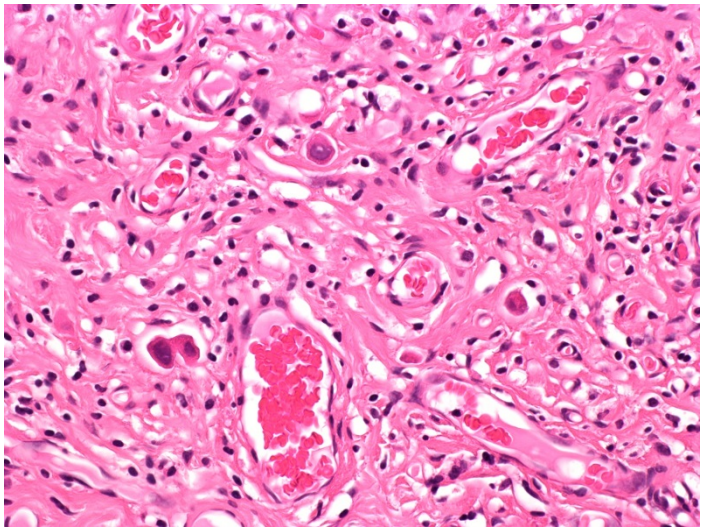

Partial response LN

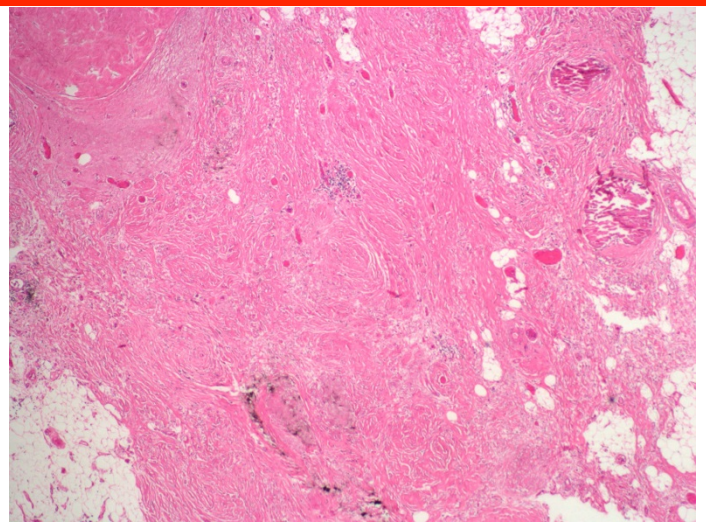

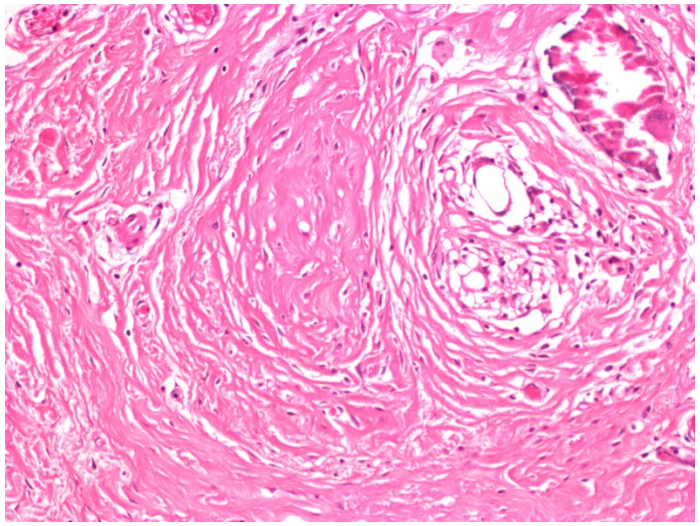

pCR breast

Systems of Categorizing Response to NAC Treatment

NSABP B-18

pCR: No recognizable invasive tumor cells present

pPR: The presence of scattered individual or small clusters of tumor cells in a demosplastic or hyaline stroma

pNR: Tumors not exhibiting therapy related changes

Miller-Payne System

- Grade 1: no reduction in overall cellularity
- Grade 2: a minor loss in overall cellularity (up to 30% loss)
- Grade 3: 30-90% reduction in cellularity
- Grade 4: >90% reduction in cellularity
- Grade 5: no residual invasive carcinoma

Classification of Breast Ca After NAC

Miller-Payne Grading System

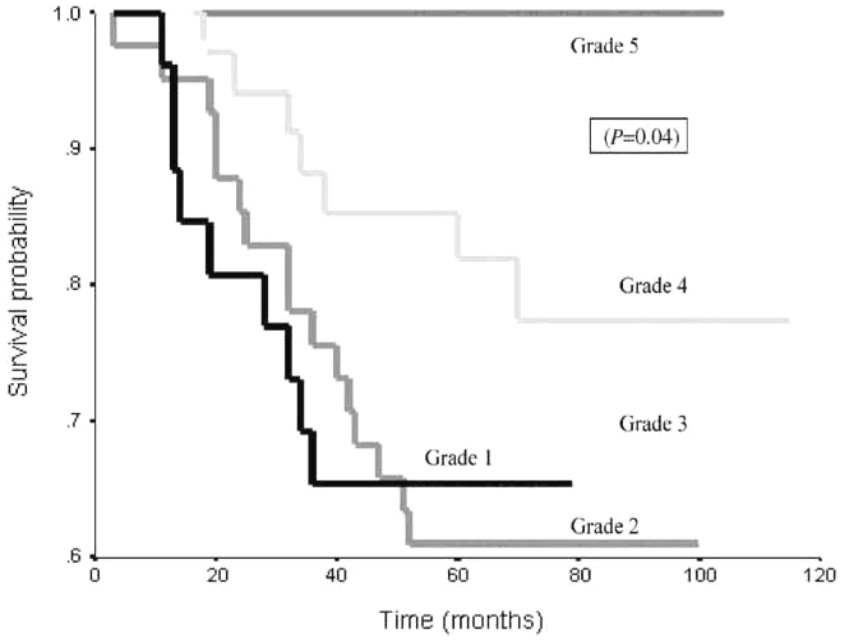

Overall survival compared with histological response to chemotherapy

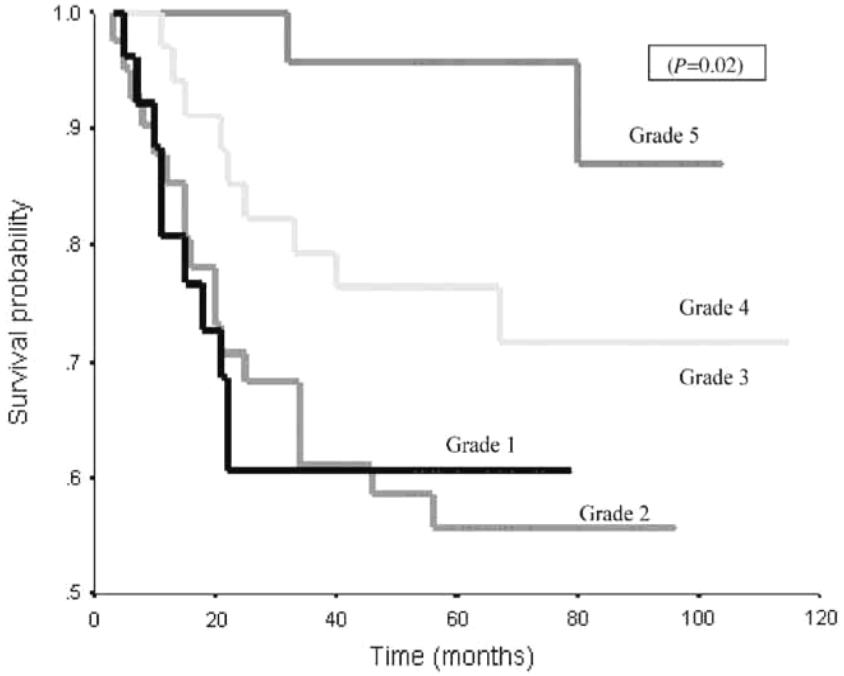

Disease free survival compared with histological response to chemotherapy

Breast. 12(5):320-7, 2003.

Miller-Payne System

- Pts with grade 4 response have a significantly worse prognosis
- Identification of small foci of residual invasive carcinoma is important
- Main limitation is that it does not include response in lymph nodes

Residual Cancer Burden System MDACC

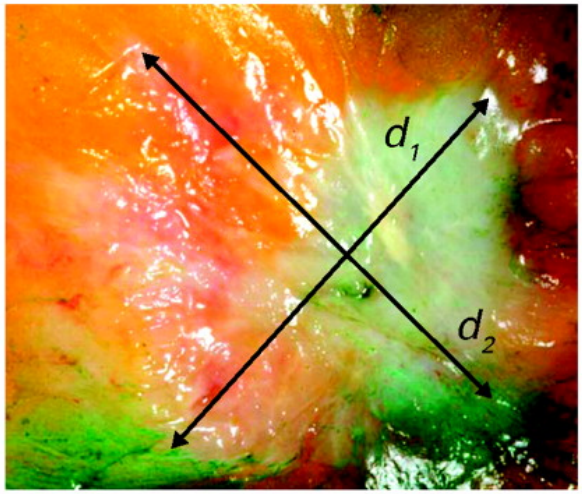

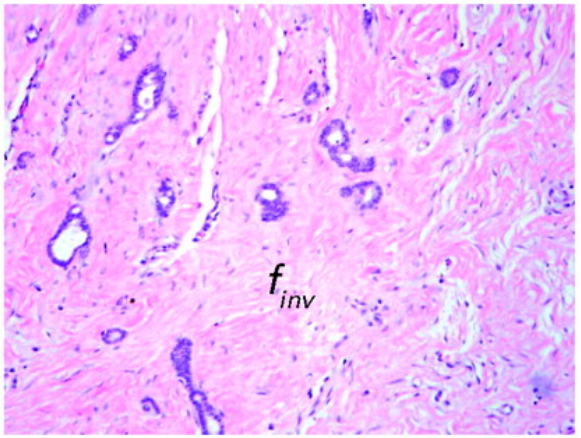

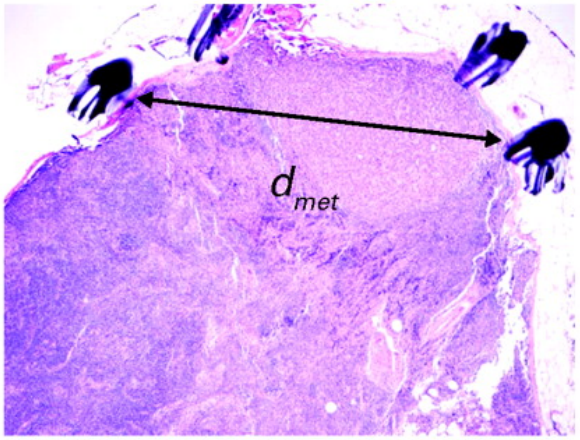

Variable	Hazard Ratio (95% CI)	*P*
Primary tumor bed dimensions ($\sqrt{d_1 d_2}$)	1.24 (1.04 to 1.48)	.02
Cellularity fraction of invasive cancer (f_{inv})	7.37 (2.16 to 25.1)	.001
Size of largest metastasis (d_{met})	1.17 (0.99 to 1.38)	.06
No. of positive lymph nodes	1.11 (1.04 to 1.19)	.002

- Cellularity of residual carcinoma over the tumor bed
- Presence of lymph node metastasis
- Size of the largest lymph node metastasis

Residual Cancer Burden

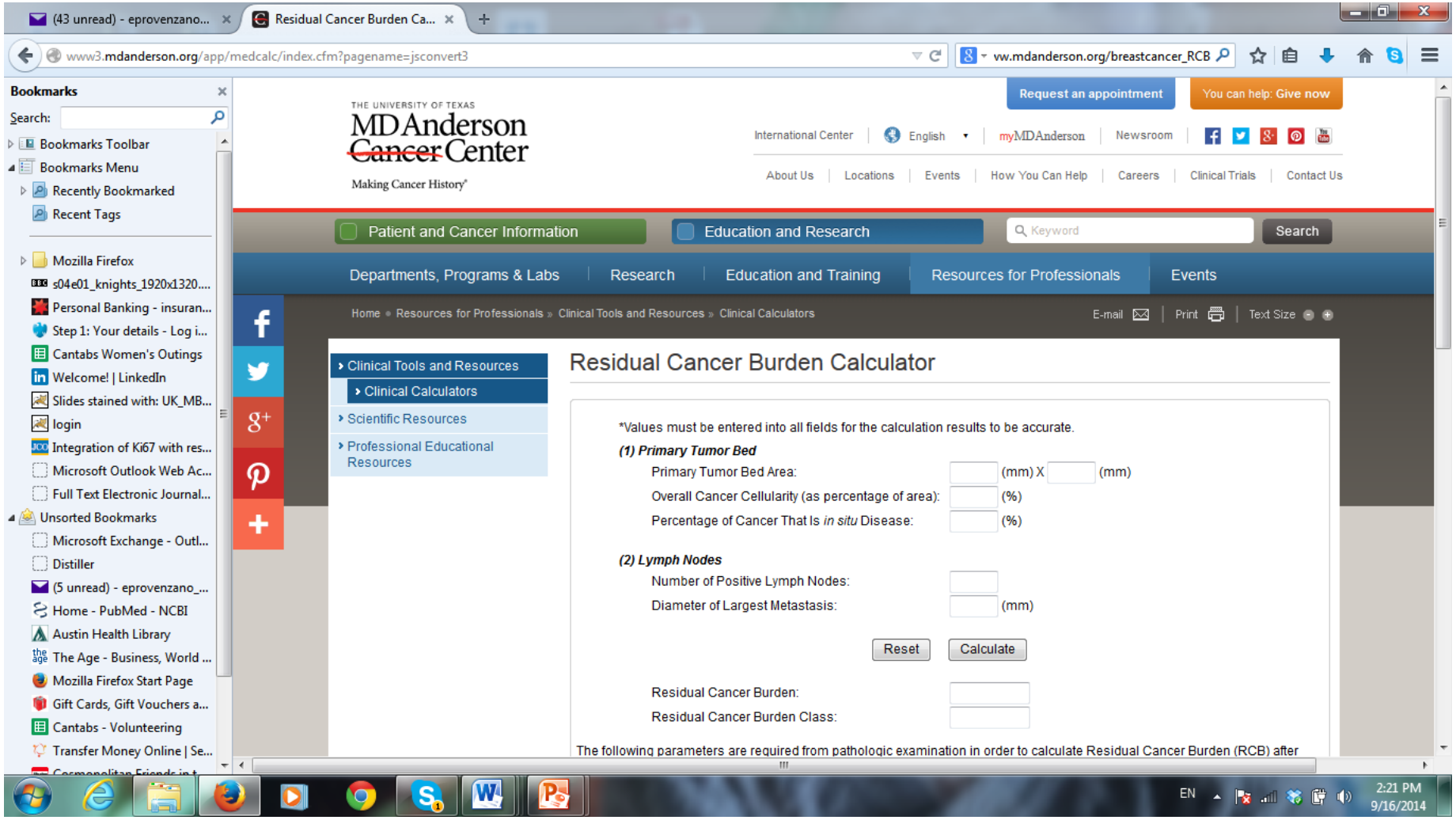

Systems of Categorizing Response To Neoadjuvant Treatment

Residual Cancer Burden System (MDACC)

RCB-0 No carcinoma in breast or lymph nodes (pCR)

RCB-1 Minimal residual disease (marked response)

RCB-2 Moderate response

RCB-3 Minimal or no response (chemoresistant)

Residual Cancer Burden

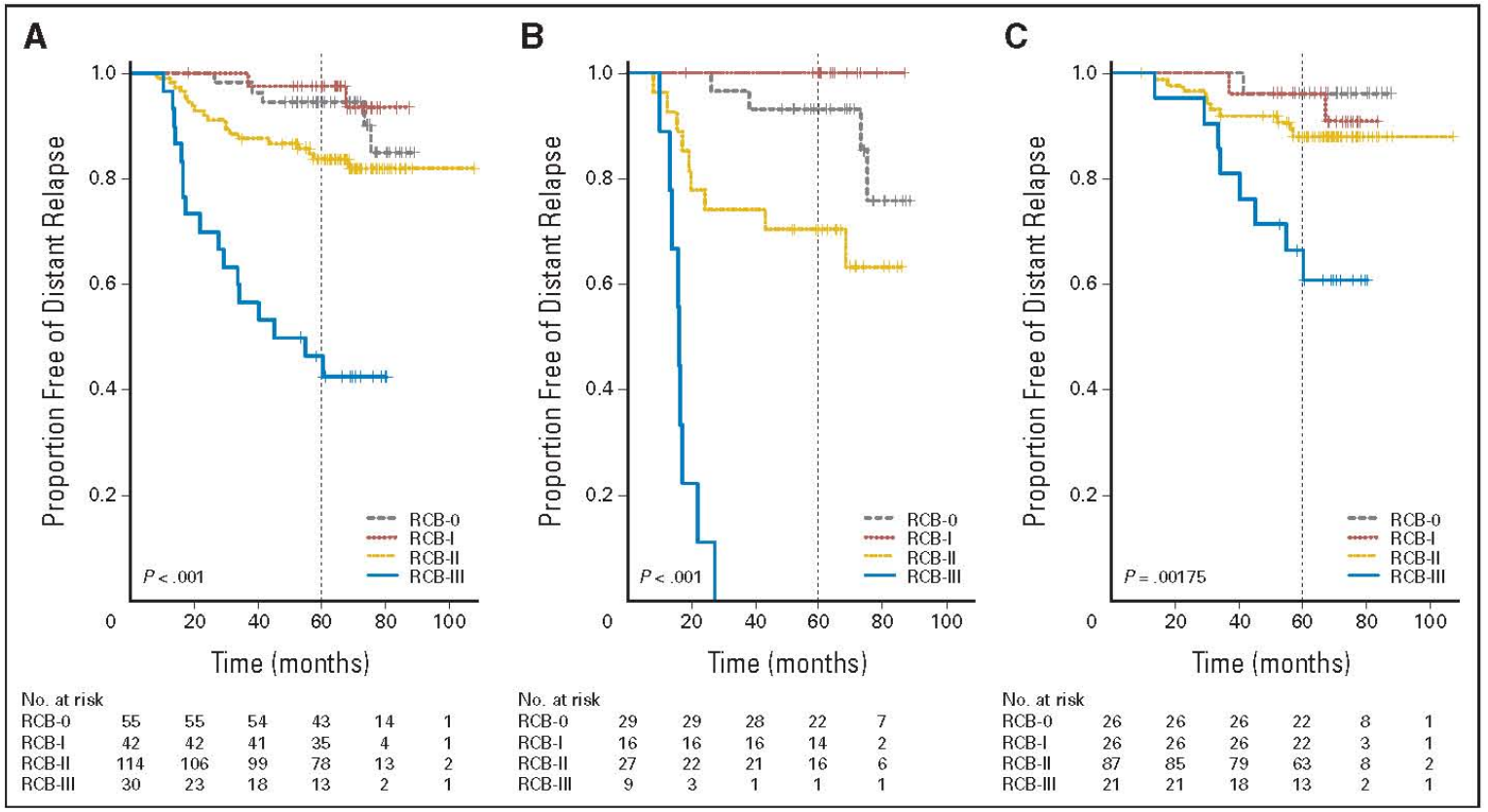

Likelihood of distant relapse in patients with residual cancer burden
A: entire paclitaxel plus fluorouracil, doxorubicin, and cyclophosphamide cohort
B: subset without adjuvant hormone treatment
C: subset who received adjuvant hormone treatment

J Clin Oncol. 25(28):4414-22, 2007

What do we look at in the pathologic examination after NAC?

All prognostic factors important before treatment are also important after treatment

- Residual Tumor pattern
- Tumor size
- LVI
- Lymph node status
- Histologic type and grade
- Tumor biomarkers

Neoadjuvant Chemotherapy

- Identification of “Tumor Bed” essential
- Can be very difficult if there is a marked clinical/imaging response
- Requires thorough evaluation

Tumor Bed

How extensively these specimens need to be sampled?

- If gross tumor is present limited sampling is adequate to establish the presence, size and cellularity of residual tumor. 1-2 sections/cm of tumor is reasonable
- If tumor bed is ill defined more extensive sampling is necessary

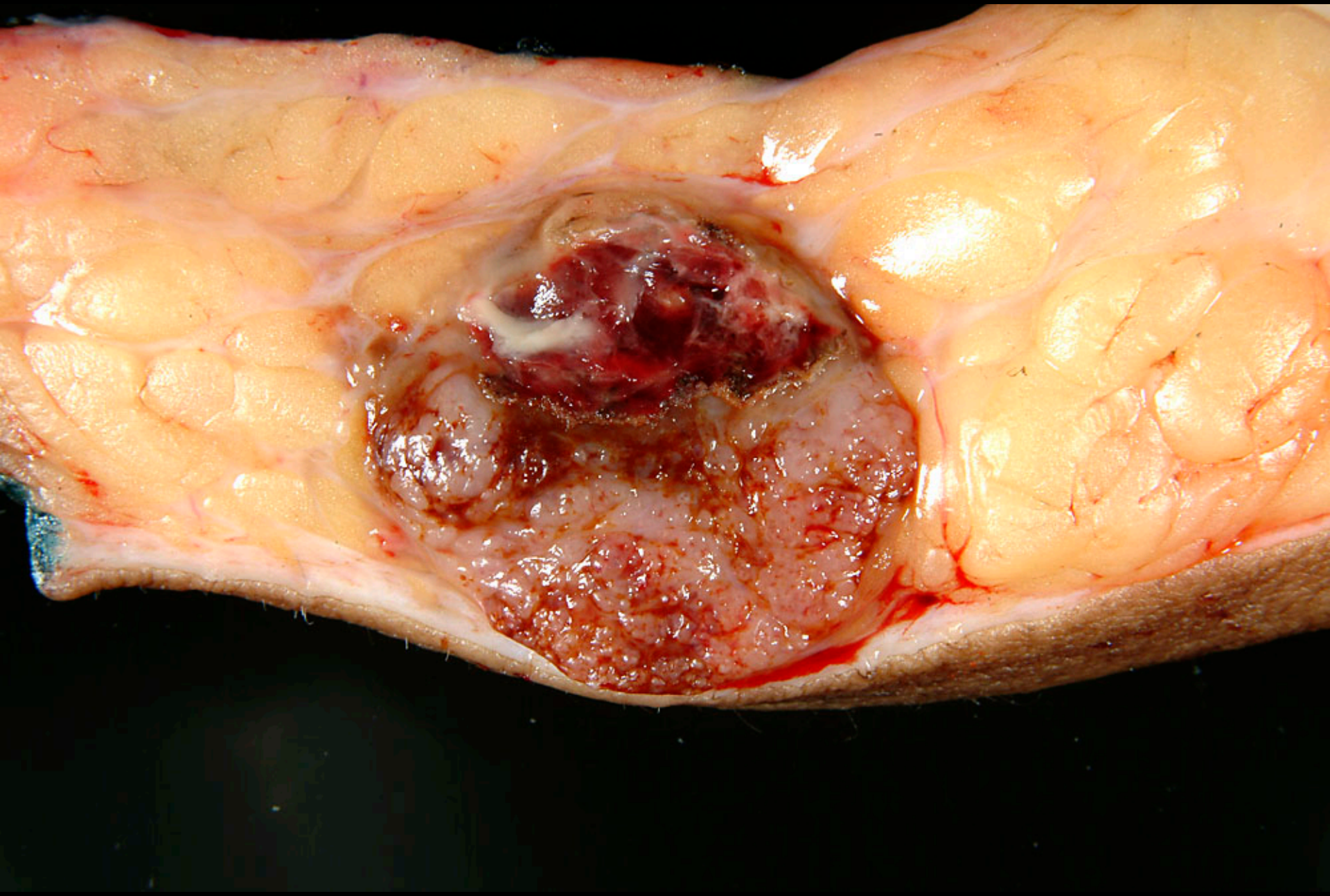

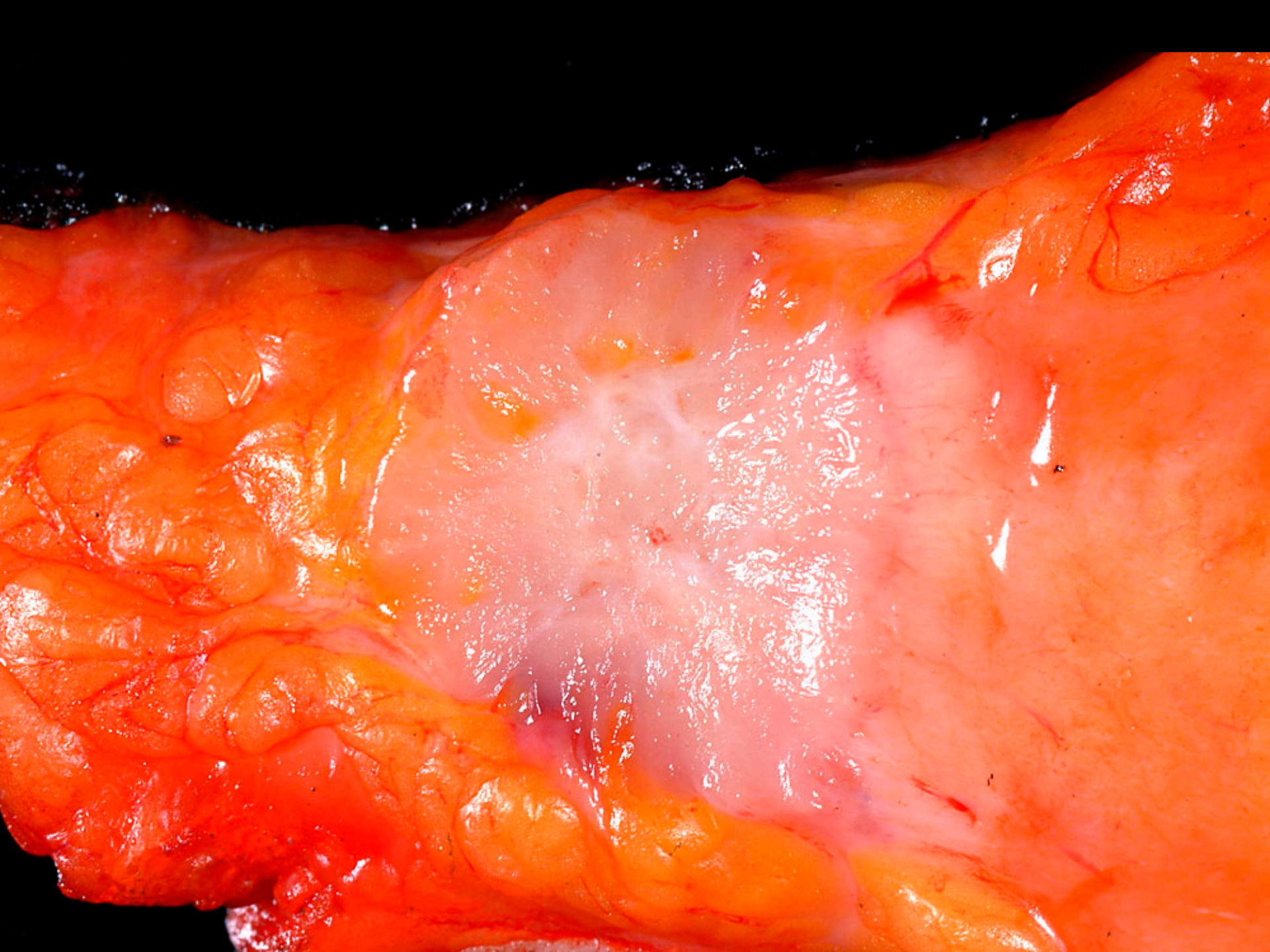

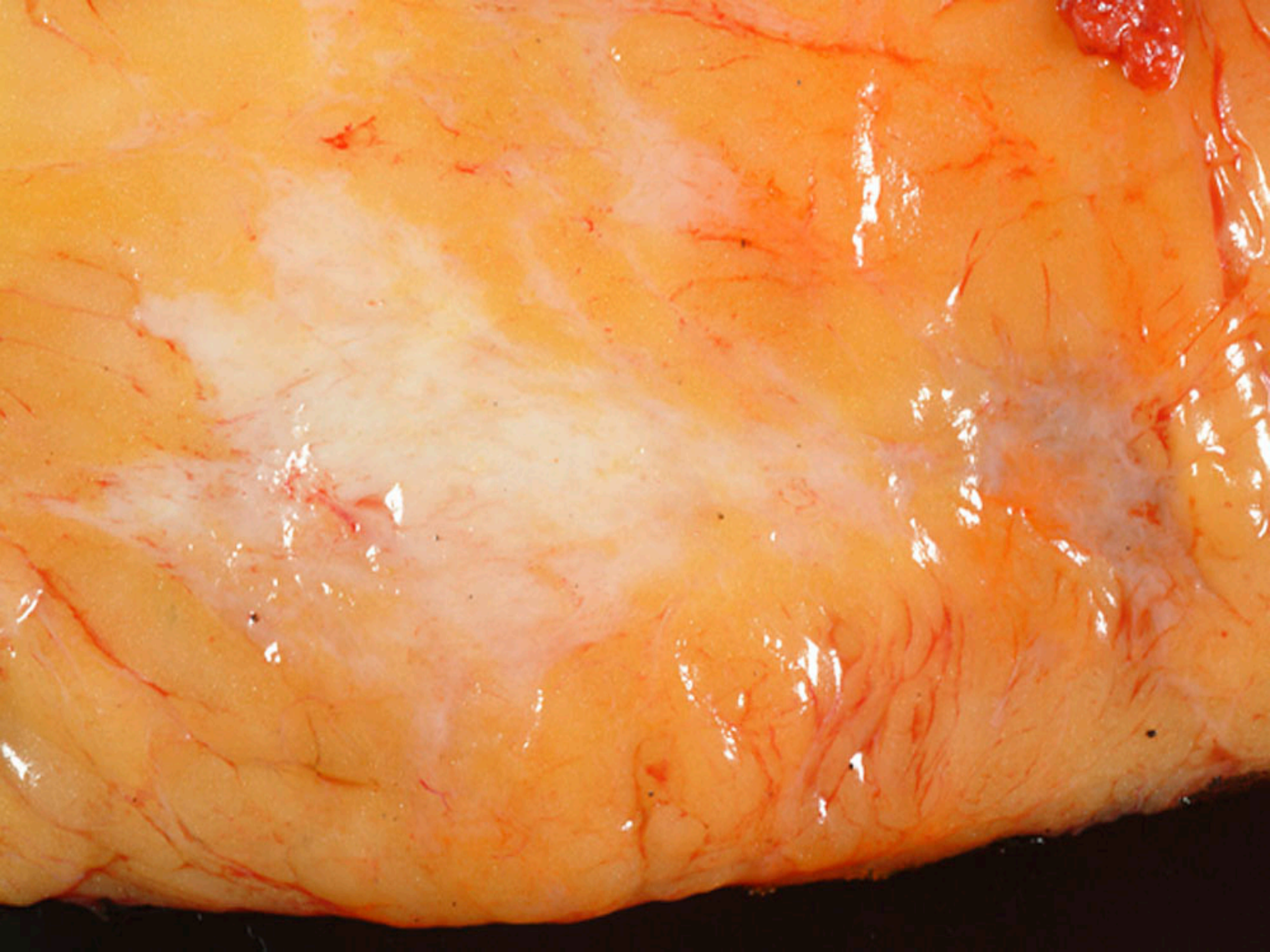

Placement of clip prior to treatment is very helpful

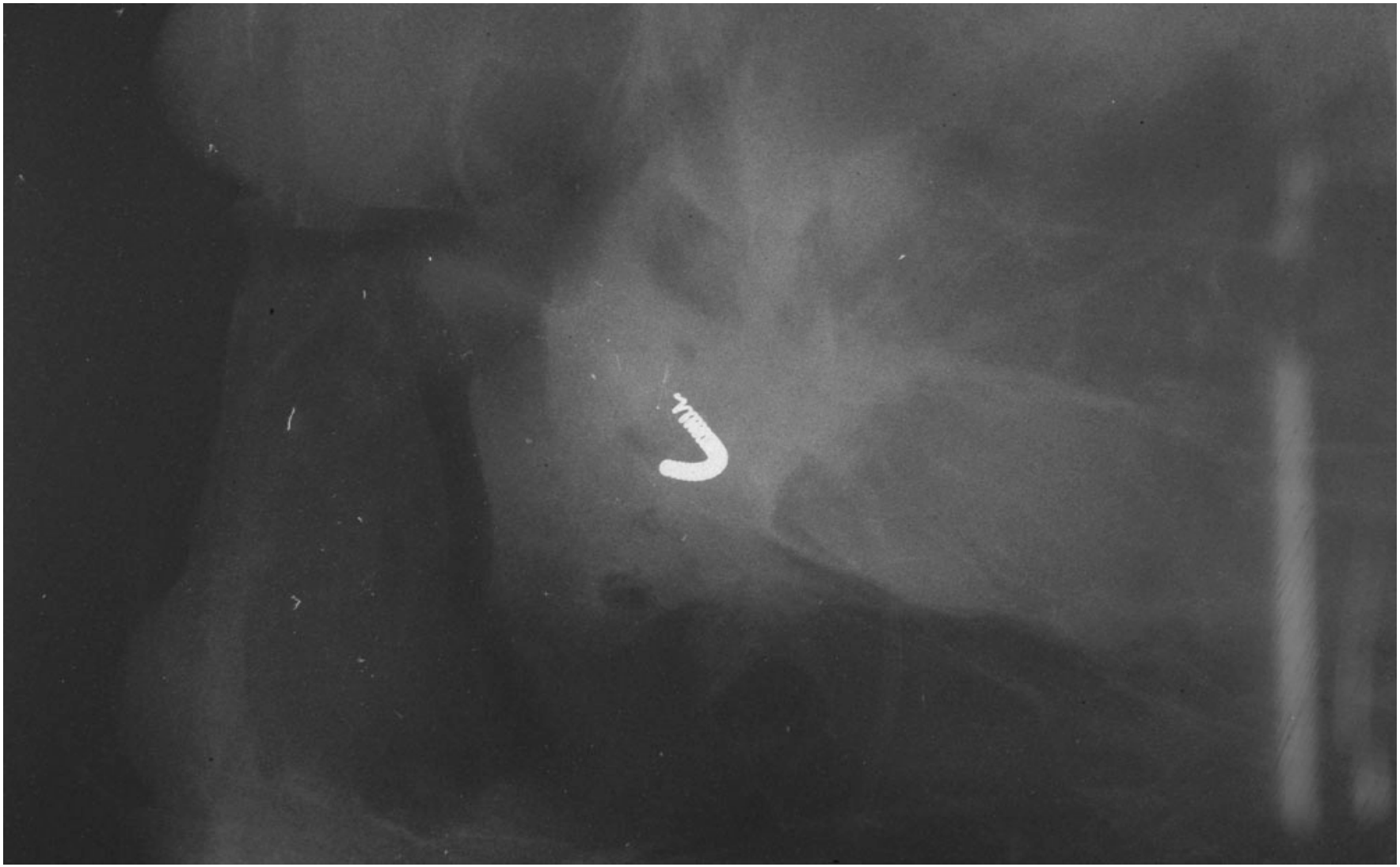

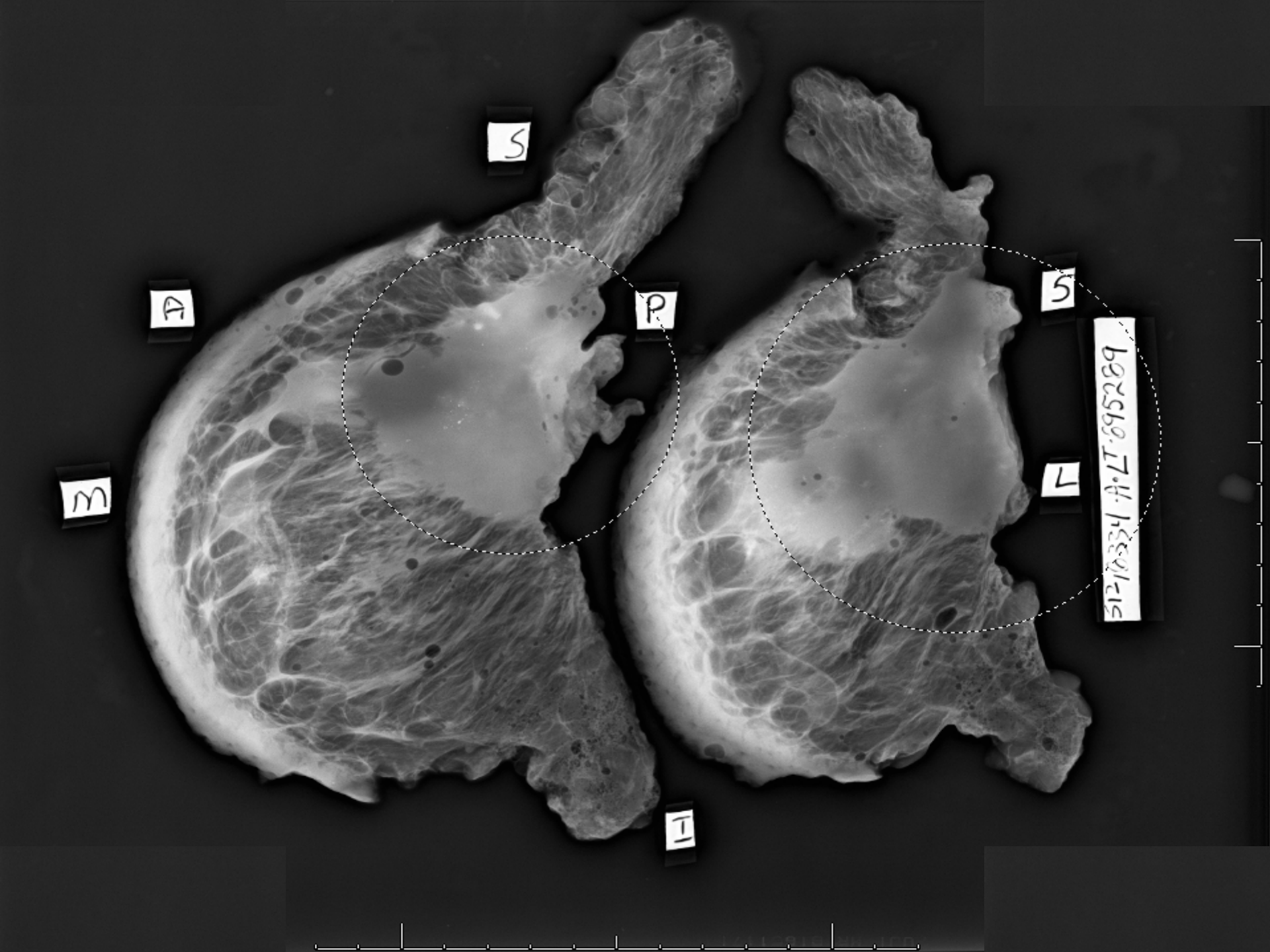
S
A
P
M
I
S
L
512-10334-A-LT-695289

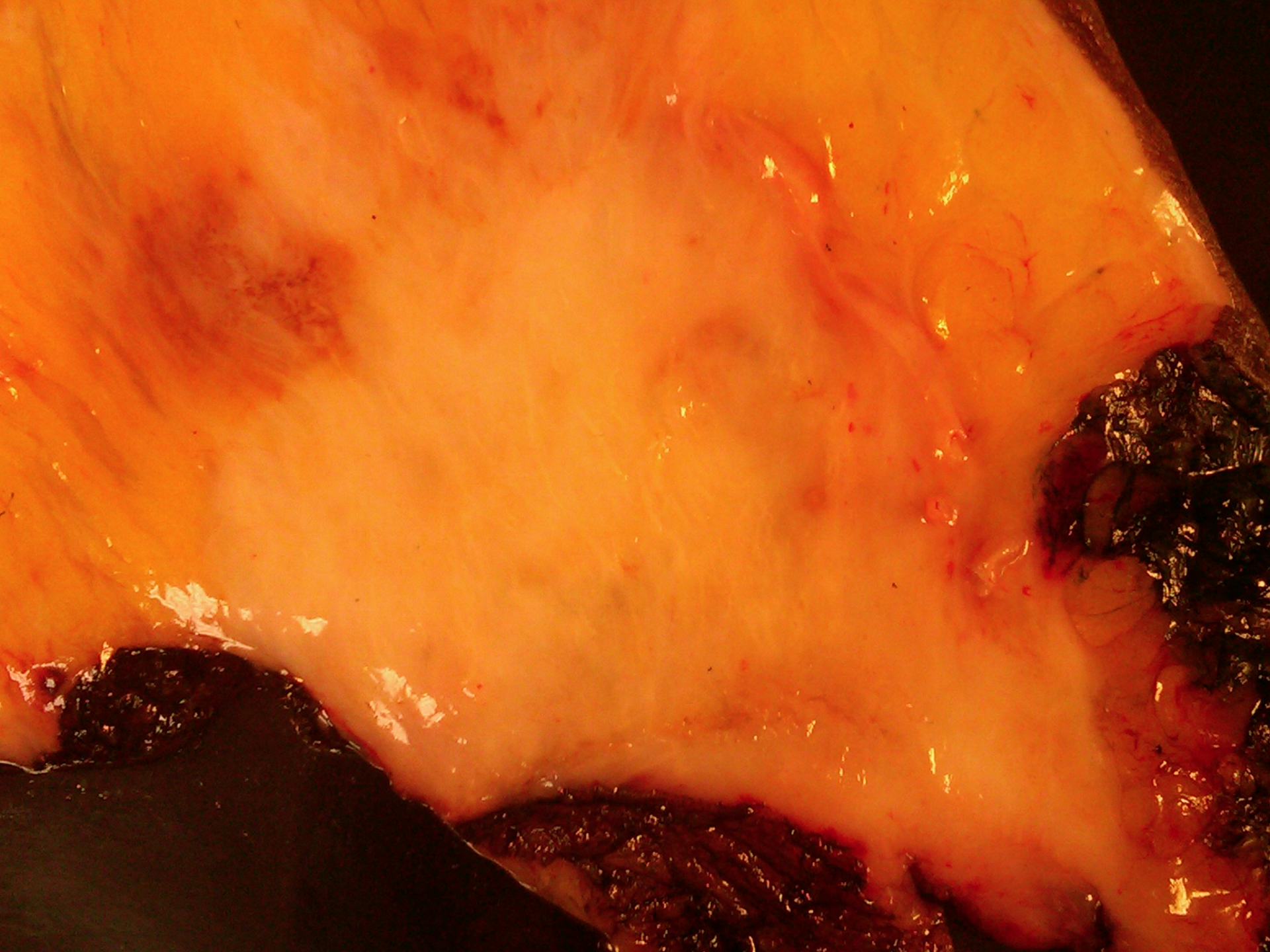

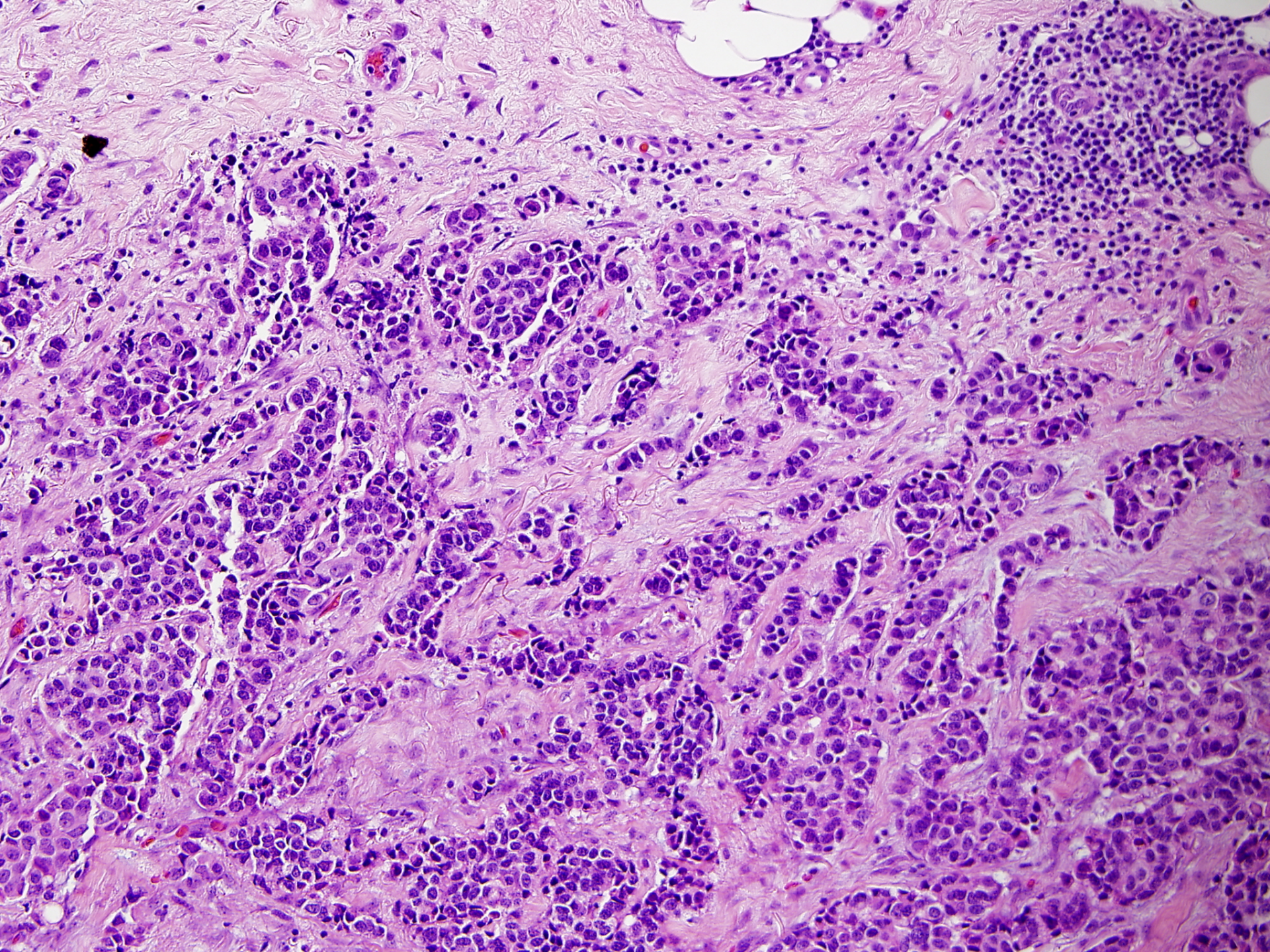

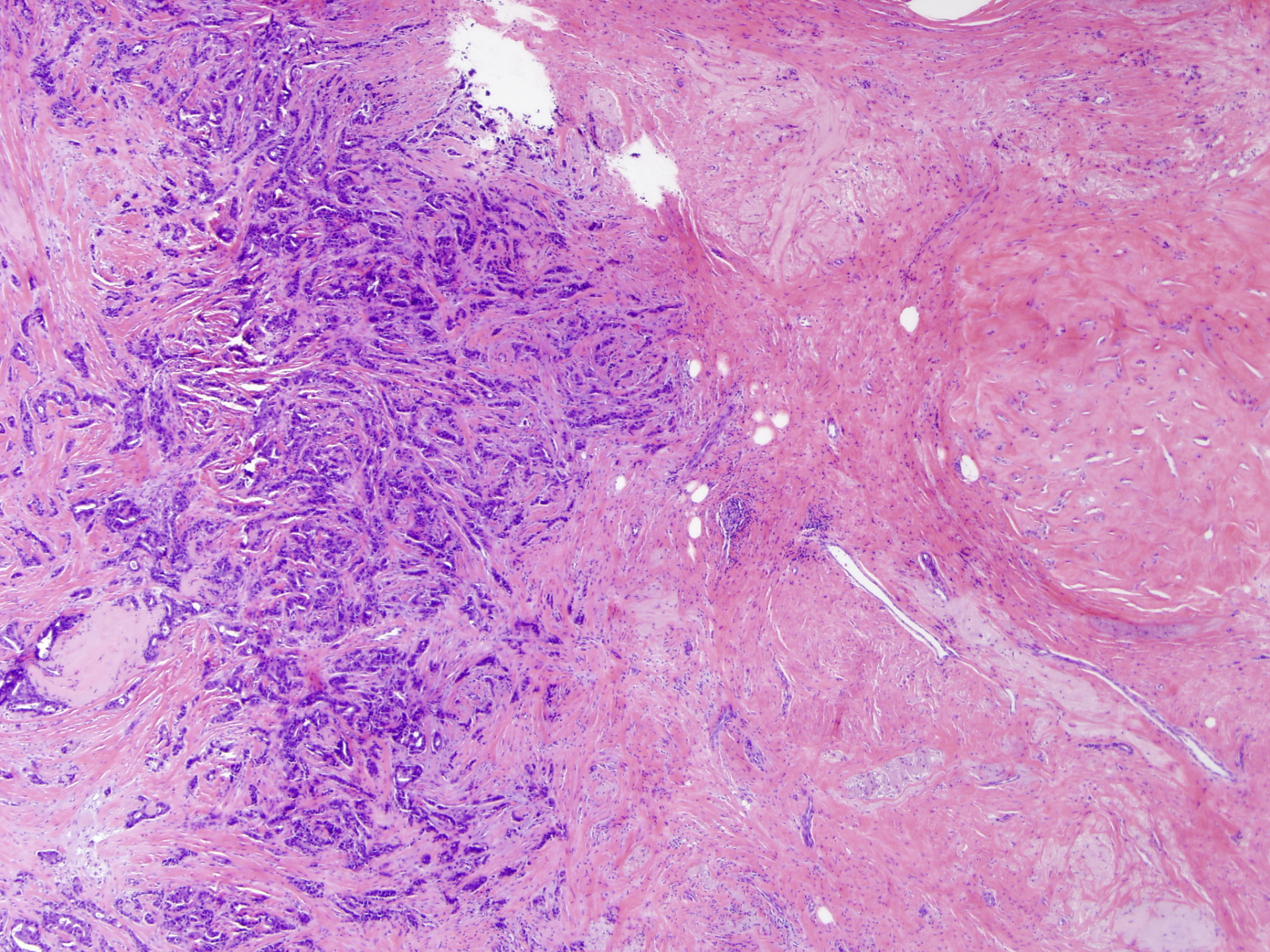

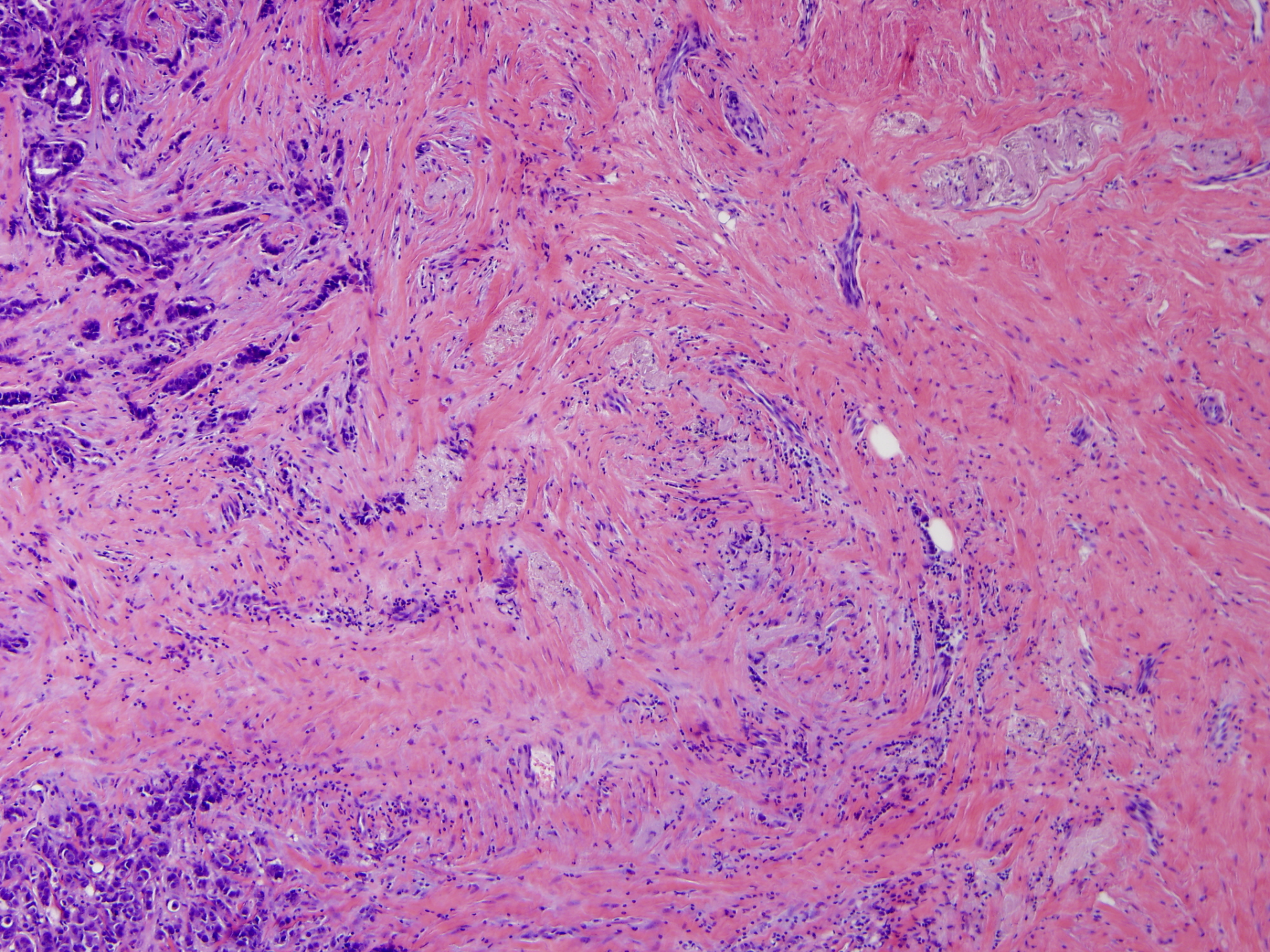

Neoadjuvant Chemotherapy

Histopathological Changes

- Lobular atrophy and calcification
- Epithelial atypia
- Fibrous stromal involution
- Inflammation
- Cytoplasmic vacuolization
- Pigmented and foamy macrophages
- Interlobular fibrosis
- Fat necrosis
- Duct ectasia

Neoadjuvant Chemotherapy

Cytomorphologic Changes

Similar changes can occur in lymph node metastases

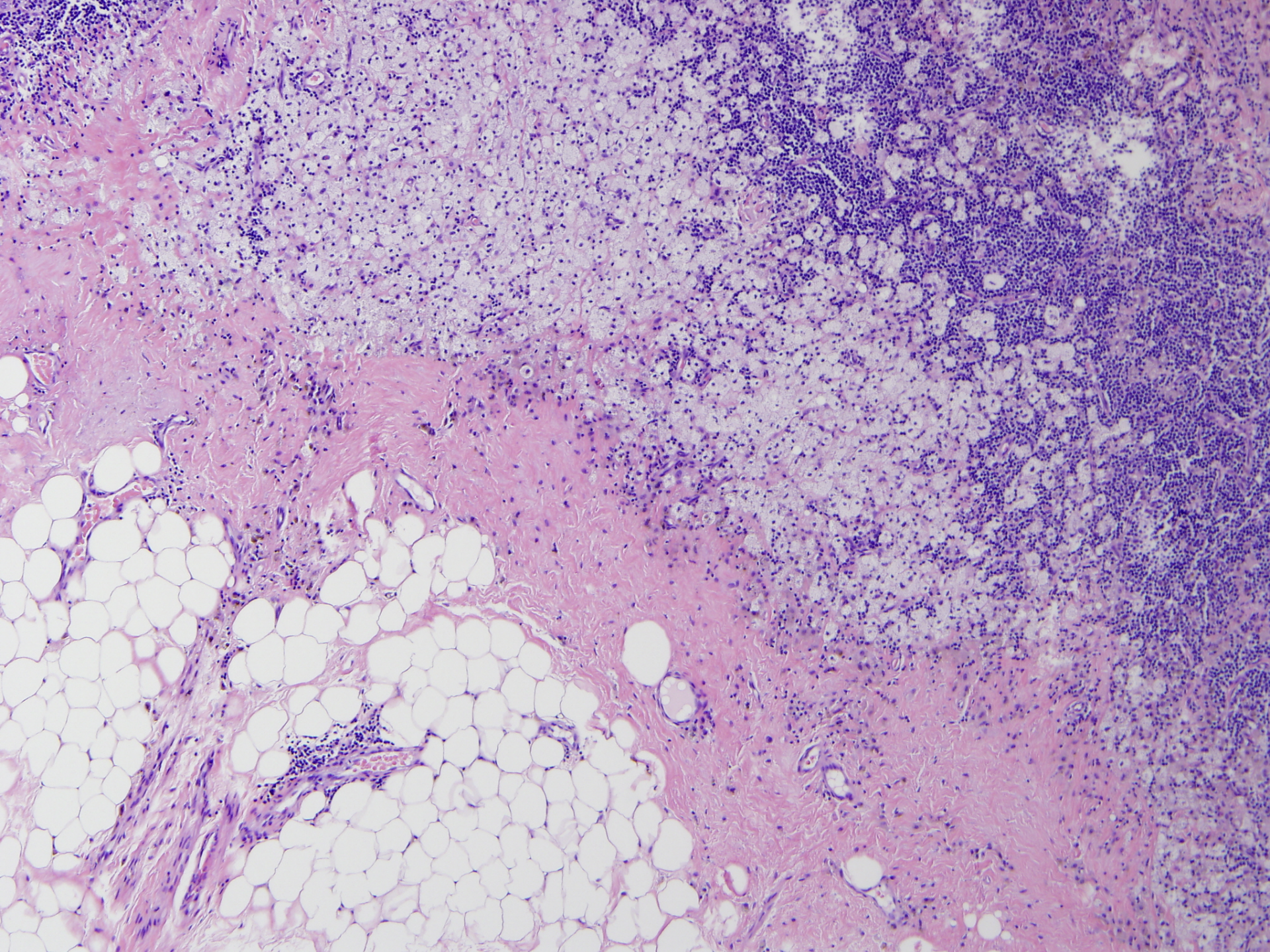

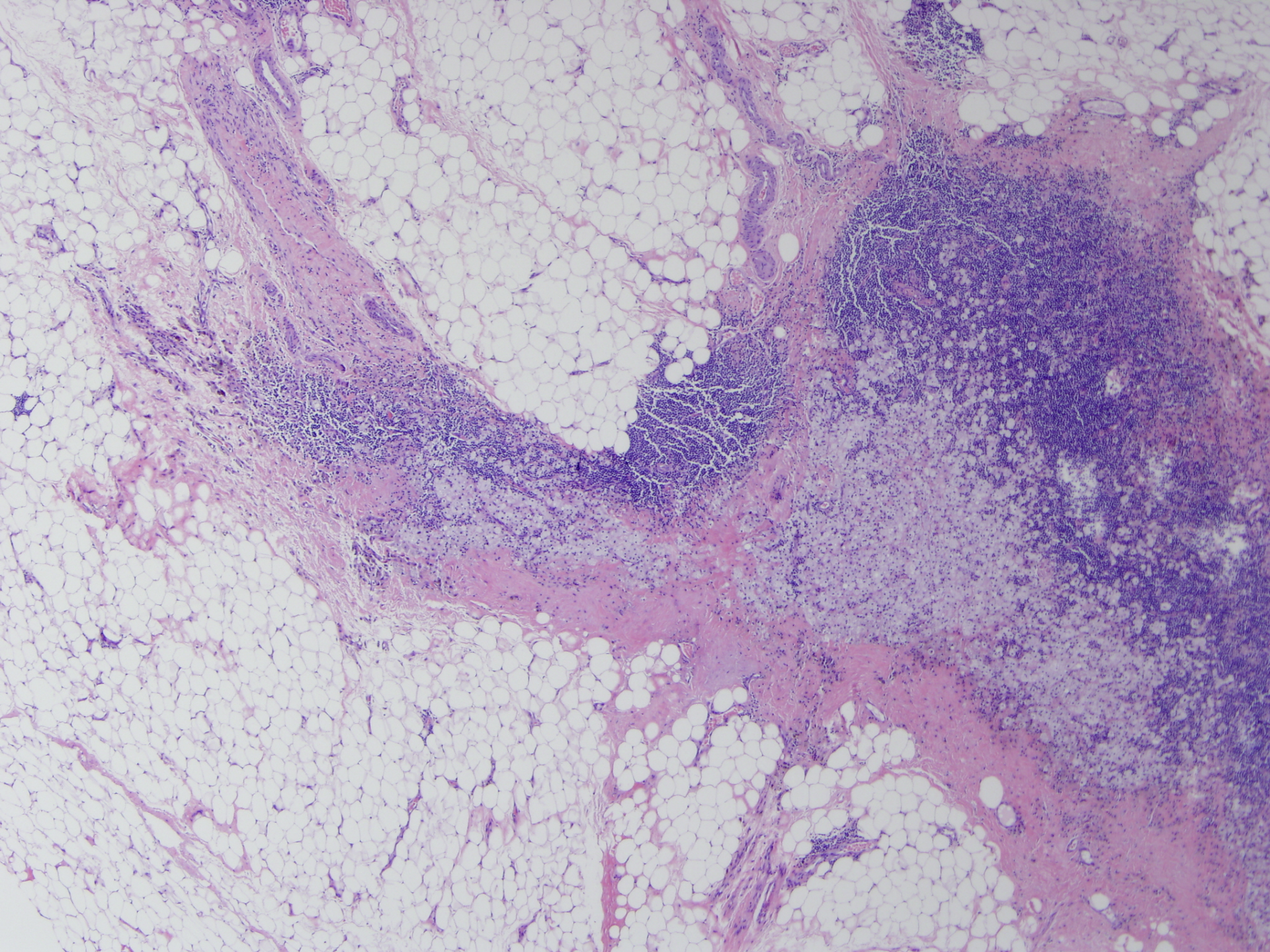

Neoadjuvant Chemotherapy

Lymph Node Metastases

- Number of positive nodes
- Even small clusters are significant
- Evaluation of ENE can be difficult

Neoadjuvant Chemotherapy

Take Home Messages

- NAC is being used more frequently
- Pathologic response is an important predictor of survival
- pCR provides the best prognosis

Neoadjuvant Chemotherapy

Take Home Messages

- Pathologists should be familiar to ensure that chemotherapy induced changes in non-neoplastic tissue is not mistaken for residual tumor or that residual tumor is not confused with non-neoplastic cells