بسم الله الرحمن الرحيم

The role of three dimensional transrectal ultrasonography (3-D TRUS) and power Doppler sonography in prostatic lesions evaluation

Introduction

- The ability to differentiate between carcinoma confined to the prostate and the extracapsular spread of tumor is the key point for management. (Enlund et al 1990) Radical prostatectomy is performed for carcinoma localized to the prostate but if the tumor extends beyond the prostatic capsule ,other treatment options like radiotherapy (external beam irradiation or Brachytherapy),Hormonal therapy will be tried (Boccon et al 2003).

- Previous studies predict extracapular spread of tumor through elevated serum PSA > 10 ng/ml ,increased number of positive cores in guided biopsies which means increased tumor volume , detection of perineural invasion in biopsy samples and Gleason score =7 or more (Tarjan et al 2006)

- ECE of prostate cancer can lead to failure of radical prostatectomy and every attempt should be made to localize the tumor and assess its extensions preoperatively.
- It is very disappointing to inform the patient that he has recurrent cancer or the cancer will recur after he performed radical prostatectomy and after he was exposed to all operative and post operative risks including impotence and urinary incontinence

- Our current study is an attempt to localize the prostate cancer and to assess its local extensions prior to surgery using transrectal ultrasound assisted with power Doppler and 3D capabilities in addition to TRUS guided biopsy and to distinguish malignant from common prostatic pathologies like inflammation and BPH

The aim of the work:-

To evaluate the value of three dimensional (3D), two dimensional (2D) as well as power Doppler transrectal ultrasound (TRUS) in the diagnosis of different prostatic lesions and in the assessment of local extensions of prostatic cancer

Patients and Methods

2-D TRUS, power Doppler sonography and 3D TRUS were performed for 100 patients. All patients were complaining of lower urinary tract obstructive or irritative symptoms or they had abnormal digital rectal examination (DRE) and or they had elevated serum prostatic specific antigen (PSA) level.

Biopsies were performed for 77 cases showing suspicious areas within the prostate during 2-D,3-D TRUS, abnormal flow pattern with power Doppler sonography and for cases with abnormal DRE or elevated serum total PSA >4 ng/ml or when the percent-free PSA is 10% or less after taking patient consent. The patients were instructed to take antibiotics before and after the procedure, to stop any anticoagulants or nonsteroidal anti-inflammatory drugs and to do an enema before the procedure.

Eight tissue samples were taken from different prostatic regions (6 tissue samples were taken from the midlobe parasagittal planes bilaterally at the base, middle and apical prostatic zones and 2 samples from the lateral aspect of each lobe) in addition, targeted tissue samples were taken from the suspicious focal lesions or from the seminal vesicles suspected tumor infiltration observed during transrectal ultrasound.

TRUS and TRUS guided biopsy were performed in an outpatient setting.

In cancer patients, the final diagnosis was reached based on the result of true cut prostatic biopsies, target biopsies of the region of interest, post radical prostatectomy pathological reports, cystoscopy and biopsy of urinary bladder in cases of suspected urinary bladder infiltration, targeted seminal vesicle biopsy in cases with suspected infiltration and post radical prostatectomy pathological reports

In patients with BPH, estimation of adenomata volume with 2-D and 3-D TRUS was compared with the estimated adenoma volume after transurethral resection of prostate or open prostatectomy . An estimated% error in the volume calculation of adenoma using 2-D and 3-D TRUS was calculated by dividing the difference between the estimated 2-D or 3-D ultrasound volume and the estimated postoperative volume of adenoma/postoperative volume of adenoma.

Results

.

2-D Transrectal US aided with power Doppler and 3-D TRUS were performed for 100 patients, the final diagnosis was reached in 77 patients.

Eighteen patients showed prostatic carcinomas, one patient showed prostatic sarcoma. 38 patients showed benign prostatic hyperplasia (BPH). Twenty patients diagnosed as prostatitis.

In patients with biopsy proved prostatic cancer 3-D TRUS showed estimated sensitivity 78.9% and specificity 94.8% with total accuracy 90.9% with respect to an estimated sensitivity 63.1%, specificity 86.2% and total accuracy 80.5% with 2-D TRUS

3-D TRUS clearly identifies the extraprostatic spread to the periprostatic fat at 3 out of 3 patients, infiltration to the seminal vesicles in 3 out of 3 patients, infiltration of the base of urinary bladder in 2 out of 2 patients and also the presence of capsular breaks in 4 patients out of 5.

The results were equivocal or negative in 3 patients by 2D ultrasonography for detecting intra glandular lesions and were negative in detecting capsular breaks in 3 patients out of 5 proved by biopsy but it was able to detect all patients with infiltration to the periprostatic fat planes and the base of urinary bladder and in 2 patients out of 3 with seminal vesicles infiltration .

Both techniques failed to diagnose 2 patients with biopsy proved transitional zone carcinoma and 2 patients with localized intra glandular peripheral zone lesions, possibly due to the isoechoic nature of the lesions in the later.

In patients with benign prostatic hyperplasia (BPH), the postoperative data after transurethral resection of prostatic adenomas or open prostatectomy received and compared with 2-D and 3-D TRUS results showed that 3-D TRUS was superior to 2-D ultrasonography in calculating the volume of adenomas with an estimated error not more than ±6% with regard to an estimated error not more than ±18% for 2-D TRUS.

3-D ultrasound showed excellent delineation of the transitional zone, especially in the coronal plane, which is the blind plane for 2-D ultrasonography.

In patients with prostatitis the combination of color Doppler U/S and 2D ultrasonography or 3D ultrasonography if possible gives better results than either method alone.

Color Doppler U/S helps in identifying the hyperaemic prostatic foci and we suggest that the presence of peri-urethral zone of hyperaemia and irregular lucency is the most valuable sign for the inflammatory group (seen in all of our patients) as well as the presence of congested peri prostatic venous plexus.

Cases Presentation

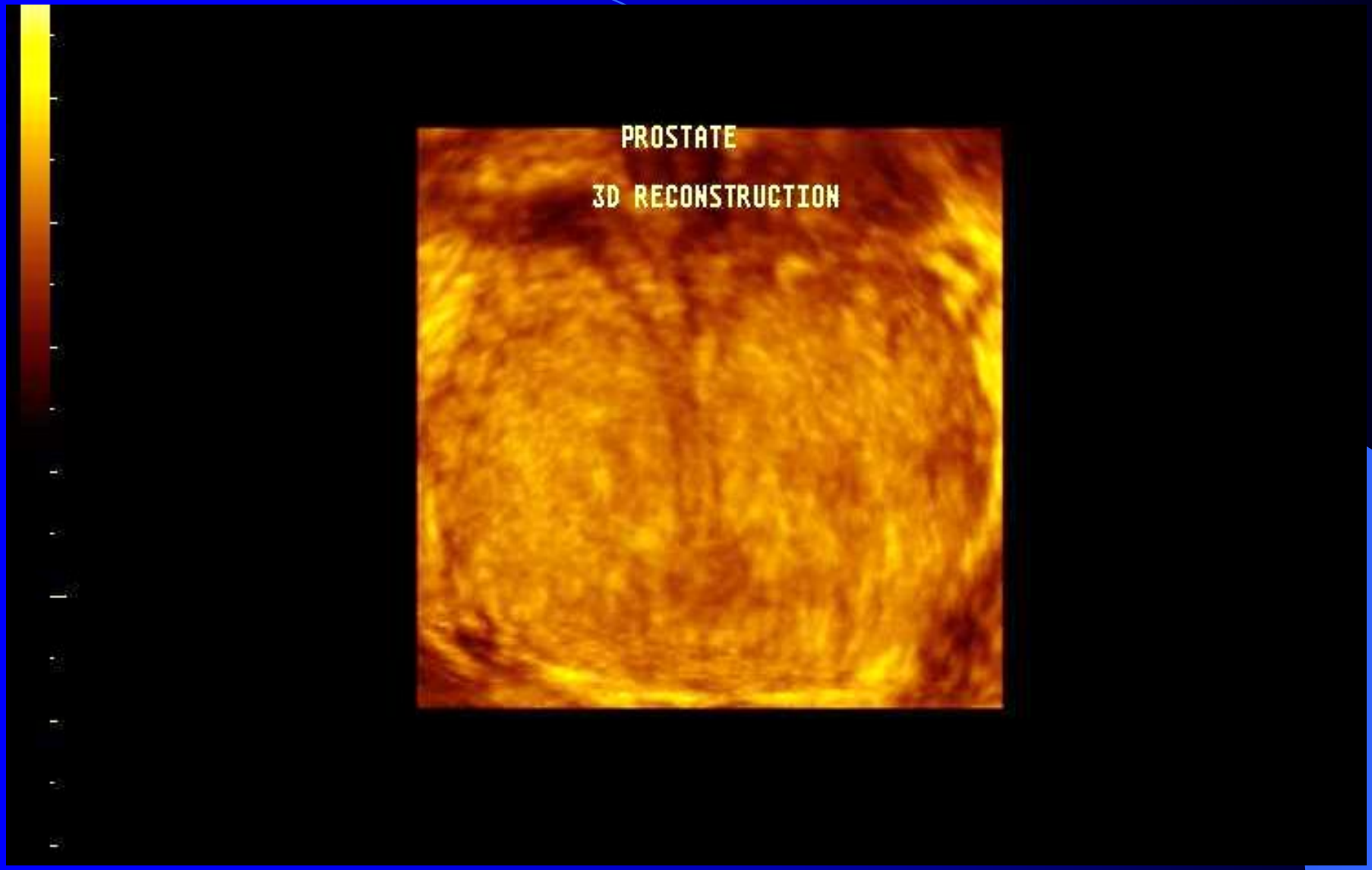
PROSTATE
3D RECONSTRUCTION

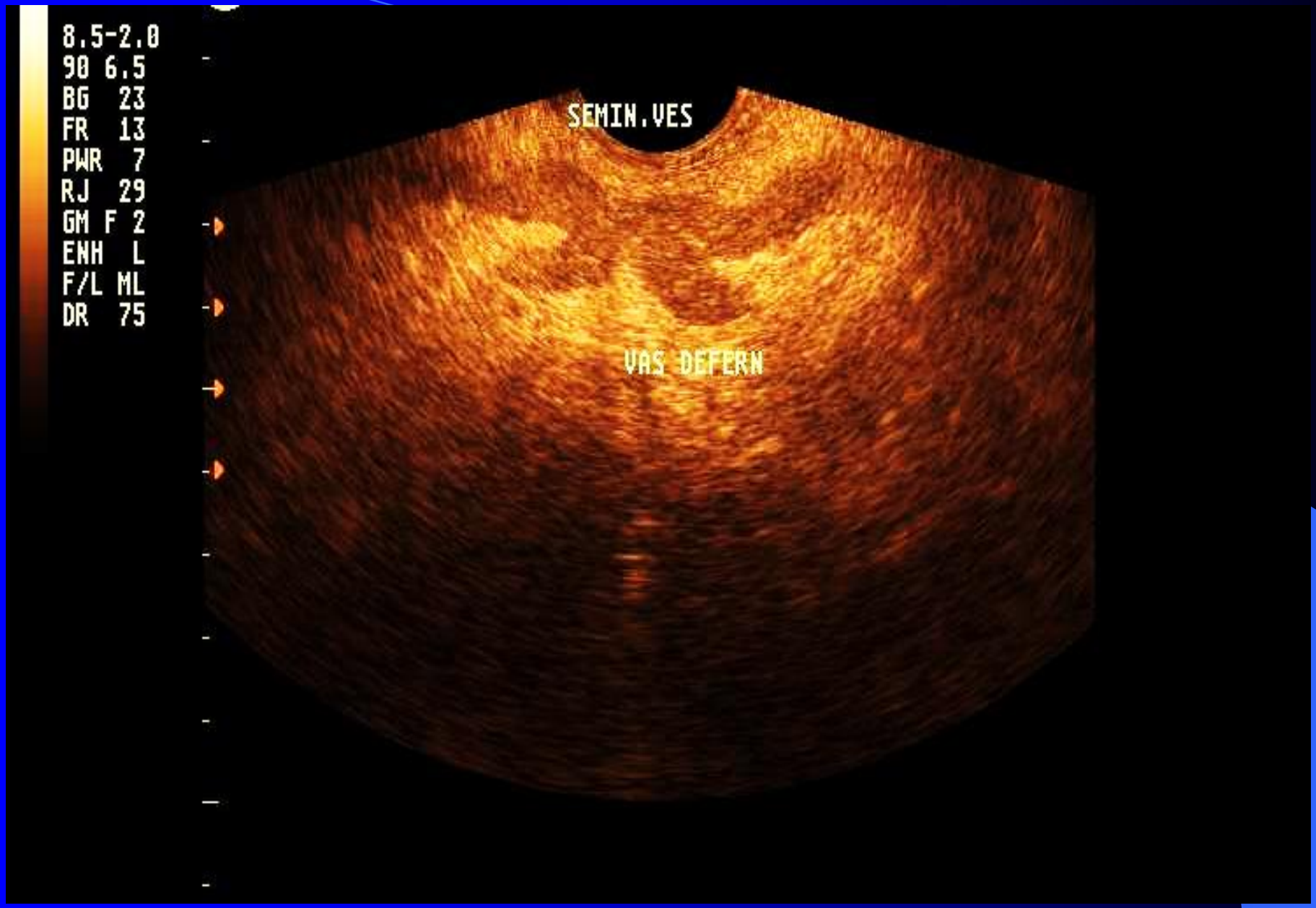
8.5-2.0
90 6.5
BG 23
FR 13
PWR 7
RJ 29
GM F 2
ENH L
F/L ML
DR 75
SEMIN.VES
VAS DEFERN

P.C

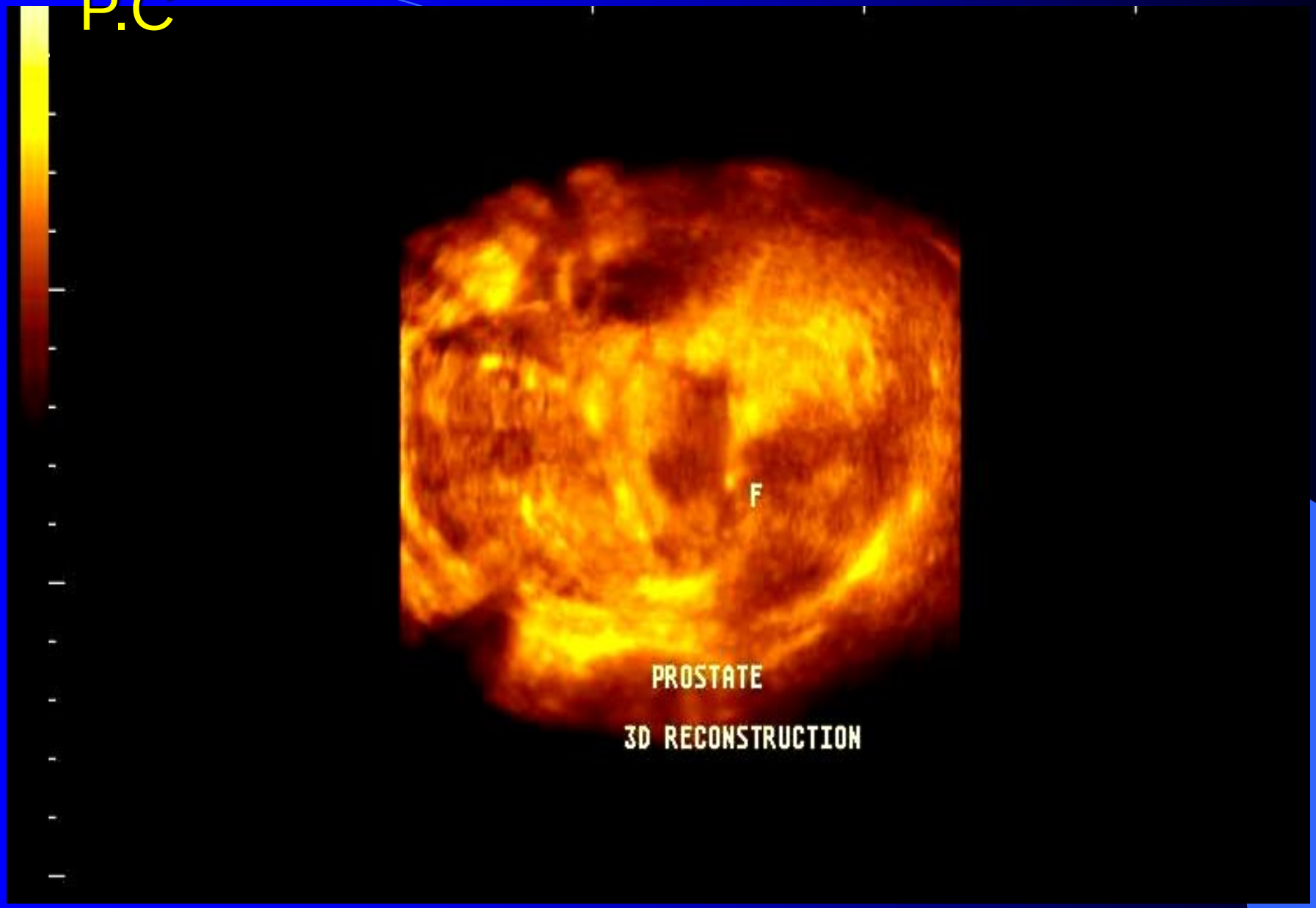

Cancer prostate

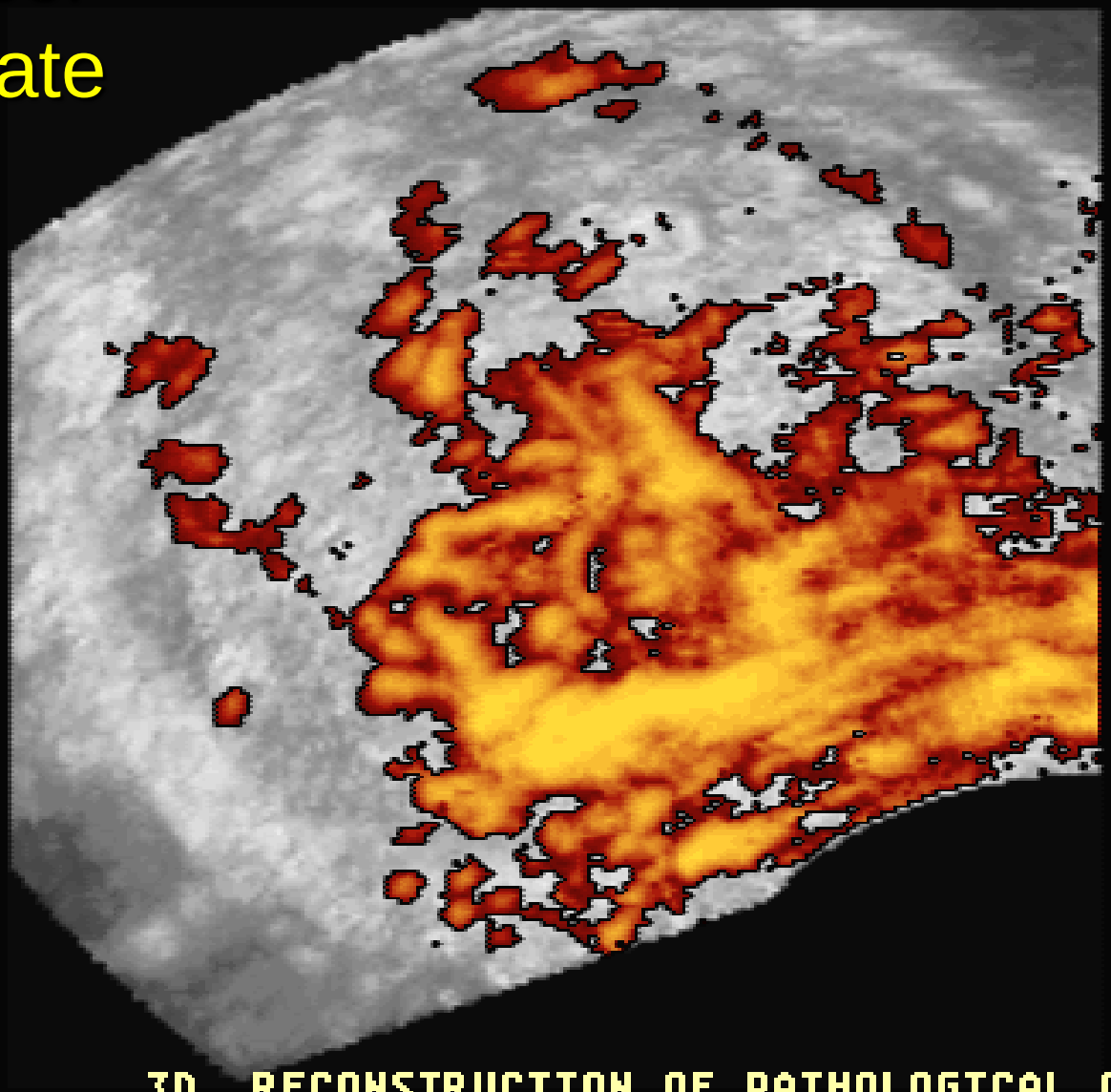

3D RECONSTRUCTION OF PATHOLOGICAL CIRCULATION IN MALIGNANT PROSTATIC MASS

Prostate Cancer -Capsular breaks

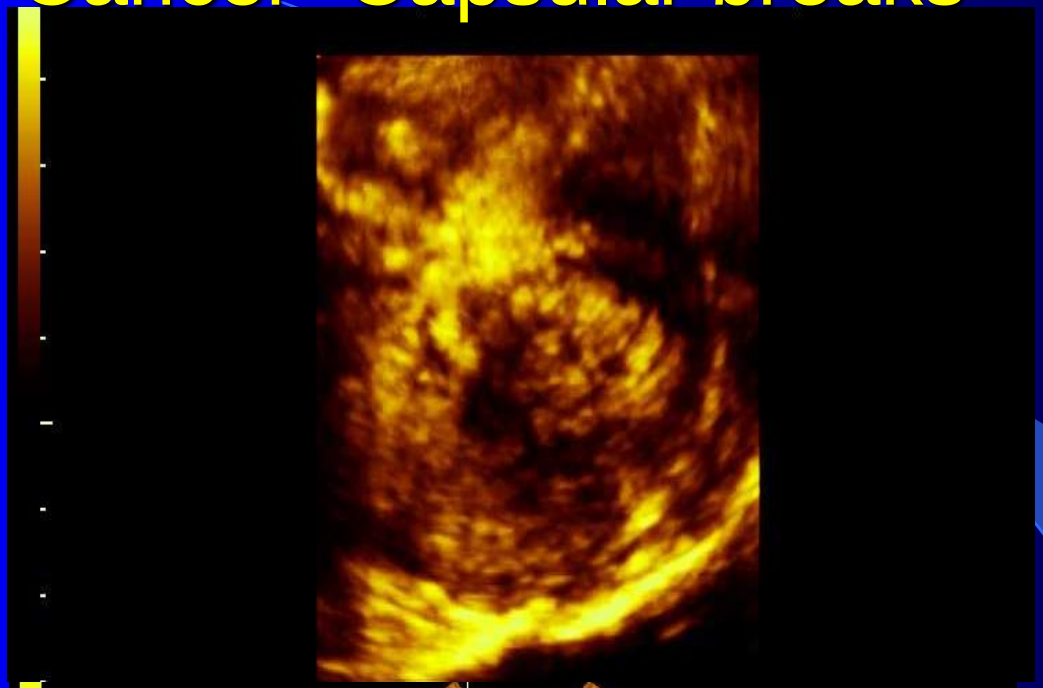

Capsular breaks

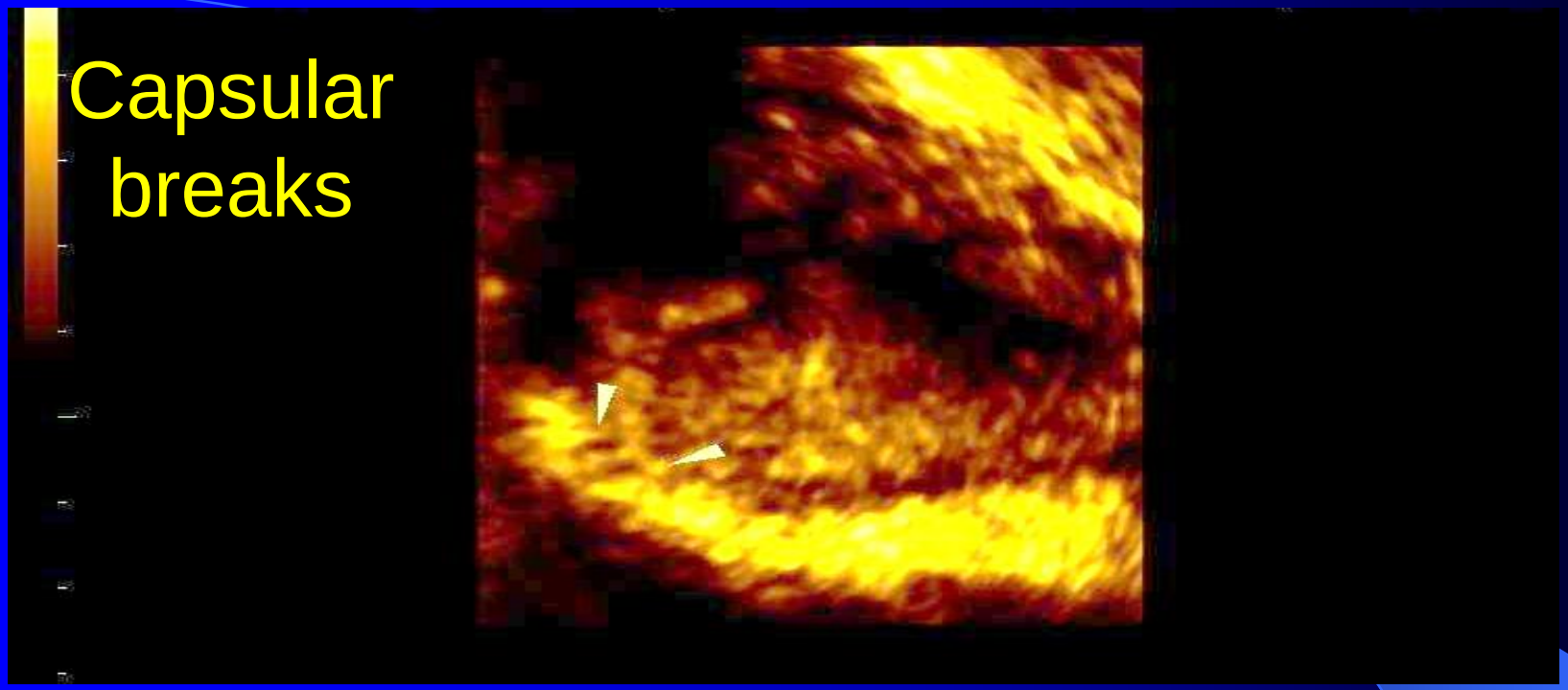

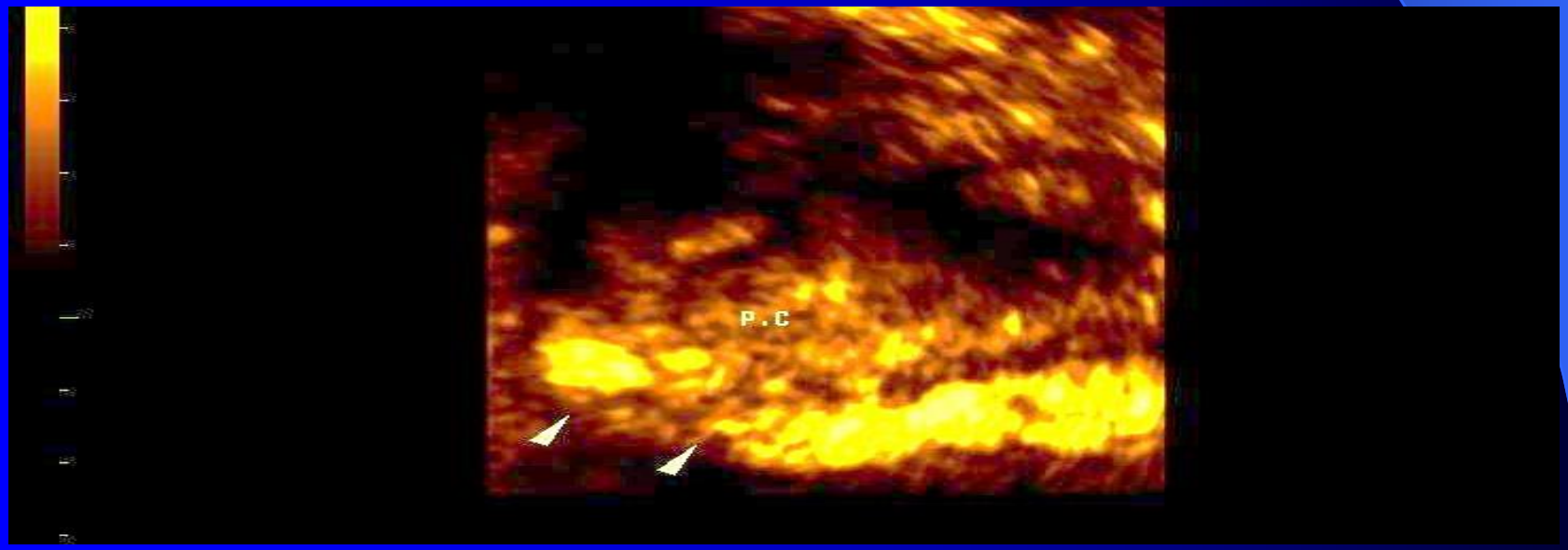

Periprostatic fat planes infiltration

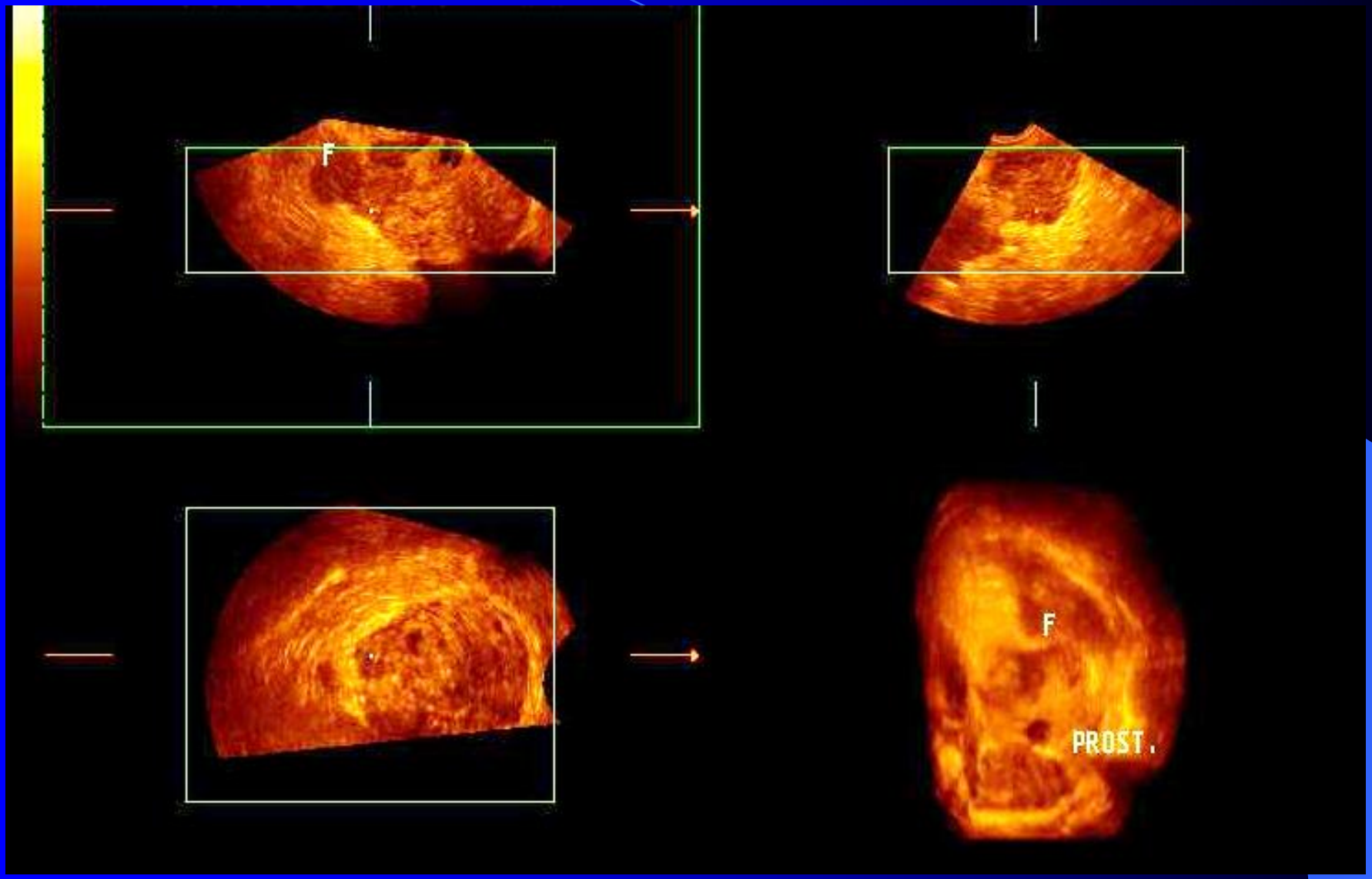

Prostate cancer

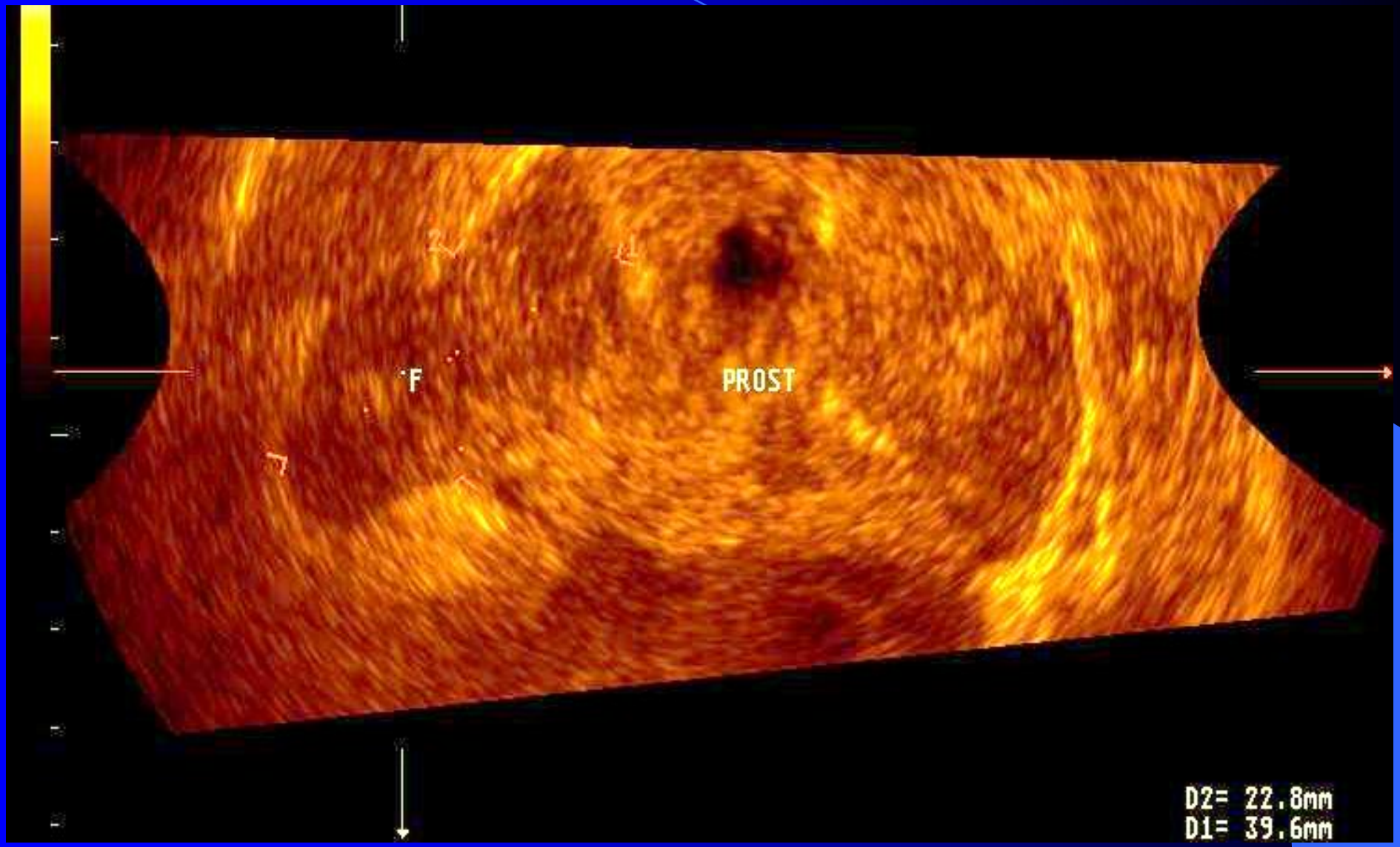

Periprostatic fat planes infiltration

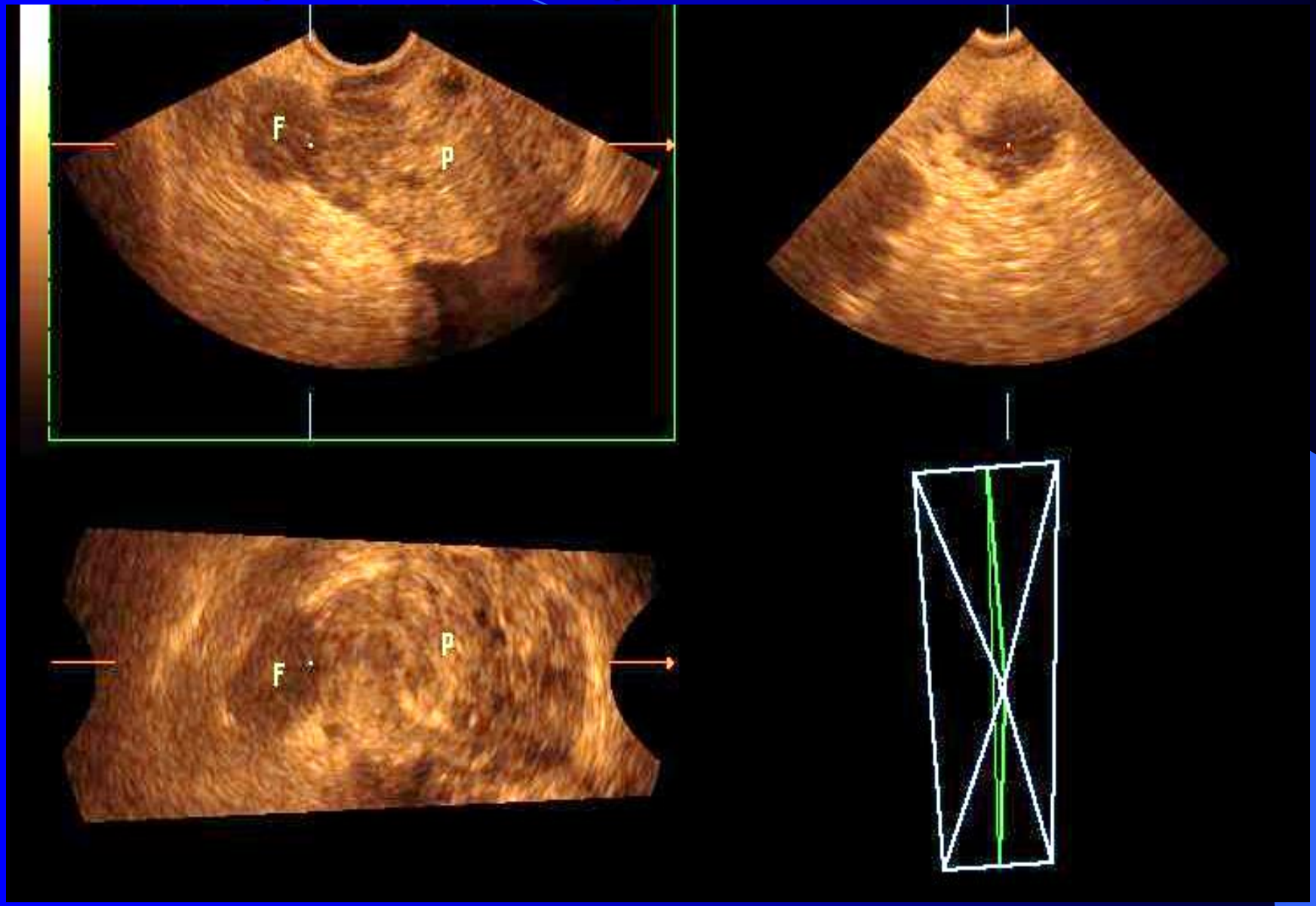

Prostate cancer

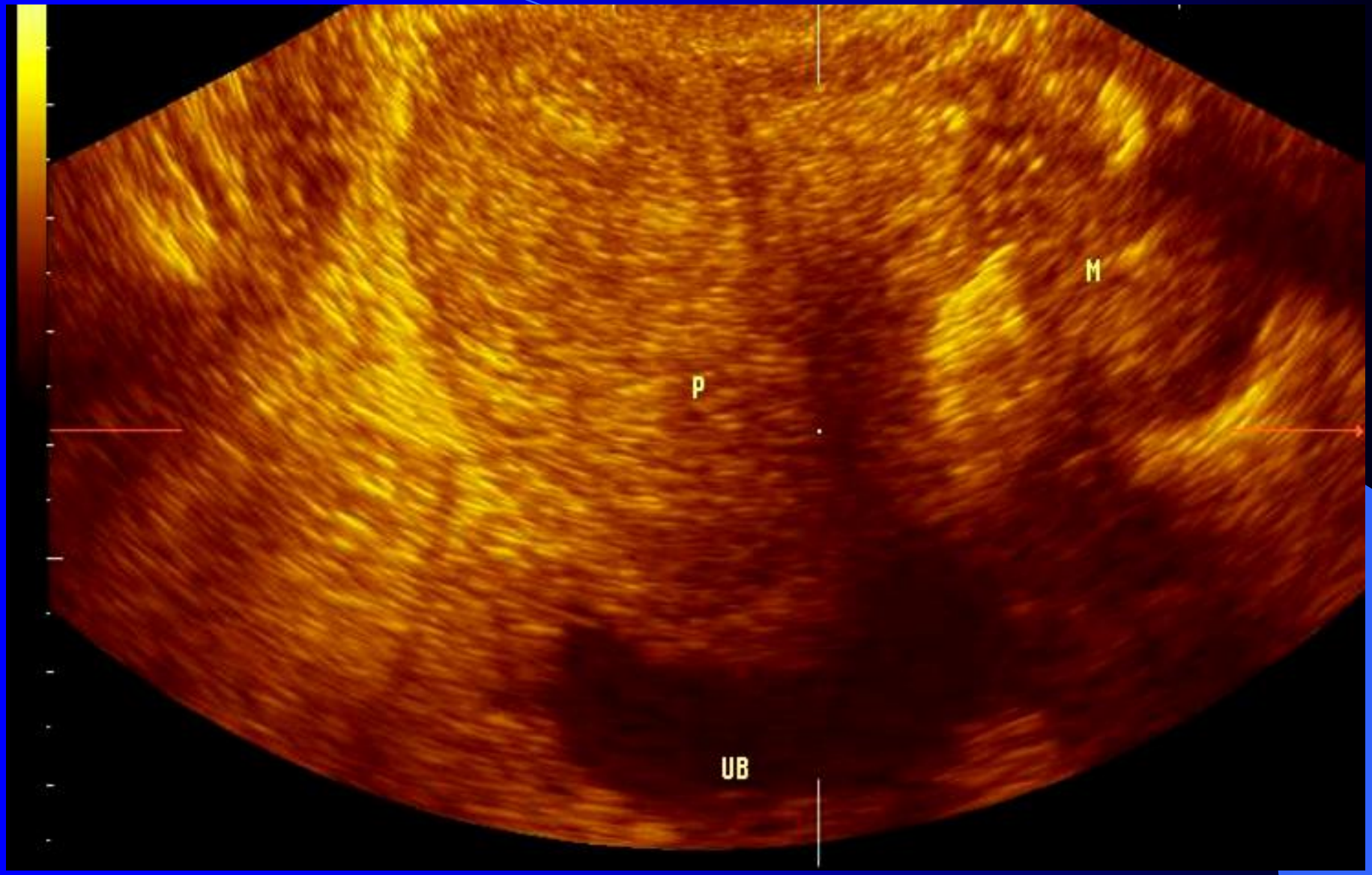

Periprostatic fat planes infiltration

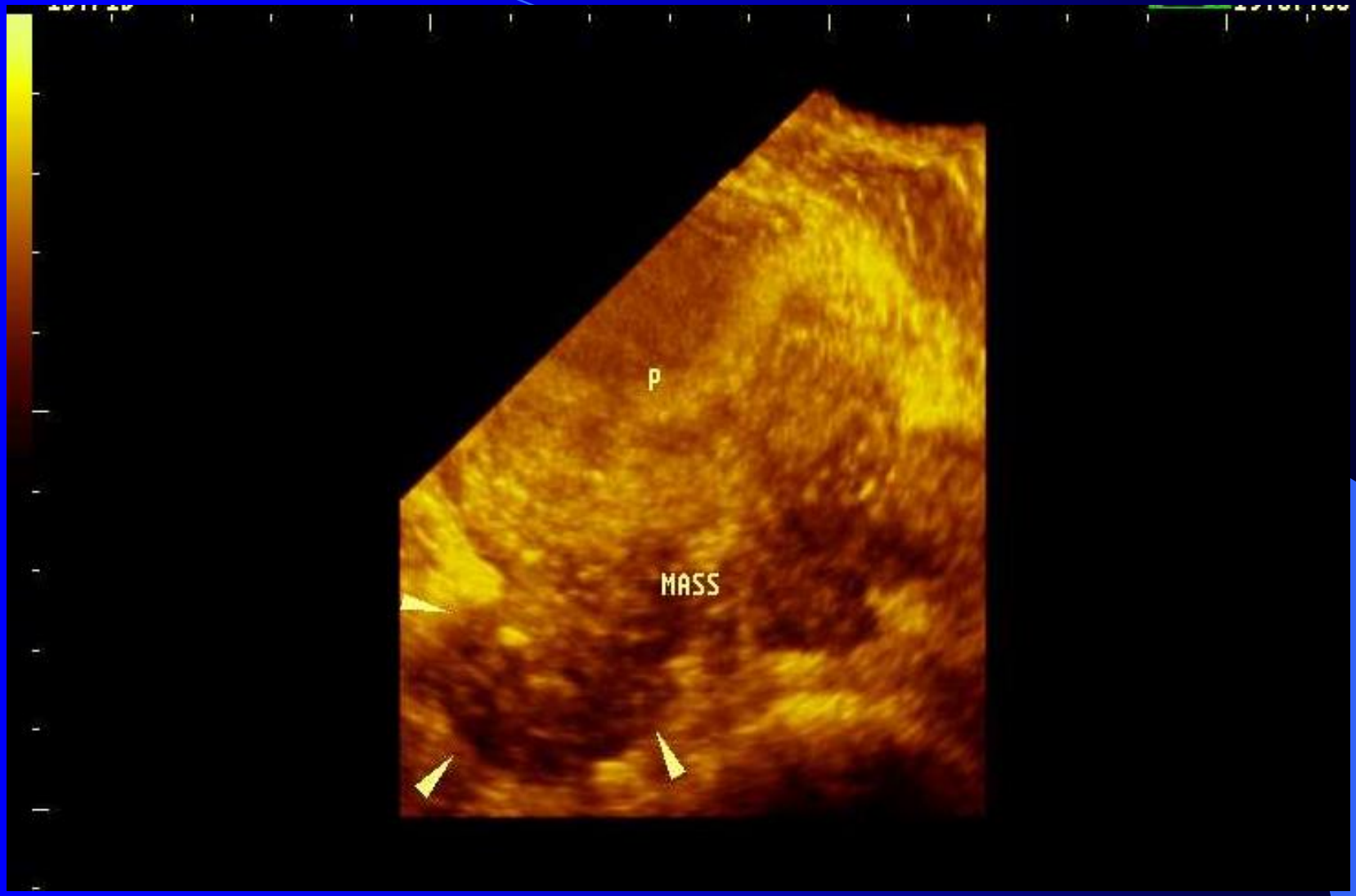

BPH with associated extra capsular extension of PC

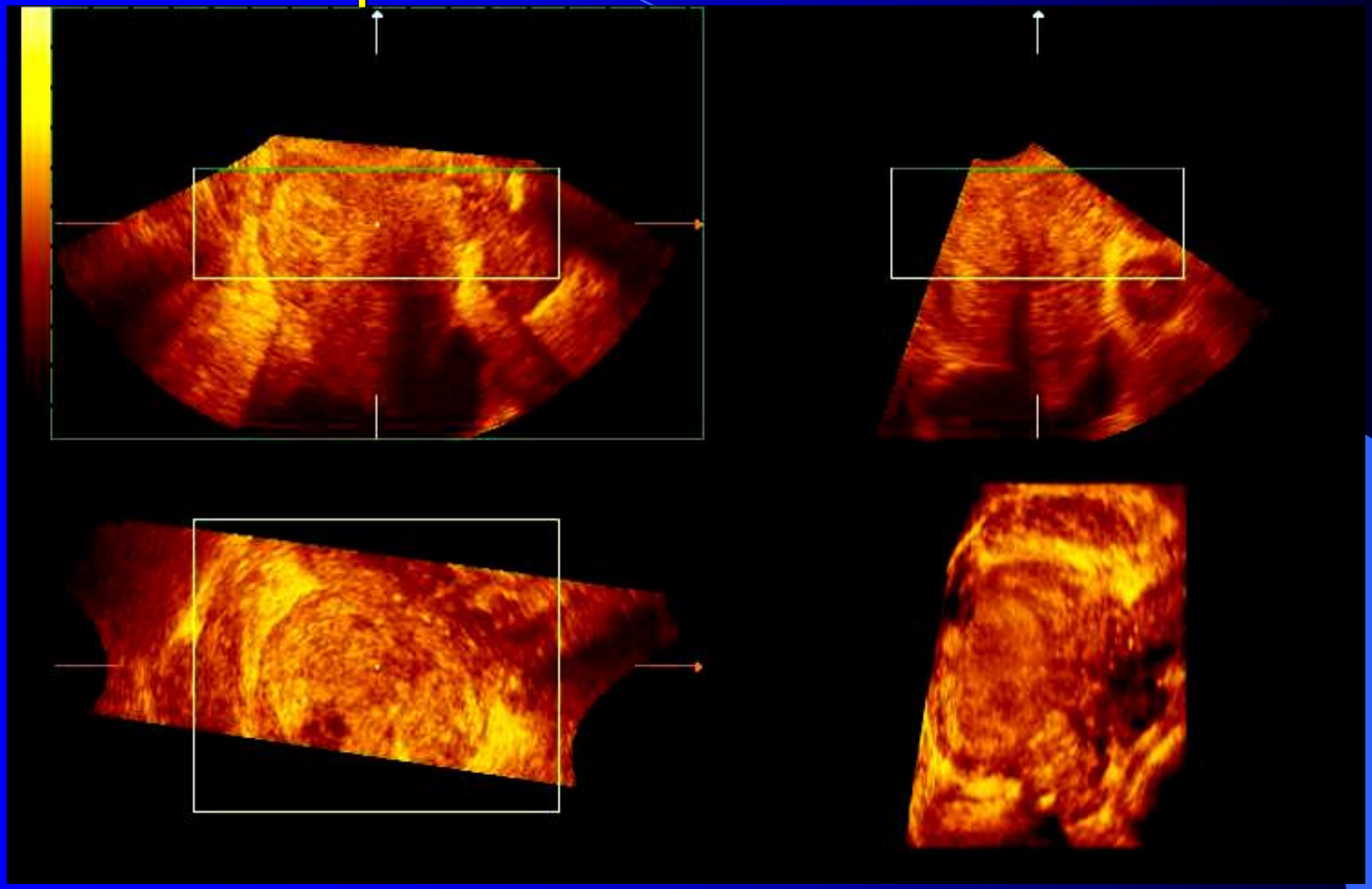

Prostate cancer infiltrating the urinary bladder

C.B

BPH

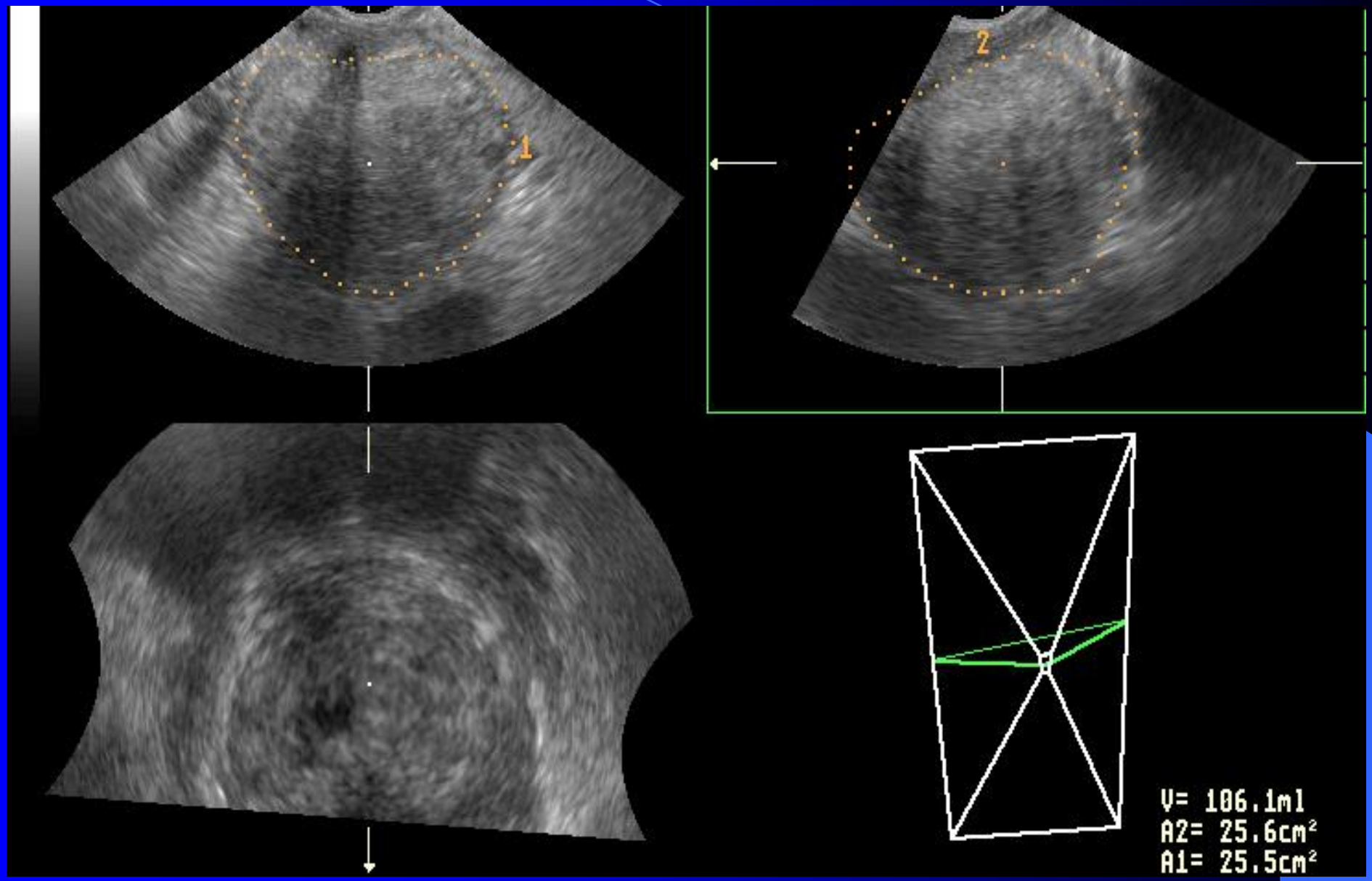

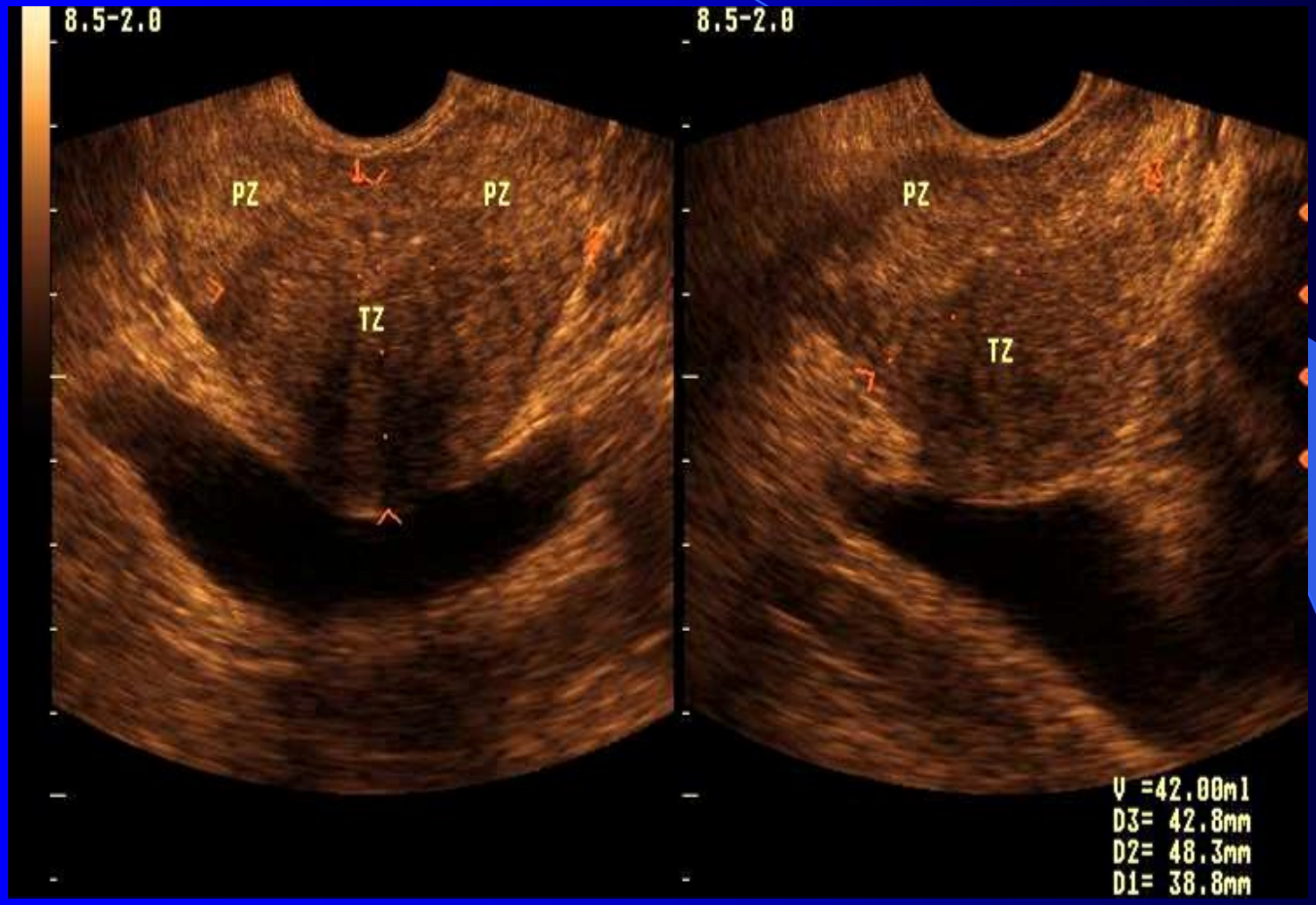
8.5-2.0
PZ
PZ
TZ
8.5-2.0
PZ
TZ
V =42.00ml
D3= 42.8mm
D2= 48.3mm
D1= 38.8mm

PROSTATIS

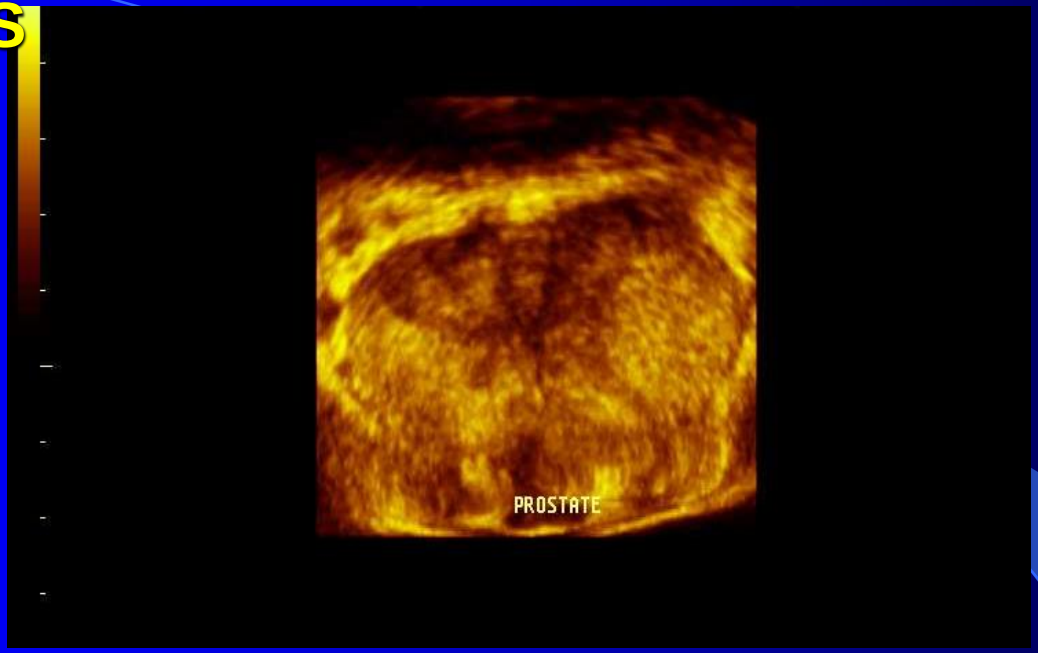
PROSTATE

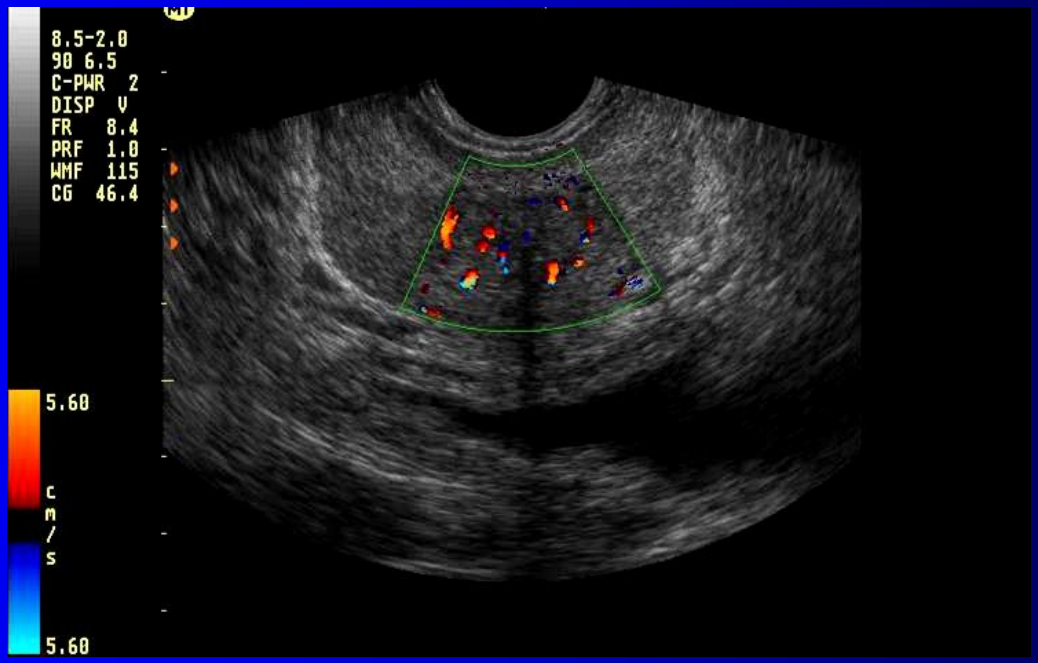
8.5-2.0
90 6.5
C-PWR 2
DISP V
FR 8.4
PRF 1.0
WMF 115
CG 46.4
5.60
cm/s
5.60

Prostatitis

Conclusion

3D TRUS and power Doppler sonography had increased the sensitivity, specificity and total accuracy of ultrasound In localizing the prostate cancer and in evaluating the capsular penetration and extracapsular spread of prostatic carcinomas.

- 3D TRUS offers more accurate volume estimation of prostatic adenomas and post-micturation residual urine.

Thank you