A Case of Large Liver Focal Nodular Hyplerplasia in children : Imaging Characterization

Sahat Matondang MD
Abdominal Imaging and Interventional Division
Cipto Mangunkusumo Hospital, Faculty of Medicine University of Indonesia

Introduction

Focal nodular hyperplasia is a rare tumorlike condition predominantly found in women during the third to fifth decade of life, although it may occur in both sexes and all age groups .FNH is rare in children, and comprises only 2% of all pediatric liver tumors.
The majority of FNH lesions are asymptomatic Symptoms in children related to size of FNH include abdominal mass, hepatomegaly, and liver function test abnormalities. It is essential to differentiate FNH from liver adenoma because the latter has a different natural evolution; namely, an increased risk of hemorrhage and rupture, and a well-documented malignant potential
Herein, we report the case of a 9 year-old child (female) with a huge FNH which size is more than 10 cm.

Case Presentation

CASE PRESENTATION: A 9-year-old female was found a hepatic space-occupying lesion.
The CT examination showed the size of the tumor to be 12.5 × 9.9 cm in the left hepatic lobe. The characteristic enhancement is diffuse homogenous arterial enhancement with isointensity in delayed scan
The MRI examination with gadoxetic acid show hepatobiliary uptake with central scar
This child underwent surgical resection of the tumor which was confirmed as FNH by pathology.



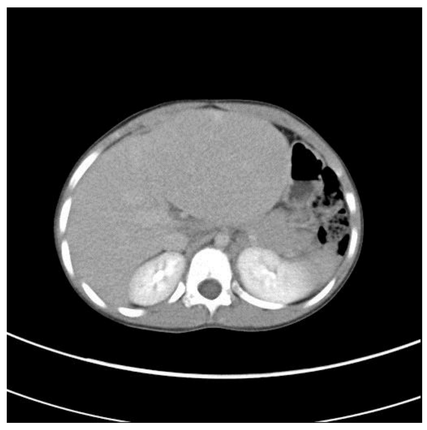
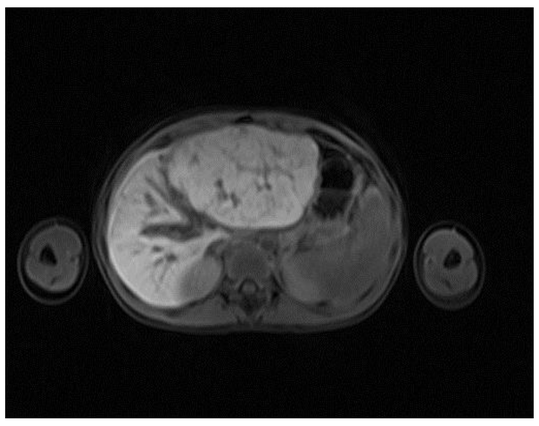

Discusion

Second most common benign hepatic tumor after hemangioma. Focal nodular hyperplasia (FNH) as a result of a hyperplastic response of the hepatocytes to the presence of pre-existing vascular malformation.
Related to the hypervascularity of the tumor, during the arterial phase of hepatic enhancement, focal nodular hyperplasia shows an immediate and intense enhancement with the exception of the central scar, which has delayed enhancement caused by the presence of abundant myxomatous stroma. Central scar is pathognomonic but may be find especialy in big FNH > 3cm . MRI can detect the central scar of FNH with 78% better sensitivity than CT
On delayed phase shows decreased enhancement of the lesion relative to the normal enhancing hepatic parenchyma, resulting in the lesion being isoattenuating to the liver.
The appearance of HA, however, can be highly variable and unfortunately, in many situations, HA and FNH have similar imaging appearances. Gadoxetic acid on delayed hepatobiliary phase images appear to improve the specificity for characterization and differentiation of these two lesions which is FNHs are usually iso- or hyperintense relative to the liver parenchyma but rarely hypointense, (like hepatic adenoma). This is presumably because of the presence of functioning hepatocytes and focal abnormal biliary excretion

Conclusions

FNH is rare in children, and comprises only 2% of all pediatric liver tumors. The majority of FNH lesions are asymptomatic Symptoms in children related to size of FNH
Enhancement pattern of FNH is hypervascular enhancement in arterial phase and decreased enhancement of the lesion relative to the normal enhancing hepatic parenchyma, resulting in the lesion being isoattenuating to the liver on delayed phase
The appearance of HA, however, can be highly variable and unfortunately, in many situations, HA and FNH have similar imaging appearances. Gadoxetic acid on delayed hepatobiliary phase images appear to improve the specificity for characterization and differentiation of these two lesions which is FNHs are usually iso- or hyperintense relative to the liver parenchyma but rarely hypointense, (like hepatic adenoma).

References

1. Shamsi K, De Schepper A, Degryse H, Deckers F. Focal nodular hyperplasia of the liver: radiologic findings. Abdom Imaging 1993;18:32–38
2. Vilgrain V, Flejou JF, Arrive L, et al. Focal nodular hyperplasia of the liver: MR imaging and pathologic correlation in 37 patients. Radiology 1992;184:699–703
3. Reymond D, Plaschkes J, Luthy AR, Leibundgut K, Hirt A, Wagner HP. Focal nodular hyperplasia of the liver in children: review of follow-up and outcome. J Pediatr Surg 1995;30:1590–1593
4. Fowler KJ, et al: Magnetic resonance imaging of focal liver lesions: approach to imaging diagnosis. Hepatology. 2011 ;54(6):2227-37.
5. Silva AC, et al: MR imaging of hypervascular liver masses: a review of current techniques. Radiographics. 2009 ;29(2):385-402.
6. Seale et al .Hepatobiliary specific MR contrast agent . Role in imaging liver and biliary tree. RadioGraphics 2009; 29:1725–1748